

REFERENCES

1. Tarragón B, Valdenebro M, Serrano ML, Maroto A, Llópez-Carratalá MR, Ramos A, et al. Fracaso renal agudo en pacientes hospitalizados por COVID-19. *Nefrología*. [Online]. 2021;41:34–40, <http://dx.doi.org/10.1016/j.nefro.2020.08.005>.
2. Claire-Del Granado R, Casas-Aparicio G, Rosa-Diez G, Rizo-Topete L, Ponce D. Renal Replacement Therapy for Acute Kidney Injury in COVID-19 Patients in Latin America. *Kidney Blood Press Res*. [Online]. 2020;45:775–83, <http://dx.doi.org/10.1159/000511914>.
3. Menon T, Sharma R, Kataria S, Sardar S, Adhikari R, Tousif S, et al. The Association of Acute Kidney Injury With Disease Severity and Mortality in COVID-19: A Systematic Review and Meta-Analysis. *Cureus*. [Online]. 2021;13:e13894, <http://dx.doi.org/10.7759/cureus.13894>.
4. Mohamed MMB, Velez JCQ. Proteinuria in COVID-19. *Clin Kidney J*. [Online]. 2021;14 Supplement.1:i40–7, <http://dx.doi.org/10.1093/ckj/sfab036>.
5. Cheng Y, Zhang N, Luo R, Zhang M, Wang Z, Dong L, et al. Risk Factors and Outcomes of Acute Kidney Injury in Critically Ill

Patients with Coronavirus Disease 2019. *Kidney Dis*. [Online]. 2020;14 Supplement.1:1–9, <http://dx.doi.org/10.1159/000512270>.

Alfredo Rebaza-Mateo, Fernando Yarasca-Moreno, Luis Tataje-Lavanda*

Escuela Profesional de Medicina Humana, Universidad Privada San Juan Bautista Lima, Perú-Filial Ica, Ica, Peru

*Corresponding author.

E-mail address: luis.tatajel@upsjb.edu.pe (L. Tataje-Lavanda).

21 May 2021

<https://doi.org/10.1016/j.nefro.2021.06.008>

2013-2514/© 2021 Sociedad Española de Nefrología. Published by Elsevier España, S.L.U. This is an open access article under the CC BY-NC-ND license (<http://creativecommons.org/licenses/by-nc-nd/4.0/>).

A case of acute interstitial nephritis following the Pfizer–BioNTech COVID-19 vaccine

Un caso de nefritis tubulointersticial aguda después de la vacunación con Pfizer-BioNTech COVID-19



Dear Editor,

We still do not fully understand the mechanisms behind renal involvement in SARS-CoV-2 infection, whether direct injury from the virus or resulting from depletion and/or release of cytokines as a severe complication of the respiratory condition.^{1,2} After vaccination was rolled out, the world population began to see a ray of hope. However, this has been obscured by reports of adverse events creating a potential barrier to large-scale vaccination efforts. We present the case of a patient with acute tubulointerstitial nephritis (ATIN) on top of diabetic nephropathy, in which no related agent was identified, except for the Pfizer-BioNTech Comirnaty® COVID-19 mRNA vaccine (BNT162b2).

This was a 78-year-old male with hypertension, hyperuricaemia, dyslipidaemia, diabetes mellitus with good metabolic control and chronic kidney disease (CKD) stage 3a-b/A3. In November 2018, he had a serum creatinine (Cr) level of 1.7 mg/dl, estimated glomerular filtration rate by CKD-EPI of 39 ml/min/1.73 m² and albumin/creatinine ratio (ACR) of 1400 mg/g, with no repeat or subsequent nephrology follow-up. He had no history of COVID-19 infection. He was on

long-term treatment with statins, ACE inhibitors, allopurinol, vildagliptin and metformin. He went to Emergency Room after a lab tests that revealed Cr of 5.38 mg/dl, urea of 156 mg/dl, anaemia with eosinophilia, and ACR of 3397 mg/g, with no nephrotic syndrome. He had urine sediment with microhaematuria and leukocyturia without eosinophils in the urine (Table 1). The patient reported mild hypoxemia and asthenia since receiving the first dose of the COVID-19-BNT162b2 vaccine three weeks prior, but no fever or skin rash; 48 h before admission, he received the second dose of the vaccine but reported no additional symptoms. He showed mild signs of dehydration on physical examination. No abnormalities on chest X-ray and PCR for SARS-CoV-2 was negative. The ultrasound showed small kidneys (left 9.4 cm and right 10 cm) with slightly hyperechoic parenchyma; no signs of dilation of the collecting duct system. Renal biopsy (Fig. 1) showed a total of 40 glomeruli, 21 were globally sclerosed (52%), the rest presented lesions of nodular glomerulosclerosis. The interstitium showed foci of severe mononuclear inflammatory infiltrate with abundant eosinophils, with tubular damage, fibrosis and tubular atrophy. The arterioles showed no lesions and there were no immune deposits in the immunofluorescence. The findings were consistent with the pathology diagnosis of immunoallergic ATIN^{3,4} that combined with the clinical characteristics and the recent administration of the COVID-19 vaccine, led us to define this case as ATIN potentially induced by the BNT162b2 vaccine. Treatment was started with

DOI of original article:

<https://doi.org/10.1016/j.nefro.2021.05.004>,

<https://doi.org/10.1016/j.nefro.2023.01.002>.

Table 1 – Changes over time in the analytical parameters of the patient with acute tubulointerstitial nephritis.

Parameters	Baseline Nov/2018	On admission	At 2 weeks*	At 6 weeks	Normal values
Leucocytes	8.83	7.05	11.39	7.76	4–10 × 10 ³ /μl
Haemoglobin	15.3	11.2	11.1	10.8	12–16 g/dl
Platelets	256	254	165	140	130–450 × 10 ³ /μl
Neutrophils	5.67 (64)	4.98 (70)	9.9 (87)	6.2 (80)	2–7 × 10 ³ /μl (40%–80%)
Lymphocytes	2.16 (24)	0.94 (13.3)	0.64 (5.6)	0.74 (9.5)	0.6–3.4 × 10 ³ /μl (14%–48%)
Eosinophils	0.44 (5)	0.72 (8.9)	0.13 (1.1)	0.21 (2.7)	0–0.6 × 10 ³ /μl (0%–7%)
LDH	215	318	289	242	135–214 IU/l
Total bilirubin	0.5	0.3	0.5	0.3	0.1–1 mg/dl
Total proteins	5.4	6.4	6.5	5.6	6.4–8.7 g/dl
Serum albumin	3.9	4.2	4	3.39	3–5.5 g/dl
GOT	22	25	27	9	5–32 IU/l
GPT	23	23	22	17	5–33 IU/l
Total cholesterol	146	119	120	128	mg/dl
LDL cholesterol	98	55	–	49	mg/dl
Triglycerides	279	178	128	130	mg/dl
Urea	65	156	179	205	17–60 mg/dl
Creatinine	1.7	5.38	5	4.9	0.6–1.2 mg/dl
Uric acid	6.2	4.5	7	7.6	3.4–7 mg/dl
Na ⁺	143	145	140	137	135–145 mmol/l
K ⁺	4.7	5.6	3.6	3.6	3.5–5.5 mmol/l
Cl ⁻	105	117	101	95	95–110 mmol/l
Ca ⁺²	9.6	9.4	8.5	8.2	8.5–10.5 mg/dl
p ⁺²	–	4.7	4.2	4.4	3.5–5.5 mg/dl
Magnesium ⁺²	2.3	1.69	1.9	2	1.7–2.2 mg/dl
Bicarbonate	23	19.9	27	26	22–28 mEq/l
CRP	0.5	0.23	1.52	1.72	0.1–0.5 mg/dl
Ferritin	–	139	150	196	–
Procalcitonin	–	0.19	0.2	0.21	<0.5 ng/mL
Hepatitis B, C and HIV	–	Negative	–	–	N/A
ANA, Anti-GBM, Anti-dsDNA, ANCA, RF and cryoglobulins	–	Negative	–	–	N/A
C3	–	123	–	–	–
C4	–	25.5	–	–	–
Anti-PLA2R Ab (ELISA)	–	Negative	–	–	N/A
IgG	–	1,070	–	–	800–1600 mg/dl
IgA	–	179	–	–	70–400 mg/dl
IgM	–	107	–	–	90–180 mg/dl
Serum electrophoresis	–	Polyclonal Ig distribution	–	–	Negative g/l
Serum/urine immunofixation	–	Negative	–	–	N/A
Diuresis	1.9	1.2	0.4	0.35	l/24 h
Albumin/creatinine ratio (ACR)	1.4	3.3	2.8	–	<0.03 g/g Cr
Microhaematuria	1–5	35–50	20–25	–	/HPF
Proteinuria	1.2	3.1	–	–	g/24 h
Urinary Na	–	82	–	–	20–200 mEq/l
Urinary Cl	–	78	–	–	N/A
Urinary K	–	34.9	–	–	25–125 mEq/l

* : check-up after initiation of acute haemodialysis; N/A: not applicable; Na⁺: sodium; Cl⁻: chloride; K⁺: potassium; Mg⁺²: magnesium; Ca⁺²: calcium; CRP: C-reactive protein; Ab: antibodies; HIV: human immunodeficiency virus; HBV: hepatitis B virus; HCV: hepatitis C virus; ANA: antinuclear antibodies; anti-dsDNA: anti-double-stranded DNA antibody; ANCA: antineutrophil cytoplasmic autoantibody; anti-GBM: anti-glomerular basement membrane; RF: rheumatoid factor; anti-PLA2R-Ab: anti-phospholipase A2 receptor antibody; Ig: immunoglobulins; ELISA: enzyme-linked immunosorbent assay; C3: complement component C3; C4: complement component C4; HPF: high-power field.

three boluses of methylprednisolone 125 mg/day followed by prednisone 0.8 mg/kg/day, which was gradually reduced and discontinued after six weeks.⁵ As there was no recovery of renal function or oliguria, he was started on haemodialysis without changes so far.

The BNT162b2 vaccine, based on particles of nucleoside-modified RNA in lipid nanoparticles, enters the host cells, producing the SARS-CoV-2 S protein and stimulating the immune system to produce antibodies against it.⁶ Polack et al.⁷ studied the safety and efficacy of this vaccine in

43,548 participants, concluding that a two-dose regimen conferred 95% protection, for a median of two months. However, only 0.7% (n = 256) had CKD, thereby perpetuating the lack of data on immunogenicity, efficacy, safety and possible immunoallergic reactions in patients with kidney disease.⁸ In a prospective observational study, Menni et al.⁹ assessed the proportion and likelihood of self-reported systemic and local side effects and allergic reactions within eight days after vaccination among individuals who received one or two doses of the BNT162b2 vaccine and one dose of the ChAdOx1-nCoV-

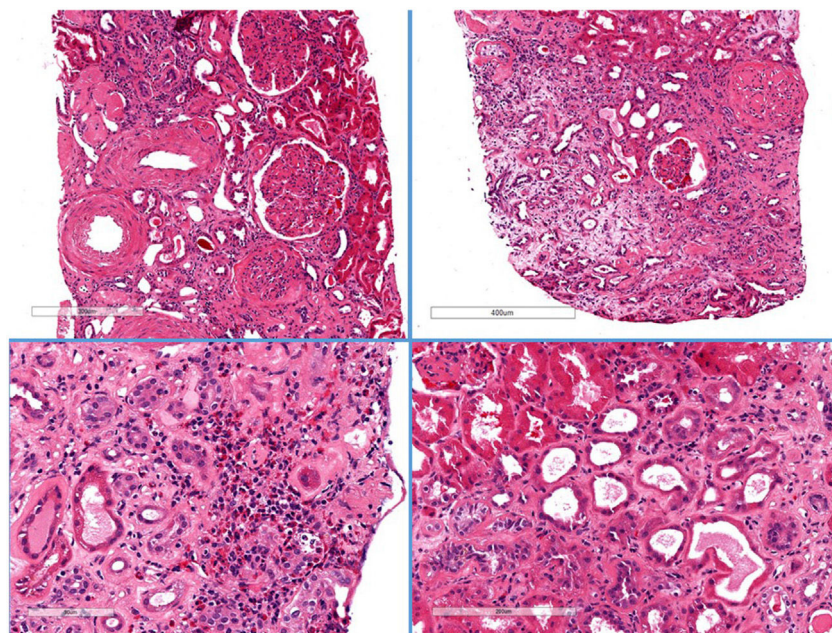


Fig. 1 – Renal biopsy histology.

Haematoxylin-eosin. Global sclerosis is evident in 21/40 glomeruli. Diffuse mesangial enlargement with images of nodular transformation. Severe foci of patchy oedema with mononuclear inflammatory infiltrate with abundant eosinophils. Fibrosis and moderate tubular atrophy with flattening of the epithelium, without tubulitis. The arteries show moderate-to-intense arteriosclerosis, and the arterioles show intense hyaline lesions.

19 vaccine; 282,103 received one dose of BNT162b2, of whom 28,207 received a second dose; 71.9% and 68.5%, respectively, reported local side effects, while systemic side effects were only reported by 13.5% after the first dose and 22% after the second. As compared with those who had no known prior infection, the individuals with prior COVID-19 infection presented systemic side effects that were 1.6 times more common after the first doses in.

Despite the undeniable success of vaccination, pharmacovigilance is a matter of public interest which is becoming increasingly important. This makes the pathology findings of our case particularly relevant, although it is always difficult to make assumptions about causality in cases of drug-induced ATIN. There have been reports of different glomerular diseases associated with COVID-19.¹⁰⁻¹² Several cases were recently reported involving a possible association between COVID-19 vaccines and glomerular disorders: five cases of macroscopic post-vaccination haematuria, three with known IgA nephropathy (IgAN)^{13,14} and the other two healthy individuals being diagnosed respectively with IgAN and extracapillary proliferative glomerulonephritis with crescents¹⁵; and lastly, two cases associated with minimal change disease.^{16,17} Meanwhile, only one case of ATIN has been reported coinciding with BNT162b2 vaccination.¹⁸

Consequently, the surveillance and identification of adverse effects presumed to be attributable to vaccination should be one of the priorities in public health in all countries.

Funding

No funding was received for this study.

Conflicts of interest

The author has no conflicts of interest to declare.

REFERENCES

1. Khouchlaa A, Bouyahya A. Covid-19 nephropathy; probable mechanisms of kidney failure. *J Nephropathol.* 2020;9:35.
2. Su H, Yang M, Wan C, Yi LX, Tang F, Zhu HY, et al. Renal histopathological analysis of 26 postmortem findings of patients with COVID-19 in China. *Kidney Int.* 2020;98:219-27.
3. Praga M, González E. Acute interstitial nephritis. *Kidney Int.* 2012;77:956-61.
4. Caravaca-Fontán F, González E, Fernández-Juárez G. Nefropatías Intersticiales. En: Lorenzo V, López Gómez JM (Eds). *Nefrología al día.* Available from: <https://www.nefrologiaaldia.org/252>.
5. Schurder J, Buob D, Perrin P, Thervet E, Karras A, Hertig A. Acute interstitial nephritis: aetiology and management. *Nephrol Dial Transplant.* 2020:1-4.
6. Sahin U, Muik A, Vogler I, Derhovanessian E, Kranz LM, Vormehr M, et al. BNT162b2 induces SARS-CoV-2-neutralising antibodies and T cells in humans. *medRxiv.* 2020, <http://dx.doi.org/10.1101/2020.12.09.20245175>.
7. Polack FP, Thomas SJ, Kitchin N, Absalon J, Gurtman A, Lockhart S, et al. Safety and Efficacy of the BNT162b2 mRNA Covid-19 Vaccine. *N Engl J Med.* 2020;383:2603-15.
8. Glenn DA, Hegde A, Kotzen E, Walter EB, Kshirsagar AV, Falk R, et al. Systematic review of safety and efficacy of COVID-19 vaccines in patients with kidney disease. *Kidney Int Rep.* 2021;6:1407-10.

9. Menni C, Klaser K, May A, Polidori L, Capdevila J, Louca P, et al. Vaccine side-effects and SARS-CoV-2 infection after vaccination in users of the COVID Symptom Study app in the UK: a prospective observational study. *Lancet Infect Dis.* 2021;3099:1-11.
 10. León Román J, Vergara A, Agraz I, García-Carro C, Bermejo S, Gabaldón A, et al. Focal and segmental glomerulosclerosis associated with COVID-19 infection. *Nefrologia (Engl Ed).* 2021, <http://dx.doi.org/10.1016/j.nefro.2021.03.002>. S0211-6995(21)00058-8.
 11. Sharma P, Uppal NN, Wanchoo R, Shah HH, Yang Y, Parikh R, et al. COVID-19-associated kidney injury: a case series of kidney biopsy findings. *J Am Soc Nephrol.* 2020;31: 1948-58.
 12. Nasr SH, Kopp JB. COVID-19-associated collapsing glomerulopathy: an emerging entity. *Kidney Int Rep.* 2020;5:759-61.
 13. Rahim SEG, Lin JT, Wang JC. A case of gross hematuria and IgA nephropathy flare-up following SARS-CoV-2 vaccination. *Kidney Int.* 2021;100:238, <http://dx.doi.org/10.1016/j.kint.2021.04.024>.
 14. Negrea L, Rovin BH. Gross hematuria following vaccination for severe acute respiratory syndrome coronavirus 2 in 2 patients with IgA nephropathy. *Kidney Int.* 2021;99: 1487.
 15. Tan HZ, Tan RY, Jun Choo JC, Lim CC, Tan CS, Liang Loh AH, et al. Is COVID-19 vaccination unmasking glomerulonephritis? *Kidney Int.* 2021, <http://dx.doi.org/10.1016/j.kint.2021.05.009>.
 16. Lebedev L, Sapojnikov M, Wechsler A, Varadi-Levi R, Zamir D, Tobar A, et al. Minimal change disease following the Pfizer-BioNTech COVID-19 vaccine. *Am J Kidney Dis.* 2021;XX:1-4.
 17. Maas RJ, Gianotten S, van der Meijden WAG. An additional case of minimal change disease following the Pfizer-BioNTech COVID-19 vaccine. *Am J Kidney Dis.* 2021;(May), <http://dx.doi.org/10.1053/j.ajkd.2021.05.003>.
 18. Case Series Drug Analysis Print Name: COVID-19 mRNA Pfizer-BioNTech vaccine analysis print. Report Run Date: 16-Mar-2021. Data Lock Date: 07-Mar-2021 19:00:03.
- José Carlos de la Flor Merino^{a,*}, Tania Linares Gravalos^a, Marina Alonso-Riaño^b, Pilar Segura Cebollada^c, Cristina Albarracín Serra^a, Elisa Ruiz Cicero^a, Gioconda Gallegos Bayas^a, Miguel Rodeles del Pozoa^a
- ^a Servicio de Nefrología, Hospital Central de la Defensa Gómez Ulla, Madrid, Spain
^b Servicio de Anatomía Patológica, Hospital 12 de octubre, Madrid, Spain
^c Servicio de Medicina Preventiva, Hospital Central de la Defensa Gómez Ulla, Madrid, Spain
- * Corresponding author.
E-mail address: jflomer@mde.es (J.C. de la Flor Merino).
<https://doi.org/10.1016/j.nefro.2021.05.007>
- 2013-2514/© 2021 Sociedad Española de Nefrología. Published by Elsevier España, S.L.U. This is an open access article under the CC BY-NC-ND license (<http://creativecommons.org/licenses/by-nc-nd/4.0/>).