

Role of monoclonal antibodies in the treatment of immune-mediated glomerular diseases

Joaquín Manrique¹, Paolo Cravedi²

¹ Servicio de Nefrología. Complejo Hospital de Navarra. Pamplona (Spain)

² Icahn School of Medicine at Mount Sinai. New York (USA)

Nefrología 2014;34(3):388-97

doi:10.3265/Nefrologia.pre2014.Feb.12506

ABSTRACT

Non-specific immunosuppressants have represented for decades the only therapies for patients with immune-mediated glomerular diseases. These treatments, however, are associated with high rates of no-response and are burdened by toxicities that frequently offset the benefits of proteinuria reduction. Monoclonal antibodies targeting selective cell populations or mediators implicated in the pathophysiology of glomerular diseases have recently become available. Rituximab, a chimeric monoclonal antibody against the CD20 antigen on B cells safely reduced proteinuria in patients with nephrotic syndrome secondary to membranous nephropathy, minimal change disease, or focal segmental glomerulosclerosis. Its ability to reduce auto-antibody formation has been instrumental to treat also ANCA-associated vasculitis, lupus nephritis, and mixed cryoglobulinemia. Many reports have also documented the efficacy of the anti-C5 humanized monoclonal antibody Eculizumab to treat atypical hemolytic uremic syndrome, C3 nephropathy, and membranoproliferative glomerulonephritis. Thanks to these encouraging findings, monoclonals are becoming very helpful tools to treat patients with glomerular diseases. Moreover, thanks to their specific mechanism of action, these and other monoclonal antibodies are important in improving our understanding of the pathophysiology of glomerular diseases. Their still high costs, however, might represent a major hurdle for their widespread implementation for all patients in need.

Keywords: Abatacept. Adalimumab. Belimumab. Eculizumab. Fresolimumab. Glomerular disease. Monoclonal antibody. Rituximab.

INTRODUCTION

Until the end of the Nineties, the treatment of glomerular diseases has been largely based on specific immunosuppressive agents, frequently associated with substantial toxicities. More

Correspondence: Joaquín Manrique

Servicio de Nefrología.
Complejo Hospital de Navarra. Pamplona (Spain).
jmanrique@navarra.es

Papel de los anticuerpos monoclonales en el tratamiento de las enfermedades glomerulares autoinmunes

RESUMEN

Los inmunosupresores no específicos han representado durante décadas las únicas terapias para pacientes con enfermedades glomerulares autoinmunes. Estos tratamientos, sin embargo, se asociaban con unas tasas muy elevadas de no respondedores y mucha toxicidad que contrarrestaba su efecto antiproteinúrico. Recientemente están disponibles anticuerpos monoclonales cuyo objetivo selectivo son poblaciones celulares o mediadores directamente implicados en la patofisiología de las enfermedades glomerulares. El Rituximab es un anticuerpo monoclonal quimérico dirigido contra el antígeno CD20 en la superficie de los linfocitos B que reduce de manera eficaz y segura la proteinuria en pacientes con síndrome nefrótico secundario a nefropatía membranosa, enfermedad de cambios mínimos o glomeruloesclerosis segmentaria y focal. Su capacidad para reducir la formación de anticuerpos ha sido empleada también en las vasculitis ANCA positivas, nefropatía lúpica y crioglobulinemia mixta. Diversos trabajos han documentado la eficacia del anticuerpo monoclonal anti-factor C5, eculizumab, para el tratamiento del síndrome hemolítico urémico atípico, la nefropatía C3 o la glomerulonefritis membranoproliferativa. Con base en estos prometedores resultados, los anticuerpos monoclonales se han convertido en estrategias muy útiles en el tratamiento de pacientes con enfermedades glomerulares. Incluso, basado en su mecanismo de acción, estos y otros monoclonales han contribuido a mejorar el conocimiento de la patofisiología de la enfermedad glomerular. Sin embargo, actualmente no es posible generalizar su uso en todos los pacientes que potencialmente podrían beneficiarse, por su elevado coste.

Palabras clave: Abatacept. Adalimumab. Belimumab. Eculizumab. Fresolimumab. Enfermedad glomerular. Anticuerpo monoclonal. Rituximab.

recently, the development of monoclonal antibodies, together with progresses in the knowledge of pathophysiological mechanisms of autoimmune glomerulopathies, offered the opportunity for more selective, effective, and safer treatments.

Rituximab, a chimeric antibody against the B cell-expressed CD20 antigen, was the first monoclonal employed for the treatment of a glomerular disease.¹ Introduced in 1998 with

the indication for the treatment of non-Hodgkin lymphoma and chronic lymphatic leukemia, it has been subsequently approved as a therapy for rheumatoid arthritis.² Rituximab has been initially used to treat membranous nephropathy (MN),³⁻⁶ but its use has rapidly spread to other primary⁷ and secondary⁸ glomerular diseases. Another antibody whose employment has progressively increased in the treatment of glomerulopathies is Eculizumab, a humanized monoclonal antibody against the C5 complement component.⁹

These encouraging results and the growing availability of novel monoclonal antibodies selectively targeting cytokines, inflammatory mediators and different lymphocyte populations are expected to generate a major paradigm shift in the treatment of immune-mediated glomerular diseases.

RITUXIMAB

Membranous nephropathy

Membranous nephropathy, the leading cause of nephrotic syndrome in Caucasian adults, is characterized by the deposition of immune complexes in the subepithelial space of the glomeruli, leading to a thickening of the glomerular basement membrane.¹⁰ If untreated, about 30-40% of affected patients reach end-stage kidney disease (ESRD) in over 5-10 years after diagnosis.¹¹

Since B cells play a crucial role in MN pathogenesis through autoantibody production and antigen presentation, Rituximab was hypothesized to represent an ideal treatment to selectively treat the disease. Consistent with this hypothesis, in early small cohort studies Rituximab-induced B-cell depletion was associated with proteinuria reduction and regression or amelioration of immunopathologic changes of active glomerular disease.¹²⁻¹⁴

Recently, Ruggenti et al. reported the outcomes of 100 patients with MN and nephrotic syndrome treated with Rituximab.⁶ B-cell depletion was associated with remission of the nephrotic syndrome in 65 out of 100 consecutive patients with MN. Twenty-seven of these patients achieved complete remission with reduction of urinary protein excretion to normal range, and 20 of the 35 who failed to achieve remission had their proteinuria reduced to less than 50% of baseline values. Treatment effect was time-dependent and all patients with at least four years of follow-up achieved complete or partial remission (Figure 1). Rituximab was effective also when previous treatments with steroids and other immunosuppressive drugs, including cyclophosphamide and chlorambucil, had failed or a second course of Rituximab was needed to treat disease recurrence after initial remission.

In summary, Rituximab treatment is able to achieve disease remission and to stabilize or even improve renal function

in MN patients at high risk of poor outcome because of persistent nephrotic syndrome. In consideration of its excellent safety profile, Rituximab should be considered to replace more toxic regimens as first line treatment of MN, at least for those patients with nephrotic syndrome unresponsive to conservative therapy.

Minimal change disease and focal segmental glomerulosclerosis

Idiopathic Nephrotic Syndrome (NS) in children and young adults is secondary to minimal change disease (MCD) in 90 percent of cases and focal segmental glomerulosclerosis (FSGS) is present in most of the remaining ones. Except for a minority of cases associated with molecular defects of podocyte genes,¹⁵ the disease appears to be immune mediated.¹⁶ This represents the rationale why until recently treatment of the disease largely relied on steroids, that achieve remission within four weeks in approximately 90% of children with MCD and 20 to 60% of those with FSGS.¹⁷ Sixty to 70% of patients, however, relapse after steroid tapering or withdrawal and most require repeat courses of prednisone to achieve remission of recurrent episodes and/or the addition of other immunosuppressive medications such as calcineurin inhibitors, mycophenolate mofetil (MMF) or alkylating agents to reduce the number of relapses and prevent major side effects of steroid treatment.¹⁸ These patients are affected by the serious adverse effects of immunosuppression and by the serious complications associated with relapsing episodes of heavy proteinuria such as accelerated cardiovascular disease, thromboembolic events and progressive renal function loss.

The possibility of a specific and safer approach to patients with steroid-dependent or frequently relapsing NS emerged in 2004, when the B-cell depleting monoclonal antibody Rituximab was reported to induce remission of proteinuria in a child with frequently relapsing NS secondary to MCD who had received this medication to cure a supervened idiopathic thrombocytopenic purpura.^{19,20} Subsequent sparse uncontrolled observations reported the efficacy of Rituximab in patients with steroid-dependent or frequently relapsing MCD,²¹ suggesting that B-cell immunity could play a key role in the pathophysiology of the disease. A prospective cohort study tested the efficacy of multiple Rituximab infusions (1 to 5) in 46 consecutive children with idiopathic nephrotic syndrome lasting for at least 1 year and maintained in remission with oral prednisone and calcineurin inhibitors. Oral agents were tapered after each infusion, and completely withdrawn within 45 days. One- and 2-year-remission probabilities were, respectively, 20 and 10%, with Median time intervals between complete oral-agent withdrawal and relapse were 5.6 and 8.5 months, respectively, following the first and subsequent courses.²²

Until recently, less attention was given to adults and patients with FSGS given difficulties in designing adequately powered

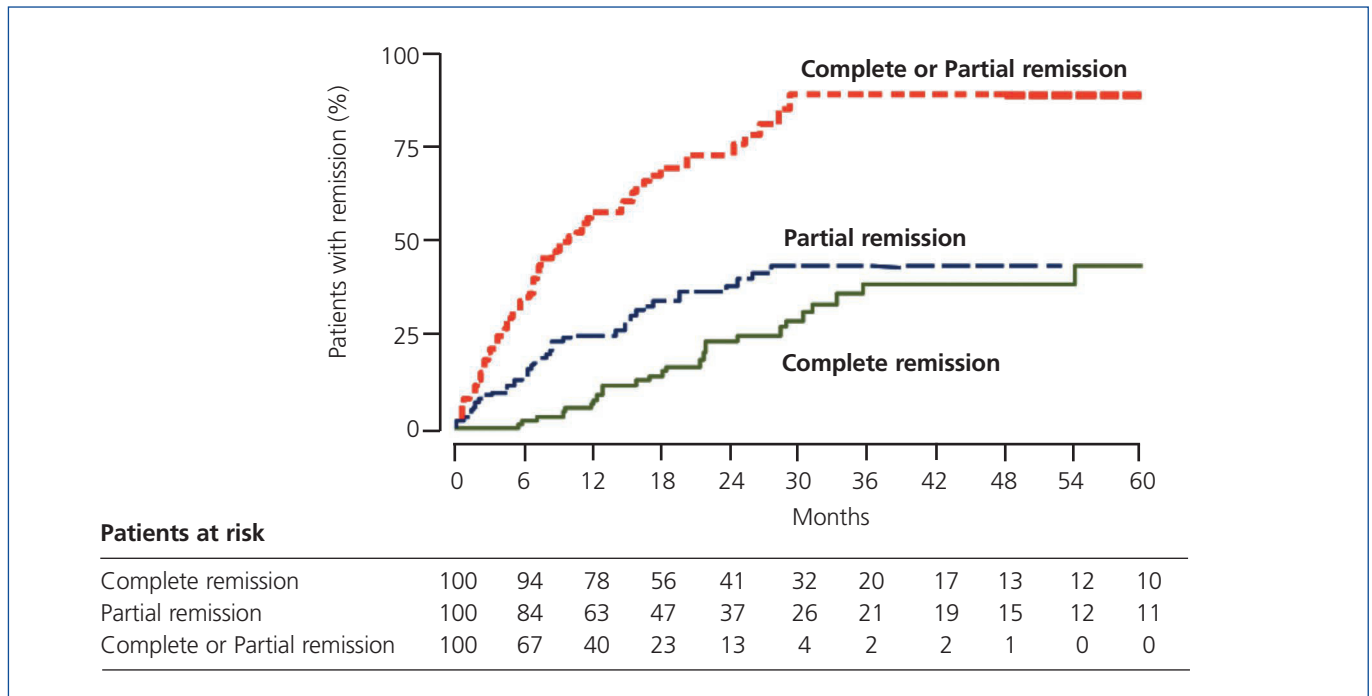


Figure 1. Kaplan-Meier curves of the percentages of 100 patients with nephrotic syndrome due to membranous nephropathy achieving complete or partial remission after Rituximab therapy⁶.

trials. In 2013, a multicenter, off-on trial evaluated the effects of Rituximab therapy followed by immunosuppression withdrawal on disease recurrence in 10 children and 20 adults with MCD or FSGS who had suffered at least two recurrences over the previous year and were in steroid-induced remission for at least one month. At 1 year after Rituximab infusion, all patients were in remission: 18 were treatment-free and 15 never relapsed. Compared with the year before Rituximab treatment, the per-patient median number of relapses decreased from 2.5 to 0.5 ($P < 0.001$) during the one year of follow-up.²³ Still unclear is the efficacy of Rituximab in steroid-resistant INS. A retrospective study showed that Rituximab induced complete remission in 7 out of 10 patients with steroid-resistant INS on steroids, calcineurin inhibitors with or without antiproliferative agents.²⁴ On the other hand, a randomized trial found that add-on therapy with Rituximab on top of calcineurin inhibitors (CNI) and prednisone did not reduce proteinuria at 3 months in 31 children with steroid-resistant INS.²⁵ Further studies are needed to establish whether B-cell depletion can be effective also in these patients.

Lupus nephritis, ANCA-associated vasculitis, and cryoglobulinemic nephropathy

The crucial pathogenic role of immune complexes in lupus nephritis (LN) made this disease an obvious target for Rituximab therapy, with the rationale that B cell depletion will extinguish the reservoir of autoreactive plasma cells.

In numerous small studies, Rituximab monotherapy proved effective in promoting complete remission of LN. In a series of 18 patients with NL class III/IV/V,⁴ induction therapy with Rituximab associated with MMF maintenance immunosuppression induced complete or partial remission in 78% of the cases, which persisted up to one year in 67% of them. This combined treatment seems effective also as a rescue therapy in refractory or relapsing LN forms. In an open-label, multicenter study including 15 patients with active or resistant LN, combined Rituximab-MMF therapy promoted partial or complete remission in 9 cases.^{26,27}

The results from initial uncontrolled studies were challenged by the Lupus Nephritis Assessment with Rituximab (LUNAR) trial, a randomized, double blind, phase III study testing the efficacy and safety of Rituximab versus placebo in patients with active proliferative LN receiving MMF and steroids. The rates of complete or partial remission at 1 year (primary end point) in the Rituximab and placebo groups were 57% and 46%, respectively, which did not reach statistical significance. Nevertheless, Rituximab was associated with a significant improvement in C3, C4 and anti-dsDNA levels.^{28,29} The Exploratory Phase II/III SLE Evaluation of Rituximab trial also failed to demonstrate benefits on nonrenal lupus.²⁹ However, uncontrolled studies on refractory LN still document 75% responder rates and many specialists continue using Rituximab successfully for these patients.³⁰ Further studies are needed to identify predictors of response to Rituximab in LN patients.

Table 1. Main studies on monoclonal antibodies in glomerular diseases

Reference	Ethiology	N	F/U (mo)	Study design	Dose	CR	Comments
Rituximab							
Ruggenti P, et al., 2012 ⁶	MN	100	29	Prospective cohort	375mg/m ² ; 1-4 doses	27%	PR: 38%; recurrences: 28%
Fervenza F, et al., 2010 ³⁸	MN	18	12	Prospective cohort	375mg/m ² ; 4 or 8 doses	22%	Out of the 18 patients who completed 24-month follow-up, 4 were in complete remission, 12 was in partial remission, 1 had a limited response, and 1 patient relapsed. CR+PR=88%
Kamei K, et al., 2009 ²⁰	Steroid-dependent INS	12	12	Prospective cohort	375mg/m ² ; 1 dose	25%	The study included only children. After steroid withdrawal, 9 patients relapsed, but 3 remained in remission without steroids for >1yr
Kemper MJ, et al., 2011 ²¹	Steroid-dependent INS	29	12	Retrospective	375mg/m ² ; 1-4 doses	70.3%	The study included only children. Steroids were withdrawn after Rituximab infusion. Out of the 29 patients with >2yrs follow-up, 12 (41%) remained in remission, 7 (24.1%) of them without further maintenance immunosuppression
Ravani P, et al., 2013 ²²	Multirelapsing INS	46	6	Off-on trial	375mg/m ² ; 1-5 doses	48%	The study included only children ^a
Ruggenti P, et al., 2014 ²³	Multirelapsing INS	30	12	Off-on trial	375mg/m ² ; 1-2 doses	100%	The study included adults (n=20) and children (n=10) ^a At one year, 18 patients were treatment-free and 15 never relapsed
Kamei K, et al., 2014 ²⁴	Steroid-resistant INS	10	21	Retrospective	375mg/m ² ; 1-4 doses	70%	Rituximab was administered on top of steroids, calcineurin inhibitors ± antiproliferative agents. In 1 patient achieved PR and in 2 no response
Magnasco A, et al., 2012 ²⁵	Steroid-resistant INS	31	3	RCT	375mg/m ² ; 2 doses	Ns	The study included only children. In the treatment arm, Rituximab was administered on top of previous immunosuppression and did not reduce proteinuria at 3 months
Pepper R, et al., 2009 ⁴	LN III/IV/V	18	12	Prospective cohort	1g; 2 doses	78%	All patients were already on steroids and received Rituximab induction and MMF maintenance therapy
Rovin BH, et al., 2012 ²⁸	LN III/IV	144	12	RCT	1g; 4 doses	26%	Rituximab or placebo were administered together with MMF and steroids. No significant difference in Rituximab vs. placebo in overall (complete and partial) response rate 57% vs. 46%
Merrill JT, et al., 2010 ²⁹	LN II/III	257	12	RCT	1g; 4 doses	12%	Background immunosuppression was continued. No significant difference in Rituximab vs. placebo in overall (complete and partial) response rate 30% vs. 28%
Jones RB, et al., 2010 ³²	AAV	44	12	RCT	375mg/m ² ; 4 doses	76%	Patients were treated with steroids + Rituximab vs. intravenous cyclophosphamide. Remission rate was comparable between the two groups
Specks U, et al., 2013 ³³	AAV	197	18	RCT	375mg/m ² ; 4 doses	39%	Rituximab-induced rate of CR was not inferior to cyclophosphamide (33%)

Continues Table 1. Main studies on monoclonal antibodies in glomerular diseases

Reference	Ethiology	N	F/U (mo)	Study design	Dose	CR	Comments
Saadoun D, et al., 2010 ³⁵	HCV-MC	33	40	Prospective cohort	375mg/m ² ; 4 doses	81%	Patients and controls received also Peg-interferon- α and Ribavirin. Response rate was significantly higher than in the control group (40%)
Visentini M, et al., 2011 ³⁶	HCV-MC	27	7	Phase II clinical trial	250mg/m ² ; 2 doses	79%	Patients received also Peg-interferon- α and Ribavirin
Eculizumab							
Bomback AS, et al., 2012 ⁴⁸	DDD and C3 GN	6	12	Case series	900mg/w (w1-4), 1200 every 2w up to w53	33%	2 patients had a reduction in serum creatinine and 1 patient had proteinuria decline
Fresolimumab							
Trachtman H, et al., 2011 ⁵⁰	Steroid-resistant FSGS	16	3	Phase I clinical trial	0.3, 1, 2, or 4mg/kg; 1 dose	N/A	Fresolimumab was well tolerated
Adalimumab							
Joy MS, et al., 2010 ⁵¹	FSGS	10	4	Phase I clinical trial	24mg/m ² ; 9 doses	N/A	Adalimumab was well tolerated. Proteinuria decreased by $\geq 50\%$ in 4 of 10 treated patients
Abatacept							
Yu CC, et al., 2013 ⁵²	FSGS	5	10-48	Case series	10mg/kg; 1-3 doses	100%	
Belimumab							
Navarra SV, et al., 2011 ⁵³	SLE	867	12	RCT	1 or 10mg/kg		Significantly higher rates of reduction of SLE severity index in Belimumab treatment groups vs. placebo. LN was an exclusion criterion

^a Rituximab was added when patients were in remission with other therapies that were progressively withdrawn. The rate of remission refers to the patients with no therapy at 2 years after Rituximab.

AAV: ANCA Associated Vasculitis; CR: Complete remission; DDD: Dense Deposits Disease; FSGS: Focal Segmental Glomerulosclerosis; F/U: Follow Up; GN: Glomerulonephritis; HCV-MC: Hepatitis C Virus-associated mixed cryoglobulinemia; INS: Idiopathic Nephrotic Syndrome; LN: Lupus Nephropathy; MN: Membranous Nephropathy; PR: Partial remission; RCT: Randomized Controlled Trial; SDNS: steroid-dependent nephrotic syndrome; SLE: Systemic Lupus Erythematosus; SSNS: steroid-sensitive nephrotic syndrome.

The evidence that the percentage of circulating B cell correlates with ANCA-associated vasculitis activity³¹ formed the background for numerous uncontrolled studies where Rituximab induced disease remission in cases resistant to other treatments. In 2010, results have been published from two large randomized controlled trials, the Rituximab versus cyclophosphamide in ANCA-associated vasculitis (RITUXVAS)³² and the Rituximab in ANCA-Associated Vasculitis (RAVE)³³ including 197 and 44 patients with ANCA-associated vasculitis, respectively. In both studies, Rituximab had a safety/efficacy profile similar to cyclophosphamide over 12 months of follow-up. Results from the extension phases of these studies might have major impact on future treatment of ANCA-associated vasculitis.

Rituximab proved effective also in the treatment of mixed cryoglobulinemia. A retrospective analysis of 242 patients with hepatitis C-unrelated mixed cryoglobulinemia showed that Rituximab treatment associated with steroids was associated with a significant improvement of clinical manifestations compared to steroids alone or in association with alkylating agents.³⁴ Similar results have been reported by a prospective-cohort study comparing the outcomes of 33 patients with hepatitis C-associated mixed cryoglobulinemia who received Rituximab, Peg-interferon, and ribavirin with those of 55 patients treated with Peg-interferon, and ribavirin, but no Rituximab.³⁵ Over the 44 weeks of follow-up, 81% of patients had a complete remission, compared to 40% in the control group. Recently, another prospective-cohort study

showed that two 250mg/m² Rituximab infusions (about half of the doses normally used) induced remission in 79% of the cases of mixed cryoglobulinemia resistant to other therapies.³⁶ Reducing Rituximab doses may therefore help in improving the safety/efficacy profile of this antibody, at least in the treatment of mixed cryoglobulinemia.

Safety

Rituximab is generally well tolerated and to date no serious adverse events have been reported in patients affected by glomerular diseases treated with Rituximab monotherapy. Amongst the millions of patients treated so far, rare cases of progressive multifocal leukoencephalopathy (PML) have been described in patients affected by autoimmune diseases who received Rituximab as a component of multidrug immunosuppressive regimens.² In none of these cases, however, Rituximab has been clearly identified as responsible in promoting this infection, especially if we consider that affected patients were on active or previous treatment with other immunosuppressants. Moreover, this infection may occur also in patients with autoimmune disease treated with Rituximab-free immunosuppressive regimens. Conversely, this infection has never been reported in Rituximab-treated patients who never received other immunosuppressants.

Optimal dosing

Treatment protocols varied widely amongst different centers. Some authors used the standard regimen of four 375mg/m² weekly doses, others preferred an eight-dose “prolonged protocol” or an “extended protocol” in which the standard four weekly infusions were followed by two or three monthly infusions. Interestingly, serial measurements of circulating B-cells showed that, in patients with MN or lupus, CD20 cells were fully depleted from the circulation just after the first drug administration.^{4,37} Consistently, in a 2 years follow up study, Fervenza et al. found no difference in proteinuria reduction at 12 months in MN patients treated with two courses of four 375mg/m² Rituximab doses compared to those who received a single course or two doses of 1g.³⁸ These findings led to question whether further Rituximab doses confer additional benefit or, rather, may just increase the risk of adverse reactions or sensitization. To address this issue, a prospective, matched-cohort study compared the safety/efficacy profile of a B-cell-driven Rituximab treatment with the standard four 375mg/m² dose protocol in 36 MN patients with long-lasting nephrotic range proteinuria refractory to conventional therapy.⁵ Patients allocated to the B-cell-driven protocol received a second infusion only if they had more than five B-cells per mm³ of peripheral blood after the first Rituximab administration, which occurred in only one of the 12 patients in this group.⁵ Prompt and persistent B-cell depletion was achieved in all patients. Time-dependent changes in proteinuria and the other

components of the nephrotic syndrome were similar in the two groups. However, the B-cell-driven approach was associated with fewer adverse events and less hospitalizations, and was four-fold less expensive, allowing for more than €10,000 (approximately \$13,000) savings per patient.⁴ Thus, B-cell titrated dosing, in addition to improve the risk/benefit profile of the drug, may facilitate the access to Rituximab even in resource-limited settings.

ECULIZUMAB

Eculizumab is an inhibitor of C5 complement component, initially approved by Food and Drug Administration and European Medical Agency for the treatment of Paroxysmal Nocturnal Hemoglobinuria,³⁹ a potentially fatal disease characterized by complement-mediated hemolysis due to the absence of CD59, a C3 convertase inhibitor, on the erythrocyte membrane.

More recently, Eculizumab has been approved also for the treatment of atypical hemolytic-uremic syndrome (aHUS), a condition where abnormalities in the genes encoding for complement inhibitors may lead to uncontrolled complement activation and to the formation of microthrombi in *glomeruli*. A review of the published literature revealed five individual case reports describing the use of Eculizumab for the treatment of membranoproliferative glomerulopathy (MPGN); two patients diagnosed with MPGN Type I and three patients with MPGN Type II (DDD).⁴⁰⁻⁴³ Reports of the first two patients with aHUS successfully treated with Eculizumab were published in 2009.^{44,45} The first case was an 18-month old baby with non-identified genetic defect resistant to plasma therapy, where a 4-month treatment with Eculizumab induced disease remission.⁴⁴ In a second patient of 37 years with a deficit in factor H, a single 600mg Eculizumab dose was enough to treat disease recurrence after kidney transplant.⁴⁵ These reports have been followed by many others, where Eculizumab has been used to treat primary aHUS and for the treatment of post-transplant recurrences. In two recent prospective trials, Eculizumab inhibited complement-mediated thrombotic microangiopathy and was associated with significant time-dependent improvement in renal function in patients with aHUS.⁴⁶ These data indicate that terminal complement inhibition with Eculizumab inhibits complement-mediated thrombotic microangiopathy, decreases the need for thrombotic microangiopathy-related intervention, significantly improves the platelet count and renal function across patient groups, and is associated with substantial kidney recovery and improved clinical outcomes in patients with aHUS.

These data support the use of Eculizumab for the treatment of aHUS and, as recently reported, also in the most severe cases of typical HUS⁴⁷ associated with shiga-toxin producing bacteria. Extremely high costs of this antibody, however, will

reviews

force world healthcare systems to confront and contemplate the economical sustainability of this treatment.

Dense deposit disease and C3 nephropathy

Dense deposit disease (DDD), also named type II MPGN, is characterized by the presence of electron dense material within glomerular basement membrane. This nephropathy is associated with an abnormal activation of complement alternative pathway secondary to genetic mutations in complement regulators or to the presence of autoantibodies inhibiting complement regulator activity. Eculizumab has been used to block complement activation in patients with DDD. In five cases, treatment was effective in reducing proteinuria, improving renal function, and histological lesions during one-year follow-up.^{41,42,48} In a sixth patient with DDD recurrence in the transplanted kidney, Eculizumab induced proteinuria remission after treatment with plasmapheresis, steroids, and Rituximab failed.⁴³ Eculizumab was employed also in three patients with C3 nephropathy, a disease characterized by the presence of subepithelial or mesangial electron dense deposits, and in two cases promoted renal function improvement or stabilization.⁴⁸

Recently, an 8-year-old child with C3 nephropathy and refractory DDD who presented with a nephritic syndrome was successfully treated with Eculizumab, after multiple treatments, including steroids and Rituximab, failed.⁴⁹

These initial experiences support the use of Eculizumab in patients affected by glomerulopathies secondary to complement alterations. On the other hand, the presence subjects resistant to this treatment suggest the existence of pathogenic elements alternative to complement dysregulation, at least in a minority of patients with DDD or C3 nephropathy. The study of these patients might therefore prove important for the understanding of the pathophysiology of these nephropathies and the definitions of new therapies. This is a crucial aspect of any treatment with monoclonals that, in contrast with other drugs lacking a specific mechanism of action, have the major advantage of providing helpful information regarding pathogenesis even in the cases where they are ineffective.

Safety

So far, Eculizumab has been administered to more than 1,000 patients with various indications. Reported adverse effects have been numerous, but of mild severity. The most severe adverse effect is linked to the Eculizumab-induced complement inhibition that increases the risk of infections by meningococcus, a capsulate microorganism whose clearance is largely based on complement activity.⁹ This risk can be prevented by vaccinating patients before Eculizumab exposure

and by performing a prophylaxis with penicillin during the treatment period. Up to date, no strain of meningococcus resistant to this antibiotic has been reported.

FRESOLIMUMAB

TGF- β 1 has been long considered a key mediator of renal fibrosis by activating its downstream Smad signaling pathway. More recently, TGF- β has been recognized also as a key regulator of podocyte function. Both FSGS patients and experimental models of the disease demonstrate increased expression of TGF- β in the kidney and in the urine. Overexpression of TGF- β in podocytes leads to podocytopenia and glomerulosclerosis. In cultured podocytes, TGF- β influences cell survival and induces changes in the cytoskeleton and cell adhesion that are analogous to *in vivo* foot process effacement. These findings suggest that targeting TGF- β in the kidney may be renoprotective and have a beneficial effect on the severity or progression of FSGS.⁵⁰

Fresolimumab is a humanized monoclonal antibody able to neutralize all three isoforms of TGF- β . A phase I clinical trial in 16 patients with treatment-resistant primary FSGS and nephrotic-range proteinuria showed that Fresolimumab is well tolerated and is associated with a trend toward proteinuria reduction, especially in black patients.⁵⁰ A larger phase II trial is testing the safety/efficacy profile of Fresolimumab versus placebo in 88 patients with steroid-resistant FSGS (ClinicalTrials.gov: NCT01665391).

ADALIMUMAB

Tumor necrosis factor- α (TNF- α) is an inflammatory cytokine produced by a wide range of cells including macrophages and renal tubular epithelial cells. TNF- α has been implicated in the pathogenesis of proteinuria in FSGS through recruitment of leukocytes to the glomeruli, induction of cytokines and growth factor release, generation of oxygen radicals, and induction of cell apoptosis.⁵¹ Consistently, experimental models of FSGS and affected patients display high renal TNF- α and TNF- α produced by mononuclear cells of FSGS patients induces proteinuria in animals. Importantly, TNF- α antagonism reduced proteinuria in the angiotensin II-induced renal injury model and other models that resemble FSGS.⁵¹

A phase I study showed that 16 weeks of treatment with Adalimumab, a monoclonal antibody against TNF- α , promoted a stabilization of renal function and a reduction in proteinuria in 10 patients with steroid-resistant FSGS.⁵¹ A phase II study is testing the safety/efficacy profile in a larger cohort of patients with steroid-resistant FSGS (NCT00814255).

ABATACEPT

Various animal models of proteinuria are associated with an upregulation of B7-1 (CD80) in podocytes. B7-1 expression is not evident in normal human kidney podocytes but is found in patients with glomerular diseases. Yu et al. recently introduced a new classification of proteinuric kidney diseases by dividing them into B7-1-positive or B7-1-negative. These authors found that B7-1-positive podocytes have a reduced capacity to attach to the surrounding matrix through $\beta 1$ integrin. B7-1-positive podocytes change their morphologic characteristics and their function, leading to detachment of their foot processes from the glomerular basement membrane and giving rise to proteinuria.⁵²

Abatacept (CTLA-4-Ig) is a fusion protein composed of the Fc region of the immunoglobulin IgG1 fused to the extracellular domain of CTLA4, able to inhibit the costimulatory signaling of T cells. Approved for the treatment of rheumatoid arthritis, Abatacept reduced proteinuria in four patients with severe nephrotic syndrome due to primary FSGS and in one with recurrent FSGS after transplantation. Two randomized controlled clinical trials of Abatacept for the treatment of proliferative LN are currently underway. One study is evaluating the efficacy of Abatacept versus placebo on top of MMF and steroids (NCT00430677), and the other one in association with intravenous cyclophosphamide (NCT00774852).

BELIMUMAB

Belimumab is a humanized monoclonal antibody that binds to soluble human BLyS and inhibits its biologic

activity, which eventually restrains B cell proliferation. A large randomized placebo-controlled trial (BLISS-52) of 867 patients with erythematous lupus showed that add-on Belimumab on top of standard maintenance therapy significantly improved persistent disease activity up to 72 weeks.⁵³ This study led to the US Food and Drug Administration and European Medicines Agency approval of Belimumab for nonrenal lupus. The specific effect of the addition of Belimumab on renal function or proteinuria among patients with renal involvement was not described. This study demonstrated a beneficial effect of Belimumab in addition to standard immunosuppression in patients with SLE. The currently available data do not address its effect on renal disease. Whether Belimumab has a role in the treatment of LN, especially when associated with moderate to severe renal dysfunction, or rapid loss of function is unknown and still awaits *ad hoc* studies. However, promising data from patients with moderate nephritis enrolled in the BLISS-56 trial raise hope that Belimumab could also be efficient in severe LN.

Acknowledgments

We are indebted to Jesus Arteaga and Jeremy Leventhal for their helpful suggestions.

Conflict of interest

The authors declare that there is no conflict of interest associated with this manuscript.

KEY POINTS

1. Growing availability of monoclonal antibodies is quickly changing the way immune mediated glomerular diseases are treated and is helping translating in the clinical practice results from basic research pathophysiology studies.
2. Results from prospective trials consistently showed that anti-CD20 depleting antibody Rituximab safely reduced proteinuria in patients with nephrotic syndrome associated with membranous nephropathy and multirelapsing minimal change disease or FSGS.
3. Eculizumab, a monoclonal antibody targeting the complement component C5, has become standard of care treatment for atypical hemolytic uremic syndrome and C3 nephropathy.
4. Encouraging results from small, pilot studies are showing the efficacy of Abatacept (CTLA4Ig), Adalimumab (anti-TNF- α), Belimumab (anti-BLyS), Fresolimumab (anti-TGF- β) in reducing proteinuria in different glomerular diseases, including FGSG and lupus nephritis.
5. Due to the high costs of monoclonals, identification of optimal doses to use in glomerular diseases will be instrumental for their clinical implementation, especially in resource-limited settings.

REFERENCES

1. Remuzzi G, Chiurciu C, Abbate M, Bruségan V, Bontempelli M, Ruggenenti P. Rituximab for idiopathic membranous nephropathy. *Lancet* 2002;360:923-4.
2. Carson KR, Evens AM, Richey EA, Habermann TM, Focosi D, Seymour JF, et al. Progressive multifocal leukoencephalopathy after Rituximab therapy in HIV-negative patients: a report of 57 cases from the Research on Adverse Drug Events and Reports project. *Blood* 2009;113:4834-40.
3. Abbate M, Zoja C, Morigi M, Rottoli D, Angioletti S, Tomasoni S, et al. Transforming growth factor- β 1 is up-regulated by podocytes in response to excess intraglomerular passage of proteins: a central pathway in progressive glomerulosclerosis. *Am J Pathol* 2002;161:2179-93.
4. Pepper R, Griffith M, Kirwan C, Levy J, Taube D, Pusey C, et al. Rituximab is an effective treatment for lupus nephritis and allows a reduction in maintenance steroids. *Nephrol Dial Transplant* 2009;24:3717-23.
5. Lindholm C, Borjesson-Asp K, Zendjanchi K, Sundqvist AC, Tarkowski A, Bokarewa M. Longterm clinical and immunological effects of anti-CD20 treatment in patients with refractory systemic lupus erythematosus. *J Rheumatol* 2008;35:826-33.
6. Ruggenenti P, Cravedi P, Chianca A, Perna A, Ruggiero B, Gaspari F, et al. Rituximab in idiopathic membranous nephropathy. *J Am Soc Nephrol* 2012;23:1416-25.
7. Meyrier A. An update on the treatment options for focal segmental glomerulosclerosis. *Expert Opin Pharmacother* 2009;10:615-28.
8. Salama AD, Pusey CD. Drug insight: Rituximab in renal disease and transplantation. *Nat Clin Pract Nephrol* 2006;2:221-30.
9. Perkins JM, Davis SN. The renin-angiotensin-aldosterone system: a pivotal role in insulin sensitivity and glycemic control. *Curr Opin Endocrinol Diabetes Obes* 2008;15:147-52.
10. Ronco P, Debiec H. Antigen identification in membranous nephropathy moves toward targeted monitoring and new therapy. *J Am Soc Nephrol* 2010;21:564-9.
11. Ruggenenti P, Cravedi P, Remuzzi G. Latest treatment strategies for membranous nephropathy. *Expert Opin Pharmacother* 2007;8:3159-71.
12. Cravedi P, Ruggenenti P, Sghirlanzoni MC, Remuzzi G. Titrating Rituximab to circulating B cells to optimize lymphocytolytic therapy in idiopathic membranous nephropathy. *Clin J Am Soc Nephrol* 2007;2:932-7.
13. Cravedi P, Sghirlanzoni MC, Marasa M, Salerno A, Remuzzi G, Ruggenenti P. Efficacy and safety of Rituximab second-line therapy for membranous nephropathy: a prospective, matched-cohort study. *Am J Nephrol* 2011;33:461-8.
14. Ruggenenti P, Cravedi P, Sghirlanzoni MC, Gagliardini E, Conti S, Gaspari F, et al. Effects of Rituximab on morphofunctional abnormalities of membranous glomerulopathy. *Clin J Am Soc Nephrol* 2008;3:1652-9.
15. Hodson E, Craig J. Therapies for steroid-resistant nephrotic syndrome. *Pediatr Nephrol* 2008;23:1391-4.
16. Elie Vr, Fakhoury M, Deschênes G, Jacqz-Aigrain E. Physiopathology of idiopathic nephrotic syndrome: lessons from glucocorticoids and epigenetic perspectives. *Pediatr Nephrol* 2012;27:1249-56.
17. Tarshish P, Tobin JN, Bernstein J, Edelmann CM. Prognostic significance of the early course of minimal change nephrotic syndrome: report of the International Study of Kidney Disease in Children. *J Am Soc Nephrol* 1997;8:769-76.
18. Bargman JM. Management of minimal lesion glomerulonephritis: evidence-based recommendations. *Kidney Int Suppl* 1999;70:S3-16.
19. Benz K, Dosch J, Rascher W, Stachel D. Change of the course of steroid-dependent nephrotic syndrome after Rituximab therapy. *Pediatr Nephrol* 2004;19:794-7.
20. Kamei K, Ito S, Nozu K, Fujinaga S, Nakayama M, Sako M, et al. Single dose of Rituximab for refractory steroid-dependent nephrotic syndrome in children. *Pediatr Nephrol* 2009;24:1321-8.
21. Kemper MJ, Gellermann J, Habbig S, Krmar RT, Dittrich K, Jungraithmayr T, et al. Long-term follow-up after Rituximab for steroid-dependent idiopathic nephrotic syndrome. *Nephrol Dial Transplant* 2012;27:1910-5.
22. Ravani P, Ponticelli A, Siciliano C, Fornoni A, Magnasco A, Sica F, et al. Rituximab is a safe and effective long-term treatment for children with steroid and calcineurin inhibitor-dependent idiopathic nephrotic syndrome. *Kidney Int* 2013;84:1025-33.
23. Ruggenenti P, Ruggiero B, Cravedi P, Vivarelli M, Massella L, Marasà M, et al. Rituximab in Steroid-Dependent or Frequently Relapsing Idiopathic Nephrotic Syndrome. *J Am Soc Nephrol* 2014 Jan 30.[Epub ahead of print]
24. Kamei K, Okada M, Sato M, Fujimaru T, Ogura M, Nakayama M, et al. Rituximab treatment combined with methylprednisolone pulse therapy and immunosuppressants for childhood steroid-resistant nephrotic syndrome. *Pediatr Nephrol* 2014 Feb 6. [Epub ahead of print]
25. Magnasco A, Ravani P, Edefonti A, Murer L, Ghio L, Belingheri M, et al. Rituximab in children with resistant idiopathic nephrotic syndrome. *J Am Soc Nephrol* 2012;23:1117-24.
26. Tanaka Y, Yamamoto K, Takeuchi T, Nishimoto N, Miyasaka N, Sumida T, et al. A multicenter phase I/II trial of Rituximab for refractory systemic lupus erythematosus. *Mod Rheumatol* 2007;17:191-7.
27. Melander C, Sallee M, Trolliet P, Candon S, Belenfant X, Daugas E, et al. Rituximab in severe lupus nephritis: early B-cell depletion affects long-term renal outcome. *Clin J Am Soc Nephrol* 2009;4:579-87.
28. Rovin BH, Furie R, Latinis K, Looney RJ, Fervenza FC, Sanchez-Guerrero J, et al. Efficacy and safety of Rituximab in patients with active proliferative lupus nephritis: The lupus nephritis assessment with Rituximab study. *Arthritis Rheum* 2012;64:1215-26.
29. Merrill JT, Neuwelt CM, Wallace DJ, Shanahan JC, Latinis KM, Oates JC, et al. Efficacy and safety of Rituximab in moderately-to-severely active systemic lupus erythematosus: The randomized, double-blind, phase II/III systemic lupus erythematosus evaluation of Rituximab trial. *Arthritis Rheum* 2010;62:222-33.
30. Weidenbusch M, Rammele C, Schratte A, Anders H-J. Beyond the LUNAR trial. Efficacy of Rituximab in refractory lupus nephritis. *Nephrol Dial Transplant* 2013;28:106-11.
31. Popa ER, Stegeman CA, Bos NA, Kallenberg CG, Tervaert JW. Differential B- and T-cell activation in Wegener's granulomatosis. *J Allergy Clin Immunol* 1999;103:885-94.
32. Jones RB, Tervaert JW, Hauser T, Luqmani R, Morgan MD, Peh CA, et al. Rituximab versus cyclophosphamide in ANCA-associated renal vasculitis. *N Engl J Med* 2010;363:211-20.
33. Specks U, Merkel PA, Seo P, Spiera R, Langford CA, Hoffman GS, et al. Efficacy of remission-induction regimens for ANCA-associated vasculitis. *N Engl J Med* 2013;369:417-27.

34. Terrier B, Krastinova E, Marie I, Launay D, Lacraz A, Belenotti P, et al. Management of noninfectious mixed cryoglobulinemia vasculitis: data from 242 cases included in the CryoVas survey. *Blood* 2012;119:5996-6004.
35. Saadoun D, Resche Rigon M, Sene D, Terrier B, Karras A, Perad L, et al. Rituximab plus Peg-interferon- α /ribavirin compared with Peg-interferon- α /ribavirin in hepatitis C-related mixed cryoglobulinemia. *Blood* 2010;116:326-34; quiz 504-5.
36. Visentini M, Ludovisi S, Petrarca A, Pulvirenti F, Zaramella M, Monti M, et al. A phase II, single-arm multicenter study of low-dose Rituximab for refractory mixed cryoglobulinemia secondary to hepatitis C virus infection. *Autoimmun Rev* 2011;10:714-9.
37. Gabardi S, Martin ST, Roberts KL, Grafals M. Induction immunosuppressive therapies in renal transplantation. *Am J Health Syst Pharm* 2011;68:211-8.
38. Fervenza FC, Abraham RS, Erickson SB, Irazabal MV, Eirin A, Specks U, et al. Rituximab therapy in idiopathic membranous nephropathy: a 2-year study. *Clin J Am Soc Nephrol* 2010;5:2188-98.
39. Hillmen P, Young NS, Schubert J, Brodsky RA, Socié G, Muus P, et al. The complement inhibitor eculizumab in paroxysmal nocturnal hemoglobinuria. *N Engl J Med* 2006;355:1233-43.
40. Radhakrishnan S, Lunn A, Kirschfink M, Ono S. Eculizumab and refractory membranoproliferative glomerulonephritis. *N Engl J Med* 2012;366:1165-6.
41. Vivarelli M, Pasini A, Emma F. Eculizumab for the treatment of dense-deposit disease. *N Engl J Med* 2012;366:1163-5.
42. Daina E, Noris M, Remuzzi G. Eculizumab in a patient with dense-deposit disease. *N Engl J Med* 2012;366:1161-3.
43. McCaughan JA, O'Rourke DM, Courtney AE. Recurrent dense deposit disease after renal transplantation: an emerging role for complementary therapies. *Am J Transplant* 2012;12:1046-51.
44. Gruppo RA, Rother RP. Eculizumab for congenital atypical hemolytic-uremic syndrome. *N Engl J Med* 2009;360:544-6.
45. Nurnberger J, Philipp T, Witzke O, Opazo Saez A, Vester U, Baba HA, et al. Eculizumab for atypical hemolytic-uremic syndrome. *N Engl J Med* 2009;360:542-4.
46. Legendre CM, Babu S, Furman RR, et al. Safety & Efficacy of Eculizumab in aHUS Patients Resistant to Plasma Therapy: Interim Analysis from a Phase II Trial. *J Am Soc Nephrol* 2010;21(suppl):402A abstr FH P0/274.
47. Lapeyraque A-L, Malina M, Fremeaux-Bacchi V, Boppel T, Kirschfink M, Oualha M, et al. Eculizumab in severe Shiga-toxin-associated HUS. *N Engl J Med* 2011;364:2561-3.
48. Bomback AS, Smith RJ, Barile GR, Zhang Y, Heher EC, Herlitz L, et al. Eculizumab for dense deposit disease and C3 glomerulonephritis. *Clin J Am Soc Nephrol* 2012;7:748-56.
49. Rousset-Rouvière C, Cailliez M, Garaix F, Bruno D, Laurent D, Tsimaratos M. Rituximab fails where eculizumab restores renal function in C3nef-related DDD. *Pediatr Nephrol* 2014 Jan 10. [Epub ahead of print]
50. Trachtman H, Fervenza FC, Gipson DS, Heering P, Jayne DR, Peters H, et al. A phase 1, single-dose study of fresolimumab, an anti-TGF- β antibody, in treatment-resistant primary focal segmental glomerulosclerosis. *Kidney Int* 2011;79:1236-43.
51. Joy MS, Gipson DS, Powell L, MacHardy J, Jennette JC, Vento S, et al. Phase 1 trial of adalimumab in focal segmental glomerulosclerosis (FSGS): II. Report of the FONT (Novel Therapies for Resistant FSGS) study group. *Am J Kidney Dis* 2010;55:50-60.
52. Yu C-C, Fornoni A, Weins A, Hakrrouch S, Maignel D, Sageshima J, et al. Abatacept in B7-1-positive proteinuric kidney disease. *N Engl J Med* 2013;369:2416-23.
53. Navarra SV, Guzmán RM, Gallacher AE, Hall S, Levy RA, Jimenez RE, et al. Efficacy and safety of belimumab in patients with active systemic lupus erythematosus: a randomised, placebo-controlled, phase 3 trial. *Lancet* 2011;377:721-31.