

First case of peritoneal infection due to *Oerskovia turbata* (*Cellulosimicrobium funkei*)

Nefrologia 2011;31(2):223-5

doi:10.3265/Nefrologia.pre2010.Nov.10508

To the Editor,

Peritoneal infection (PI) or peritonitis is a common complication in peritoneal dialysis (PD). It can damage the peritoneal membrane, compromise the technique's survival rate and is the main cause for transfer to haemodialysis.¹ Most PI episodes are due to gram-positive cocci, although an increase in PI due to gram-negative bacilli is being observed, with worse clinical prognosis.²

Oerskovia infections are rare in humans. There are only four *oerskovia* PI cases published.^{3,6} It consists of two large species: *Oerskovia xanthineolytica* (*O. xanthineolytica*) and *Oerskovia turbata* (*O. turbata*), which are currently known as *Cellulosimicrobium cellulans*⁷ and *Cellulosimicrobium funkei*, respectively,⁸ according to comparative phylogenetic analysis based on 16S ribosomal rRNA gene sequences. They are gram-positive bacilli found in the ground, pastures and water from different parts of the world. Colonies are characterised by a yellow pigment with branching vegetative hyphae which penetrate in the agar.^{9,10}

Below, we describe the first peritonitis case caused by *O. turbata* in a patient undergoing automated peritoneal dialysis (APD), and have also reviewed published cases.

We present the case of a 62-year-old man, with a history of high blood pressure, dyslipaemia, stroke and ischaemic heart disease. He started APD in August 2006 following bilateral kidney nephrectomy for

transitional cell carcinoma. He presented with his first *Pasteurella multocida* PI in October 2008, which was presumably induced by contact with a cat.

In July 2009, he had his second PI. He started drug treatment with vancomycin, intraperitoneal gentamicin, and ciprofloxacin orally. On the third day, gram-positive bacilli growth was found with a preliminary identification of *Oerskovia* sp. On the sixth day, the antibiogram showed an intermediate sensitivity to ciprofloxacin and sensitivity to cotrimoxazole. Ciprofloxacin was then replaced with oral co-trimoxazole, intraperitoneal vancomycin regimen was continued every 5 days, and gentamicin was withdrawn. On the tenth day, peritoneal fluid was clear. Antibiotic treatment was maintained for 22 days.

Thirteen days after finishing the antibiotic treatment, the patient had a PI relapse. Treatment using vancomycin, intraperitoneal gentamicin and oral cotrimoxazole was restarted, using fluconazole as prophylaxis. On the third day, fluid was clear and *Oerskovia* sp growth was resistant to co-trimoxazole, and sensitive to ciprofloxacin. The antibiotic regimen was therefore changed: gentamicin was withdrawn and vancomycin maintained. Twenty-one days after antibiotic treatment, he had a second PI relapse. The PD was removed and the patient was transferred to haemodialysis. Catheter culture was negative.

Microbiology

The peritoneal fluids were collected in aerobic and anaerobic bottles for BacT/Alert blood culture test (bioMérieux, Durham, NC, USA). Both bottles were found to be positive at between 23 and 24 hours, and the gram staining revealed branching gram-positive bacilli. Chocolate agar, blood agar, and colistin-nalidixic acid

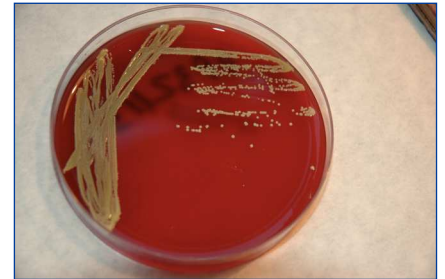

Figure 1. *Oerskovia* culture on a blood agar plate

(CNA) agar were reseeded on blood agar plates, which were incubated at 35°C in 5% CO. Some colony growth was observed at 48-72 hours. It was the characteristic pastel yellow colour (Figure 1). The colonies were catalase-positive and oxidase-negative, and were identified using API Coryne galleries (bioMérieux, Marcy L'Étoile, France). It had the code 7572727, with an *Oerskovia* sp. percentage of 99.9%. Later, we completed the 16S rRNA sequencing, and the phylogenetic gene sequence analysis confirmed *Cellulosimicrobium funkei*.

Review of the PI due to *Oerskovia* cases

We have found four cases of PI due to *O. xanthineolytica* PD in the literature. Catheter removal was necessary in two of these cases.^{3,6} Cases with good progress were treated with intraperitoneal antibiotics for 15 days^{4,5} (Table 1).

We would like to present the first PI due to *O. turbata*. This species is less frequent in human infections than *O. xanthineolytica* according to the review published in 2006.⁷ This is the first case of infection caused by *Oerskovia* diagnosed in our health centre. At present, according to the comparative phylogenetic analysis based on 16S rRNA gene sequence, it is called *Cellulosimicrobium*.

Human infections due to *Oerskovia* develop in immunosuppressed patients

Table 1. Review of cases of PI caused by *Oerskovia*

Reference	Patient	Species	PD time PD type	Treatment antibiotic	Withdrawal catheter
Rihs JD, CM 1990	70-year-old man	<i>O. xanthineolytica</i>	11 years CAPD	Vancomycin and gentamicin	Yes
Borra S, AJKD 1996	59-year-old woman	<i>O. xanthineolytica</i>	6 weeks CAPD	Vancomycin and Doxycycline	No
Lujan-Zilbermann, J PIDJ 1999	13-year-old man	<i>O. xanthineolytica</i>	11 month CAPD	Vancomycin	No
Moyano MJ, Annual meeting DP 2010	75-year-old man	<i>O. xanthineolytica</i>	4 years CAPD	Vancomycin	Yes
Our case, 2010	62-year-old man	<i>O. turbata</i>	3 years CAPD	Vancomycin ciprofloxacin and co-trimoxazole	Yes

and foreign body carriers: central catheters, valvular and joint prostheses, and peritoneal dialysis catheters.^{3-7,9,11} In some cases, the origin of the infection has been related to working or living in rural areas.^{5,10}

More than one antibiotic may be necessary and the foreign body may need to be removed. In all cases the germ has been sensitive to the antibiotic treatment in *in vitro* tests, although *in vivo* results have been poor.⁷ Our case, despite correct antibiotic treatment, did not manage to eradicate the infection and the PD catheter had to be removed.

This bacterium is resistant, although not especially virulent, given that no deaths have been recorded.^{7,12} Most infections caused by *O. turbata* have been in immunosuppressed patients.¹³⁻¹⁵ Our patient lived in an urban area and had a pet cat, but there are no references that show a relationship between infections caused by *Oerskovia* and domestic animals.

The *Oerskovia* genus is often *in vitro* resistant to penicillin, aminoglycosides, macrolides and cephalosporins, and intermediate resistance to ciprofloxacin. It is considered *in vitro* sensitive to vancomycin and rifampicin.^{7,12} In this instance, the germ was sensitive to vancomycin, rifampicin, meropenem and co-

trimoxazole, and was intermediate sensitive to ciprofloxacin. Given that there are no standardised minimal inhibitory concentration (MIC) values to study the sensitivity of this bacterium, we used the MIC for *Corynebacterium* sp.

To conclude, PIs caused by *Oerskovia* are rare despite it being a germ that is widely distributed in nature. 1.

1. Davenport A. Peritonitis remains the major clinical complications of peritoneal dialysis: the London, UK, peritonitis audit 2002-2003. *Perit Dial Int* 2009;29:297-302.
2. Jarvis EM, Hawley CM, McDonald SP, Brown FG, Rosman JB, Wiggins KL, et al. Predictors, treatment and outcomes of non-*Pseudomonas* Gram-negative peritonitis. *Kidney Int* 2010; May 26 (epub).
3. Rihs JD, McNeil MM, Brown JM, Yu VL. *Oerskovia xanthineolytica* Implicated in Peritonitis Associated with Peritoneal Dialysis: Case Report and review of *Oerskovia* Infections in Humans. *J Clin Microbiol* 1990;27:1934-7.
4. Borra S, Kleinfeld M. Peritonitis caused by *Oerskovia xanthineolytica* in a patient on chronic ambulatory peritoneal dialysis (CAPD). *Am J Kidney Dis* 1996;27:458.
5. Lujan-Zilbermann J, Jones D, DeVincenzo J. *Oerskovia xanthineolytica* peritonitis: Case Report and Review. *Pediatr Infect Dis J* 1999;18:738-9.
6. Moyano MJ, Aresté N, Suárez A, Páez C, Ortega R, Milán JA. Peritonitis por

Oerskovia xanthineolytica en paciente en diálisis peritoneal. Publicación Póster. La Coruña: VII Reunión nacional de Diálisis Peritoneal, 4-6 de febrero de 2010.

7. Rowlinson MC, Bruckner DA, Hinnebusch C, Nielsen K, Deville JG. Clearance of *Cellulosimicrobium cellulans* bacteriemia in a Child without Central Venous Catheter Renal. *J Clin Microbiol* 2006;44:2650-4.
8. Brown JM, Steigerwalt AG, Money RE, Daneshvar MI, Romero LJ, McNeil MM. Characterization of clinical isolates previously identified as *Oerskovia turbata*: proposal of *Cellulosimicrobium funkei* sp. Nov. and emended description of the genus *Cellulosimicrobium*. *Intern J Syst Evol Microbiol* 2006;56:801-4.
9. Reller LB, Maddoux GL, Mark MD, Eckman R, Pappas G. Bacterial Endocarditis Caused by *Oerskovia turbata*. *Ann Intern Med* 1975;83:664-6.
10. Cruickshank JG, Gawler AH, Shalton C. *Oerskovia* species: Rare opportunistic pathogens. *J Med Microbiol* 1979;12:513-5.
11. Harrington RD, Lewis CG, Aslanzadeh J, Stelmach P, Woolfrey AE. *Oerskovia xanthineolytica* Infection of a Prosthetic Joint: Case report and Review. *J Clin Microbiol* 1996;34:1821-4.
12. Tucker JD, Montecino R, Winograd JM, Ferraro MJ, Michelow IC. Pyogenic Flexor Tenosynovitis Associated with *Cellulosimicrobium cellulans*. *J Clin Microbiol* 2008;46:4106-8.
13. LeProwse CR, McNeil MM, Mc Carty JM. Catheter-Related Bacteriemia Caused by *Oerskovia turbata*. *J Clin Microbiol* 1989;27:571-2.
14. Reina J, Llopart I, Altes J. Absceso axilar producido por *Oerskovia turbata* en un paciente de SIDA. *Rev Clin Esp* 1991;188:485-6.
15. Lair MI, Bentolila S, Grenet D, Cahen D, Honderlick P. *Oerskovia turbata* and *Comamonas acidovorans* Bacteremia in a Patient with AIDS. *Eur J Clin Microbiol Infect Dis* 1996;15:424-6.

L. Betancourt Castellanos¹, E. Ponz Clemente¹, D. Fontanals Aymerich², C. Blasco Cabañas¹, D. Marquina Parra¹, C. Grau Pueyo¹, M. García García¹

¹ Nephrology Department. Parc Taulí Health Corporation. Parc Taulí University Institute (UAB). Sabadell, Barcelona, Spain.

² Microbiology Laboratory. Parc Taulí Health Corporation. Parc Taulí University Institute.

Correspondence: L. Betancourt Castellanos
Servicio de Nefrología.

Corporación Sanitaria Parc Taulí.

Institut Universitari Parc Taulí (UAB), Parc Taulí s/n. 08203 Sabadell. Barcelona. Spain.

lorelaybc@hotmail.com

eponz@tauli.cat

A patient with acute renal failure and episcleritis, is there more than meets the eye?

Nefrología 2011;31(2):225-6

doi:10.3265/Nefrología.pre2010.Dec.10753

Dear Editor,

The kidney and the eye, with their characteristic vascular anatomy, are vulnerable to vasculitis syndromes like antineutrophil cytoplasmic antibodies (ANCA) associated small vessel vasculitis.¹⁻³

Here we present a case of a 44 year old male patient complained of asthenia for one month. Two weeks before he developed bilateral subconjunctival hemorrhage without photophobia or ocular pain. The patient denied epistaxis, hemoptysis, abdominal pain, arthralgias or myalgias. On examination he had subconjunctival bleeding due to bilateral diffuse episcleritis (Figure 1). There were no cardiopulmonary auscultatory findings, no purpura and no signs of arthritis. The patient past medical history was remarkable for chronic sinusitis with frequent episodes of epistaxis. The blood panel showed severe azotemia (serum creatinine 11,2 mg/dl, BUN 100 mg/dl), normocytic normochromic anaemia (Hb 11,3 g/dl; Ht 33,3%), C-reactive protein 16,9 mg/L (0-10 mg/L), active urinary sediment (30 red blood cells per high-power field, 4 red blood cell casts), and a 24 hour proteinuria of

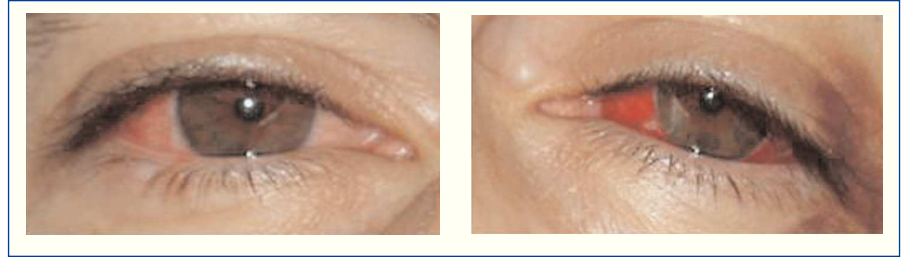

Figure 1. Subconjunctival bleeding due to diffuse episcleritis.

2,2 g. Renal imaging revealed normal size kidneys and normal corticomedullary differentiation. Hemodialysis was initiated due to uremic syndrome. Chest X-ray and chest CT scan did not show any evidence of active disease in the lower respiratory tract. Nasal sinus CT scan was compatible with a previous history of chronic sinusitis involving right ethmoidal and both maxillary sinus. Nasal mucosa biopsy showed a non-specific inflammatory process. Serologic panel was negative for HIV1 and 2, HBV and HCV infection, complement fractions were within normal range. The immunological study was positive for circulating C-ANCA with anti-proteinase 3 (PR3) activity confirmed by enzymatic immunoassay (ELISA), and negative for anti-nuclear, anti DNAs and anti-glomerular basement membrane (anti-GBM) antibodies. The renal biopsy revealed a segmentar necrotizing glomerulonephritis with circumferential crescents in more than 80% of glomeruli (Figure 2). Immunofluorescence microscopy was compatible with a pauci-immune glomerulonephritis. The above investigation confirmed the diagnosis of ANCA associated small vessel vasculitis and the patient initiated treatment with cyclophosphamide (100 mg id po), methylprednisolone (1 g id ev) changed to prednisolone (70 mg id po) after 3 days, and prophylactic antibiotherapy with trimethoprim/sulfamethoxazole. On hospital day four, he had a complete remission of the oftalmic disease, maintaining severe renal failure. Three months later, our patient remained on hemodialysis due to severe azotemia, without glomerular hematuria. Since renal function did not recover and there was no evidence of active extrarenal

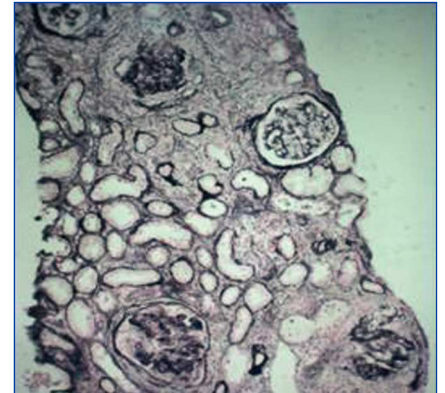


Figure 2. Cellular circumferential crescents in more than 80% of glomeruli (Silver stain, x100).

disease, immunosuppressants were discontinued.

The authors present a case report of systemic vasculitis associated with ANCAs with specificity for anti-proteinase 3 (PR3), with renal, upper respiratory tract and eye involvement suggestive of Wegener granulomatosis.

The specificity of ANCA and its role on prognosis was shown by a retrospective study by Sven Weidner, involving 80 patients with confirmed pathological diagnosis of pauci-immune glomerulonephritis. In this study, patients with PR3 ANCAs had a higher risk of progressing to end-stage renal disease (ESRD)⁴. The patient in our case report, besides having PR3 ANCAs, also presented with a pre-treatment serum creatinine above 500 μ mol/L (5,7 mg/dl), which also predicts a worse outcome⁴. As for the type and number of crescents, the presence of circumferential crescents in more