

9. Díaz-Guzmán E, Culver DA, Stoller JK. Transudative chylothorax: report of two cases and review of the literature. *Lung* 2005; 183 (3): 169-75.
10. Browse NL, Allen DR, Wilson NM. Management of chylothorax. *Br J Surg* 1997; 84 (12): 1711-6.
11. Veroux P, Veroux M, Bonanno MG, Tumminelli MG, Baggio E, Petrillo G. Long-term success of endovascular treatment of benign superior vena cava occlusion with chylothorax and chylopericardium. *Eur Radiol* 2002;12 Supl. 3: S181-4.
12. Zoetmulder F, Rutgers E, Baas P. Thoracoscopic ligation of a thoracic duct leakage. *Chest* 1994;106 (4):1233-4.

M. Torres Guinea, G. De Arriba, M.^a A. Basterrechea and J. Ocaña
Nefrología. Hospital Universitario de Guadalajara. Departamento de Medicina. Universidad de Alcalá.

Correspondence: Gabriel de Arriba. *garrabad@senefro.org. Hospital Universitario de Guadalajara. Donante de sangre, s/n, 19002 Guadalajara.*

Mixed cryoglobulinemia in patients with dual HCV/HIV infection: analysis of cryoprecipitate as a therapeutic decision tool

Nefrología 2008; 28 (3) 355-356

To the editor: Infection by the hepatitis C virus (HCV) is the main cause of mixed cryoglobulinemia.^{1,2} However, the human immunodeficiency virus (HIV) also causes cryoglobulinemia.³ In high-risk people, dual HIV/HCV infection is common. The decision to add treatment for HCV to antiretroviral medication is difficult, because it may be harmful in immunodepressed individuals. A more precise diagnosis is also required because occult infection exists, with a falsely negative antibody test.⁴

In order to contribute to solve this problem, we studied cryoprecipitates from HIV-positive patients with cryoglobulinemia and membranoproliferative glomerulonephritis (MPGN). Serologic tests were positive for HIV/HCV in one patient, and for HIV alone in two patients.

The result was markedly clear: in the patient with dual infection, the cryopre-

cipitate only showed anti-HCV activity, while in the two patients with HIV infection alone, the cryoprecipitate only showed anti-HIV activity. These data allowed for taking the decision that only one patient had to be receive treatment for HCV.

CASE 1

A 45-year old male with HIV and HCV infection (genotype 1a) on antiretroviral therapy and with negative HIV load. In March 2007, the patient experienced nephrotic syndrome, and was diagnosed MPGN (table I). Cryoprecipitate was positive for HCV alone, and additional treatment with alpha-interferon was started.

CASE 2

A 36-year old male with HIV infection detected two years before and diagnosed of non-Hodgkin lymphoma in May 2006. He then had nephrotic syndrome with normal kidney function and positive cryoglobulins (table I). No antibodies to hepatitis C and B viruses were detected, and type I MPGN was diagnosed. Cryoprecipitate was positive for HIV and negative for HCV. Antiretroviral and chemotherapeutic therapy was started.

CASE 3

A 35-year old male with known HIV infection for eight years who showed

nephrotic proteinuria, normal kidney function, and positive cryoglobulins (table I). A type I MPGN was diagnosed. HIV was only shown to be present in the cryoprecipitate, and treatment with antiretrovirals and steroids alone was started.

In all three cases, the cryoprecipitate was separated from the supernatant by centrifugation (3,000 rpm at 4 °C), with adhered proteins being removed by washing with warm saline. Viral RNAs were extracted using Cobas-Amplipred (Roche). HIV and HCV loads were measured by RT-PCR using Cobas-Amplifcor ultrasensitive for HIV-1 (limit, 50 copies/mL) and by PCR, using Taq Man 48 for HCV (limit, 10 IU/mL).

Several studies have shown the relationship between HIV and HCV infections, and the role of cryoglobulins in causing renal damage, particularly MPGN.⁵⁻⁹ It is unknown whether the higher percentage of cryoglobulinemia found in cases with dual HIV/HCV infection² is due to one and/or the other virus.³ No reference has found in the literature with respects to the concomitant presence of both viral particles in the cryoprecipitate from patients with dual HIV/HCV infection.

Analysis of the cryoprecipitate is a useful tool for differential diagnosis of cryoglobulinemia in patients with dual HIV/HCV infection. It may also be used as a supplemental test to rule out a diagnosis in patients apparently mono-infected by HIV.

Table I. Main laboratory data from the three patients at the time of cryoprecipitate analysis

	Case 1	Case 2	Case 3
Plasma creatinine (mg/dL)	3.5	0.73	1.4
Plasma albumin (g/dL)	3	2.4	1.3
Proteinuria (g/24 hours)	9	4	5
Complement C3 (mg/dL)	109	49	111
Complement C4 (mg/dL)	47	24	24
Cryoglobulins	Positive	Positive	Positive
HIV viral load (copies/mL)	42	69,000	27,900
HCV viral load (copies/mL)	245,714	0	0
HIV viral load in cryoprecipitate (copies/mL)	0	1.200	700
HCV viral load in cryoprecipitate (copies/mL)	42,840	0	0
CD4 lymphocytes/mL	746	100	458

Table 1 shows the main laboratory data from the three patients at the time of cryoprecipitate analysis.

1. Poynard T, Ratziu V, Benhamou Y, Opolon P, Cacoub P, Bedossa P. Natural history of HCV infection. *Baillieres Best Pract Res Clin Gastroenterol* 2000; 14: 211-28.
2. Dezzutti CS, Astemborski J, Thomas DL, Marshall JH, Cabrera T, Purdy M, Vlahov D, Garfein RS. Prevalence of cryoglobulinemia in hepatitis C virus (HCV) positive patients with and without human immunodeficiency virus (HIV) coinfection. *J Clin Virol* 2004; 31: 210-214.
3. Bonnet F, Pineau JJ, Taupin JL, Feyley A, Bonarek M, De Witte S, Bernard N, Lacoste D, Morlat P, Beylot J. Prevalence of cryoglobulinemia and serological markers of autoimmunity in human immunodeficiency virus infected individuals: a cross-sectional study of 97 patients. *J Rheumatol* 2003; 30: 2005-10.
4. Bonacini M, Lin HJ, Hollinger FB. Effect of coexisting HIV-1 infection on the diagnosis and evaluation of hepatitis C virus. *J Acquir Immune Defic Syndr* 2001; 26: 340-4.
5. Germtholtz TE, Goetsch SJW and Katz I. HIV-related nephropathy: A south african perspective. *Kidney Int* 2006; 69: 1885-1891.
6. Sabry AA, Sobh MA, Irving WL et al. A comprehensive study of the association between hepatitis C virus and glomerulopathy. *NDT* 2002; 17: 239-245.
7. Johnson RF, Gretch DR, Yamabe H y cols. Membranoproliferative glomerulonephritis associated with hepatitis C virus infection. *N Engl J Med* 1993; 328: 465-470.
8. Chidambaram M, Stigant CE, Sugar LM, Rames Prasad GV. Type I membrano proliferative glomerulonephritis in an HIV-infected individual without hepatitis C co-infection. *Clin Nephrol* 2002; 57: 154-7.
9. Hoch B, Juknevičius I, Liapis H. Glomerular injury associated with hepatitis C infection: a correlation with blood and tissue HCV-PCR. *Semin Diagn Pathol* 2002; 19: 175-87.

S. Alexandru, C. Caramelo[†],
A. Montoya and R. García
Servicio de Nefrología-1. Servicio de Inmunología-2. Fundación Jiménez Díaz-Capio. Universidad Autónoma. Madrid. España
Correspondence: Simona Alexandru. *simona_amely@yahoo.com. Fundación Jiménez Díaz-Capio. Av. Reyes Católicos Nº 2. 28040 Madrid.*

Renal oncocytoma and papillary microcarcinoma coexistent with cystic disease acquired before dialysis

Nefrología 2008; 28 (3) 356-357

To the editor: We report the case of a 76-year old female patient with acqui-

red cystic disease (ACD) who underwent nephrectomy due to the occurrence of images suggesting malignancy leading to a diagnosis of associated oncocytoma and papillary microcarcinoma.

She had been diagnosed in 1982 of HBP without renal involvement, and experienced a cerebrovascular episode leaving no sequelae. In 1999 the patient showed clinical signs of nephrosis, and a biopsy revealed membranous glomerulonephritis (GM) resistant to steroids and azathioprine. She had glomerular filtration rates of approximately 50 mL/min and nephrotic proteinuria. Treatment was started in 2002 with mycophenolate mofetil with an excellent response. Proteinuria decreased from 12.9 g to 1.03 g in 6 months, and eventually disappeared in 3 years, with Cr levels of 1.6 mg/dL.

In December 2005, she was admitted for anuria, oedema, and infraabdominal pain, showing acute impairment in creatinine (3.5 mg/dL), proteinuria of 4.2 g/24 h, and haematuria of 100 cells per high-power field. Early haemodialysis was required. A new biopsy was reported as sclerosis in 50% of glomeruli. A majority of the other glomeruli showed extracapillary GN with epithelial crescents associated to GM, with moderate

interstitial fibrosis. Imaging studies found images suggesting ACD, particularly a 2.5-cm solid nodule in the upper pole of the right kidney, suspected to be malignant and for which nephrectomy was performed.

The specimen showed multiple cysts, and the 3-cm nodule was greyish green in colour. Microscopically, renal parenchyma was highly destructured, with sclerosis, crescents, and severe tubulointerstitial involvement, showing papillary and tubulopapillary adenomas, eventually forming a papillary microcarcinoma, and with abundant oncocytic changes, forming interstitial nodular aggregates. The biggest nodule was a conventional oncocytoma.

Coexistence of GM and extracapillary GN occurs in 3%-5% of biopsies with a main diagnosis of GM, either at the time of diagnosis or as transformation of a primary GM in cases of lymphoproliferative disease, vasculitis, collagen diseases...^{1,2} In this case, tumour degeneration of an ACD provides the additional mechanism of an extracapillary GN related to neoplasm.

ACD has been considered virtually exclusive of patients on dialysis, but age, grade of CKD, and particularly time since disease onset are also impor-

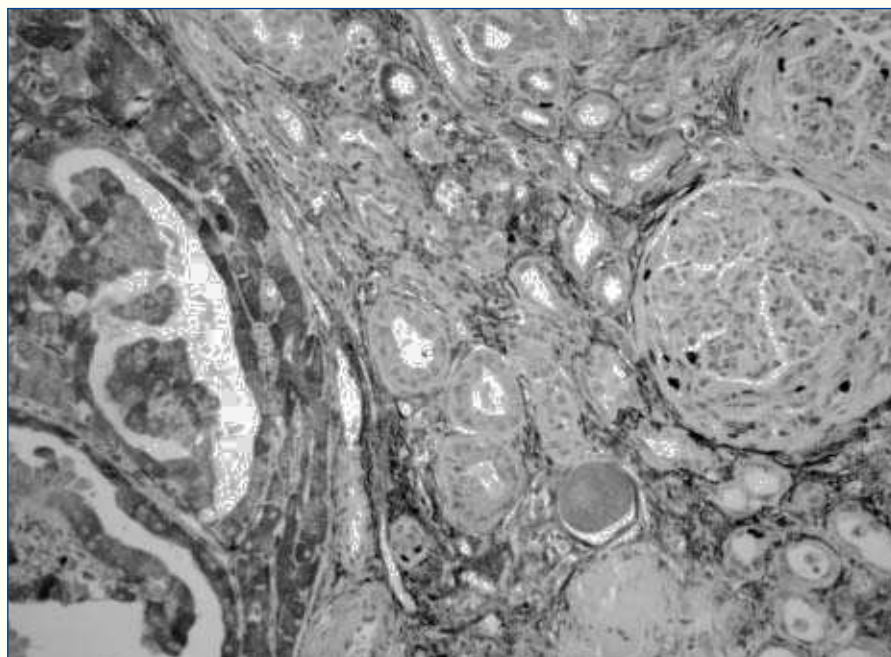


Figure 1. Epithelial crescents with significant proliferative activity close to oncocytic nodule (MIB 1).