

Sjögren's syndrome presenting as distal renal tubular acidosis

Ana R. Monteiro^{1*}, Ana I. Ferreira^{2*}, David Coelho³, Ester Ferreira², Jorge Santos Almeida²

¹Department of Medical Oncology. Instituto Português de Oncologia de Coimbra Francisco Gentil. Coimbra. Portugal

²Department of Internal Medicine. Centro Hospitalar Universitário de São João. Porto. Portugal

³Department of Pneumology. Centro Hospitalar Universitário de São João. Porto. Portugal

NefroPlus 2020;12(2):99-102

© 2020 Sociedad Española de Nefrología. Servicios de edición de Elsevier España S.L.U.

ABSTRACT

Distal renal tubular acidosis (dRTA) is a rare condition characterized by failure of the distal tubule in acidifying urine. Despite its rarity, this is the most frequent renal manifestation of primary Sjögren's Syndrome (pSS). This syndrome is a systemic autoimmune disorder that more commonly involves the exocrine glands and sicca syndrome is the most common form of presentation. Consequently, clinicians need to have a high degree of suspicion when pSS presents by dRTA. Herein, we describe a case of dRTA due to pSS successfully treated with supplementation and spironolactone.

Keywords: Sjögren's syndrome. Renal tubular acidosis. Hypokalemia. Spironolactone.

Acidosis tubular renal como manifestación inicial del síndrome de Sjögren

La acidosis tubular renal distal (ATRd) es una enfermedad rara que se caracteriza por un fallo del túbulo distal en la acidificación de la orina. A pesar de su rareza, se trata de una manifestación bien establecida del síndrome de Sjögren primario (SSp), que es un síndrome sistémico que involucra las glándulas salivares en un primer estadio. Describimos el caso de una paciente con ATRd en que el estudio etiológico confirmó el SSp. La corrección sérica de potasio se reveló muy problemática a pesar de la administración de suplementos y solo se mantuvo después de que se empezara tratamiento con espironolactona.

Palabras clave: Síndrome de Sjögren. Acidosis tubular renal. Hipopotasemia. Espironolactona.

INTRODUCTION

Primary Sjögren's Syndrome (pSS) is a systemic autoimmune disorder predominantly involving exocrine glands, namely salivary and lachrymal glands, leading to xerostomia and xerophthalmia, known as sicca syndrome. Extraglandular manifestations are less common and can affect virtually any organ; they can occur at

presentation or during the course of pSS, and if present can impact prognosis¹. Renal involvement is estimated to occur in up to 10% of patients¹, more frequently as tubulointerstitial nephritis (TIN) and rarely as glomerulonephritis. TIN is manifested as dRTA, nephrogenic diabetes insipidus, proximal tubular dysfunction, normally without renal failure^{2,3}. dRTA is the most frequent renal manifestation, it is incomplete when there is a urinary acidification defect with normal serum bicarbonate and pH, and complete when there is a urinary acidification defect, low serum bicarbonate and acidosis. Complete dRTA is less common, can occur acutely often associated with mild to severe hypokalemia and it is frequently a diagnostic and therapeutic challenge⁴.

CASE REPORT

The patient is a 56-year-old female with nasopharynx carcinoma diagnosed 5 years earlier, treated with chemoradiotherapy

Corresponding: Ana I. Ferreira

Department of Internal Medicine.

Centro Hospitalar Universitário de São João.

Alameda Prof. Hernani Monteiro, 4202-451 Porto, Portugal.

anaisabelferreira91@gmail.com

*The authors contributed equally to the paper.

Revisión por expertos bajo la responsabilidad de la Sociedad Española de Nefrología.

(cisplatin and 5-fluorouracil) and afterwards she was maintained under surveillance with no signs of tumor progression. There was no nephrotoxicity or significant electrolytic disturbances caused by cisplatin. She also had a history of corneal ulceration and xerophthalmia attributed to radiotherapy sequelae.

She presented to the emergency department with a 7-day history of progressive prostration, weakness and tetraparesia. She denied diarrhea and use of herbal or illicit drugs. On admission, patient's vital signs were normal, physical examination showed dry oral mucosa and tetraparesia with no other neurological signs. The EKG showed sinus rhythm, flattened T waves and presence of U waves. Arterial blood gas revealed normal anion gap metabolic acidosis (pH 7.37; anion gap 16 mEq/L), low bicarbonate (14 mEq/L) and severe hypokalemia (1.7 mEq/L) confirmed in venous analysis (1.9 mEq/L). Analytical studies showed normal creatinine, magnesium (2.39 mEq/L), phosphate (2.2 mEq/L) and unaltered thyroid function. Urine analysis revealed a high urinary pH (7.5) without proteinuria or glycosuria; urinary ions were not measured in the emergency department. Renal ultrasound ruled out nephrocalcinosis and nephrolithiasis. Supplementation with intravenous potassium chloride (KCl) was initiated with subsequent raise of potassium to 2.3 mEq/L and resolution of tetraparesia, and the patient was admitted in the ward.

Supplementation with high doses of intravenous KCl (50 to 100 mEq daily) was maintained without appropriate response, maintaining hypokalemia and low bicarbonate. Four days after admission, plasma potassium was 2.8 mEq/L, and supplementation with oral sodium bicarbonate (NaHCO_3) (1000 mg, every 8 hours) was initiated with sequent raise of plasma potassium. After 5 days of supplementation, serum potassium was normal (3.6 mEq/L) and bicarbonate increased slightly (19 mEq/L). At this stage, we suspended all supplementation aiming to collect 24-hour urine for analysis, which happened 4 days later when the plasma potassium and bicarbonate had started decreasing again. 24-hour urine analysis revealed creatinine clearance of 83 mL/min, high urine pH (7.5), positive urinary anion gap (41 mEq/L), inappropriately high urinary potassium (42 mEq/L) and normal calciuria (3.6 mEq/L). These results in addition to the pattern of plasma potassium, which only rose after supplementation with NaHCO_3 , led to the diagnosis of complete dRTA, and supplementation with NaHCO_3 and KCl was re-introduced. Despite that, moderate hypokalemia (2.7 mEq/L) remained and spironolactone (25 mg, once daily) was started with sequent normalization of plasma potassium, allowing patient to be discharged medicated with NaHCO_3 (1000 mg, thrice daily) and spironolactone (25 mg, once daily). The evolution of serum potassium and bicarbonate and its relation to supplementation can be analyzed in figure 1.

The etiological study showed antinuclear antibodies > 1/1000 speckled pattern, positive anti-Sjögren's-syndrome-related antigen A and antigen B autoantibodies; salivary gland scintigraphy showed chronic sialadenitis. Hence, diagnosis of pSS with TIN was established.

DISCUSSION AND CONCLUSION

We presented the case of a patient with hypokalemic paralysis which initial assessment showed metabolic acidosis with normal anion gap. At this stage the primary goal was potassium intravenous supplementation which was started before measurement of urinary ions and anion gap. Despite supplementation, there was not an adequate response of plasma potassium and normal anion gap metabolic acidosis remained which lead to the suspicion of renal tubular acidosis (RTA).

Although acid-loading and challenge infusions with NaHCO_3 tests are used to diagnose RTA, diagnosis can be achieved by serial analysis of blood and urine² and analyzing the variation pattern of plasma potassium and bicarbonate with supplementation. However, with supplementation the analysis of urinary ions could not be correctly assessed, and so we aimed to correct hypokalemia to allow safe suspension of supplementation before collecting 24-hour urine.

Very low levels of plasma bicarbonate, high urinary pH and severe hypokalemia are features of dRTA, however, urine ammonium values or urine anion gap are necessary to conclude the diagnosis. Most laboratories cannot measure urinary ammonium, therefore estimations can be made from urinary anion gap or osmolar gap. Positive urinary anion gap suggests reduced urine ammonium excretion, reflecting a primary defect in distal urine acidification which characterizes dRTA. Renal biopsy is not mandatory², and since our patient had normal renal function, it was not performed.

Management of dRTA is essentially supportive, including potassium and bicarbonate supplementation and nephro-urological follow-up to prevent complications from nephrolithiasis³. Early diagnosis and life-long alkali supplementation can prevent both acute hypokalemia and chronic complications like osteomalacia, renal stones and progression to chronic kidney disease⁴.

Cisplatin-induced nephrotoxicity is a fairly common complication, which most commonly manifests as acute or chronic impairment of kidney function with or without electrolyte disturbances. Cases of cisplatin-related dRTA have also been described, although this is a much rarer form of toxicity. Our patient had been treated with cisplatin 5 years before the diagnosis of dRTA, and during chemoradiotherapy there were no significant changes in serum creatinine and electrolytes. While cisplatin-induced nephrotoxicity is fairly common, this predominantly happens during treatment with cisplatin and not years after the treatment, and thus it was considered to be an unlikely cause of dRTA in our patient⁵.

In our case, correcting plasma potassium proved difficult despite supplementation. Normal values were only achieved with spironolactone. This allowed patient discharge medicated only with NaHCO_3 and spironolactone. Oguejiofor et al.⁶ successfully used amiloride with the same purpose.

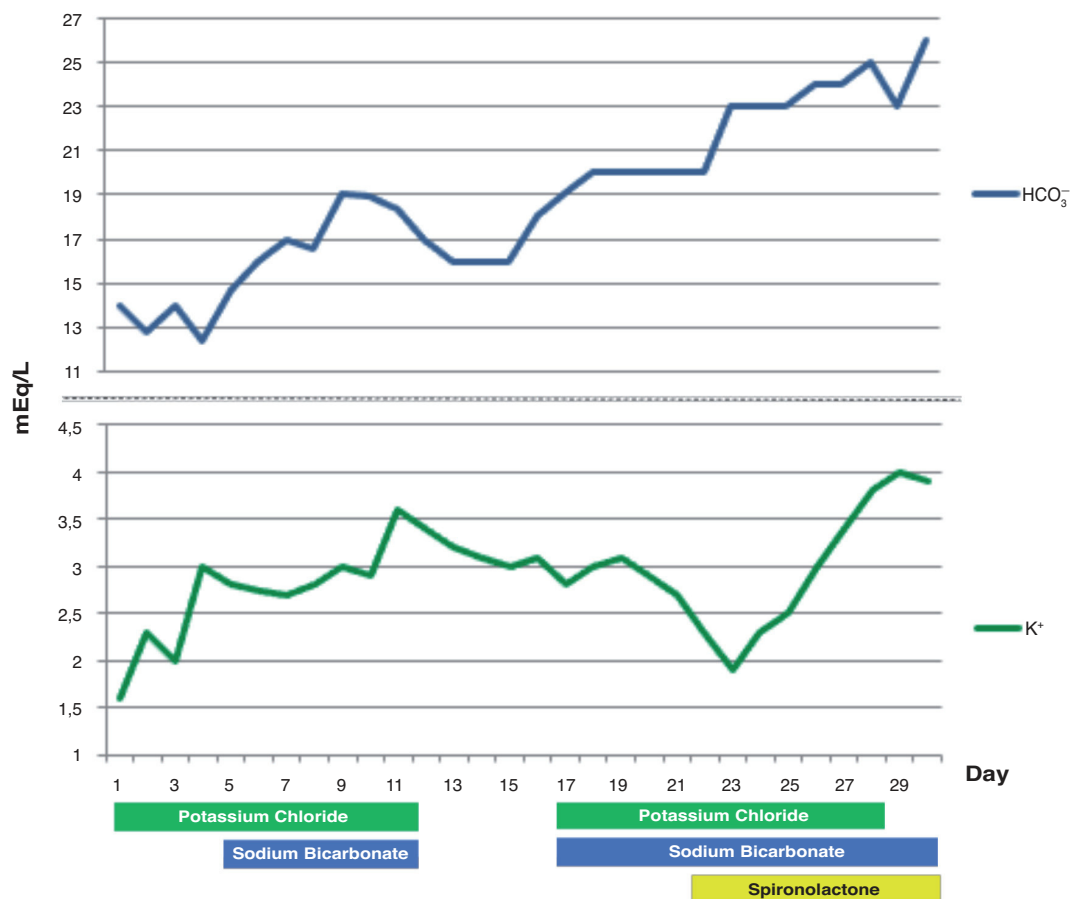


Figure 1. Evolution of serum potassium (K⁺) and bicarbonate (HCO₃⁻) and its variation with supplementation.

In this case we excluded hypokalemic periodic paralysis (HPP), as a differential diagnosis, which is characterized by episodes of painless muscle weakness or even paralysis that can be associated with heavy exercise, fasting, high-carbohydrate meals or even occur without any precipitant, beginning at early 20s. She has had no such symptoms, neither does she had a past history of paralysis or familial history. Hypokalemic familial periodic paralysis typically presents in the first 2 decades of life, with attacks typically lasting several hours⁷. Moreover, thyrotoxic hypokalemic periodic paralysis, which behaves similar to HPP with an onset of age around 20 to 50, was also excluded because the patient had normal T4 and TSH values. In these diseases, potassium and phosphate levels are low, but hypophosphatemia was not present in our patient; both present with normal acid-base status not corresponding as well to her presentation and both have low urinary potassium excretion (normally < 20 mEq/l)⁷.

The diagnosis of pSS was misled, despite the presence of sicca syndrome, given that symptoms were attributed to radiotherapy sequelae and it was needed a high degree of suspicion to include it as a differential diagnosis.

Pathophysiologic mechanisms by which pSS leads to dRTA are not completely understood. The absence of H⁺-ATPase pumps in the intercalated cells of the collecting tubules has been documented, which can cause inability to acidify urine⁶. Despite being an extraglandular manifestation, dRTA is not an indication for immunomodulatory therapy in pSS. However, steroid therapy can be considered when replacement therapy alone is unable to correct unbalances, and in cases of recurring hypokalemic paralysis episodes².

This case highlights the difficulties in diagnosing complete dRTA, since patients invariably have severe ionic and acid-base disturbances under supplementation when diagnosis is suspected, therefore urine analysis cannot be correctly assessed. It also emphasizes the challenge of treating dRTA and the possible role of diuretic sparing agents in managing refractory hypokalemia.

Disclosure statement

The authors declare they have no conflicts of interest.

REFERENCES

1. Mariette X, Criswell LA. Primary Sjögren's Syndrome. *N Engl J Med*. 2018;378:931-9.
2. Garza-Alpirez A, Arana-Guajardo AC, Esquivel-Valerio JA, Villarreal-Alarcón MA, Galarza-Delgado DA. Hypokalemic paralysis due to primary Sjögren syndrome: Case report and review of the literature. *Case Rep Rheumatol*. 2017;2017:1-7.
3. Evans R, Zdebik A, Ciurtin C, Walsh SB. Renal involvement in primary Sjögren's syndrome. *Rheumatology (Oxford)*. 2015;54(9):1541-1548.
4. Both T, Hoorn EJ, Zietse R, van Laar JA, Dalm VA, Brkic Z, et al. Prevalence of distal renal tubular acidosis in primary Sjögren's syndrome. *Rheumatology (Oxford)*. 2015;54:933-9.
5. Manohar S, Leung N. Cisplatin nephrotoxicity: A review of the literature. *J Nephrol*. 2018;31:15-25.
6. Oguejiofor P, Chow R, Yim K, Jaar BG. Successful management of refractory type 1 renal tubular acidosis with amiloride. *Case Reports Nephrol Print*. 2017;2017:8596169.
7. Rhee EP, Scott JA, Dighe AS. Case 4-2012: A 37-year-old man with muscle pain, weakness, and weight loss. *N Engl J Med*. 2012;366:553-60.