

# Hypocomplementemic urticarial vasculitis with polyadenopathies and renal involvement

Luis C. López-Romero<sup>1</sup>, Fabrizzio H. Poma-Saavedra<sup>1</sup>, Nayara Panizo-González<sup>1</sup>, Judith Pérez-Rojas<sup>2</sup>, José L. Moll-Guillem<sup>1</sup>, Sergio Bea-Granell<sup>1</sup>, María Peris-Fernández<sup>1</sup>, Paula Aledon-Viñes<sup>1</sup>, Julio Hernández-Jaras<sup>1</sup>

<sup>1</sup> Clinical Nephrology. Hospital Universitario y Politécnico La Fe. Valencia

<sup>2</sup> Anatomic Pathology. Hospital Universitario y Politécnico La Fe. Valencia

NefroPlus 2019;11(1):88-93

© 2019 Sociedad Española de Nefrología. Servicios de edición de Elsevier España S.L.U.

## ABSTRACT

Urticarial vasculitis (UV) is considered a clinicopathologic entity consisting of clinical manifestations of urticaria and histopathological evidence of cutaneous small vessels leukocytoclastic vasculitis. Based on complement levels and presence or absence of specific systemic findings, there are 2 distinct diagnostic entities: hypocomplementemic urticarial vasculitis syndrome and hypocomplementemic urticarial vasculitis. We present a 52-year-old man admitted to our hospital for general weakness with arthralgia in both hands, without arthritis signs and purpuric skin injuries in both legs. Two years before, he had been diagnosed with recurrent urticaria and treated with antihistaminics. Laboratory exams showed dysmorphic hematies in urinalysis, hypocomplementemia, proteinuria in the nephrotic range and polyadenopathies. Kidney biopsy was made showing as result a membranoproliferative glomerulonephritis.

**Keywords:** Urticarial vasculitis. Membranoproliferative glomerulonephritis. Polyadenopathies.

## INTRODUCTION

Urticarial vasculitis (UV) is considered a clinicopathologic entity consisting of clinical manifestations of urticaria and histopathological evidence of cutaneous leukocytoclastic vasculitis (LCV) of the small vessels.<sup>1,2</sup>

Based upon complement levels and presence or absence of specific systemic findings, there are 2 distinct diagnostic entities: hypocomplementemic UV syndrome (HUVS) and hypocomplementemic UV (HUV).<sup>3,4</sup> In general, patients with HUV have cutaneous disease and few or no systemic manifestations.

HUVS has been recognized as a specific autoimmune disorder involving 6 or more months of urticaria with low complement levels and systemic findings that may include arthritis or arthral-

gia, glomerulonephritis, uveitis or episcleritis and recurrent abdominal pain (Table 1). A skin biopsy showing small vessel vasculitis is essential for diagnosis. Low levels of C1q are frequently associated with HUVS, nevertheless, this finding is not specific since decreased C1q levels are also found in patients with systemic lupus erythematosus.<sup>5,6</sup>

We report the case of a patient with recurrent urticaria who developed a decline on kidney function with positive ANCA, hypocomplementemia and renal deposition of immune complexes.

## CASE REPORT

A 52-year-old man was admitted to our hospital for general weakness, arthralgia in both hands, without arthritis signs and purpuric skin injuries in both legs. Symptoms presented one month after umbilical hernia surgery. The patient presented intermittent episodes of macroscopic hematuria. Patient denied nephrotoxic drug consumption as well as respiratory or gastrointestinal symptoms. Two years before, he had been diagnosed with recurrent urticaria and treated with antihistaminics. The patient had also been treated for skin melanoma in the back. In control tomography studies he recurrently presented inespecific polyadenopathy. Repeated biopsies of

**Corresponding:** Luis Carlos López Romero

Department of Clinical Nephrology.

Hospital Universitario y Politécnico La Fe.

Avda. de Fernando Abril Martorell, 106. 46026, Valencia

luiscarloslopezromero@gmail.com

*Revisión por expertos bajo la responsabilidad de la Sociedad Española de Nefrología.*

**Table 1. Diagnostic criteria of hypocomplementemic urticarial vasculitis syndrome**

Criteria	Specifics
<b>Major criteria</b>	Urticaria for more than 6 months
	Hypocomplementemia
<b>Minor criteria</b>	Venulitis of the dermis (established via biopsy)
	Arthralgia or arthritis
	Mild glomerulonephritis
	Uveitis or episcleritis
	Recurrent abdominal pain
	Positive C1q precipitin test by immunodiffusion with an associated suppressed C1q level

The patient must have both major criteria and at least 2 of the minor criteria.

different adenopathies had been carried out with negative results for malignancy.

Physical examination: blood pressure: 130/90 mmHg; urine output with more than 100 mL per hour, urticarial lesions in both legs. Cardiopulmonary auscultation was normal.

Laboratory data on admission: red blood cells of  $3,79 \times 10^{12}/L$ ; hemoglobin, 9,3 g/dL and platelets of  $390 \times 10^9/L$ . Serum chemistry: creatinine (Cr): 2.2 mg/dL; estimated glomerular filtration rate (eGFR): 31.78 mL/min/1.73 m<sup>2</sup>; urea: 68 mg/dL, and C-reactive protein: 46 mg/L, VSG: 73 mm/h.

Urinalysis showed more than 250 red blood cells, dysmorphic hematies and epithelial casts.

C3: 34 mg/dL (normal range, 90-180 mg/dL), C4: 3 mg/dL (normal range, 10-40 mg/dL) and C1q: 6 mg/dl (normal range, 10-25 mg/dL). MPO-ANCA: 128,0 UI/mL (positive: >5 UI/mL), antistreptolysin O: 354 UI/ml (normal range, 0-200 UI/ml), IgM: 39 mg/dL (normal range, 40-230 mg/dL), IgG: 1803 mg/dL (normal range, 700-1600 mg/dL), antinuclear antibody, anti-Smith antibody, anti-SS-B, anti-glomerular basement membrane antibody, crioglobulins and PR3-ANCA were negative.

Hepatitis B, and hepatitis C were also negative.

24-hour urine protein excretion: 4.85 g/day.

An abdominal ultrasound showed a normal kidney size with hypoechoic parenchyma surrounding the echogenic renal sinus.

Computerized tomography (TAC): supra and infraclavicular polyadenopathic syndrome, multiple bilateral cervical adenopa-

thies. No pulmonary nodules were observed. Hepatic and splenic parenchymas were normal. Repeated biopsies of different adenopathies had been practiced with negative results for malignancy.

Skin biopsy: leukocytoclastic vasculitis.

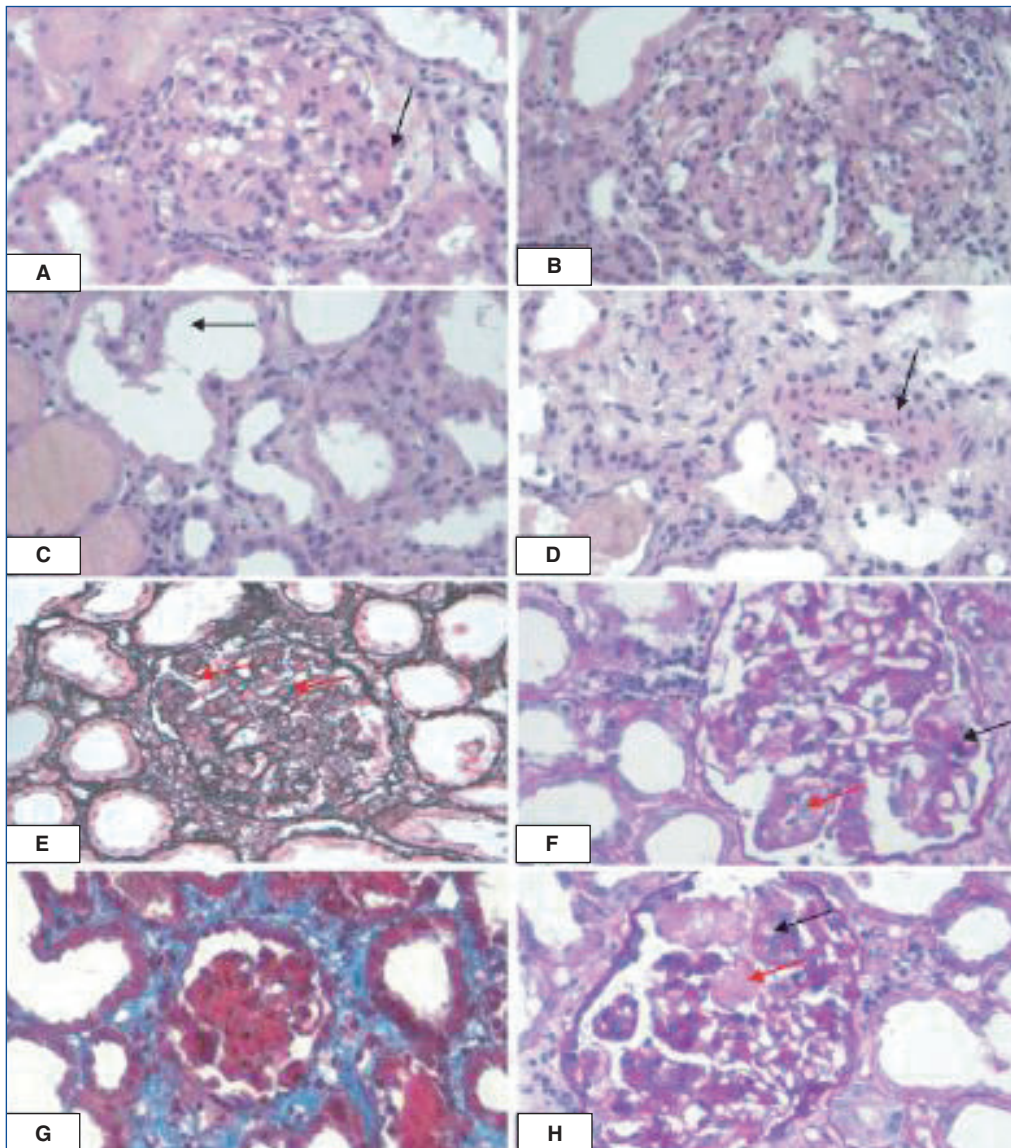
Kidney biopsy: 14 glomeruli, none with global sclerosis.

Glomerular compartment: diffuse mesangial expansion with mild mesangial hypercellularity. The capillary membranes are linear and show focal thickening. A double contour image is appreciated. No spikes or spicules are observed. Focal and segmental endocapillary proliferation. No extracapillary proliferation.

Tubulo-interstitial and vascular compartment: no interstitial fibrosis. Arteritis (endothelitis or transmural inflammation) is absent. There is no arteriolar hyalinosis neither intravascular thrombi. Absence of microaneurysms (Fig. 1).

Immunofluorescence: diffuse and global mesangial-capillary deposit of C3 ++, IgM +, IgG +; C1q (+); IgA (-) (Fig. 2). The location of electron-dense deposits (immune) is subendothelial, subepithelial and mesangial. Subendothelial and mesangial electron dense deposits, increased mesangial matrix, mesangialization of capillary loops and foot process fusion (Fig. 3).

With these results, our patient received steroid pulse therapy with methylprednisolone at a dose of 500 mg for 3 days followed by oral prednisone at a dose of 1 mg/kg/day. Once steroid therapy was started, urticarial lesions disappeared and general condition improved. MPO-ANCA became negative and C3 and C4 increased to normal range after 6 weeks of therapy. Kidney function and proteinuria also improved.



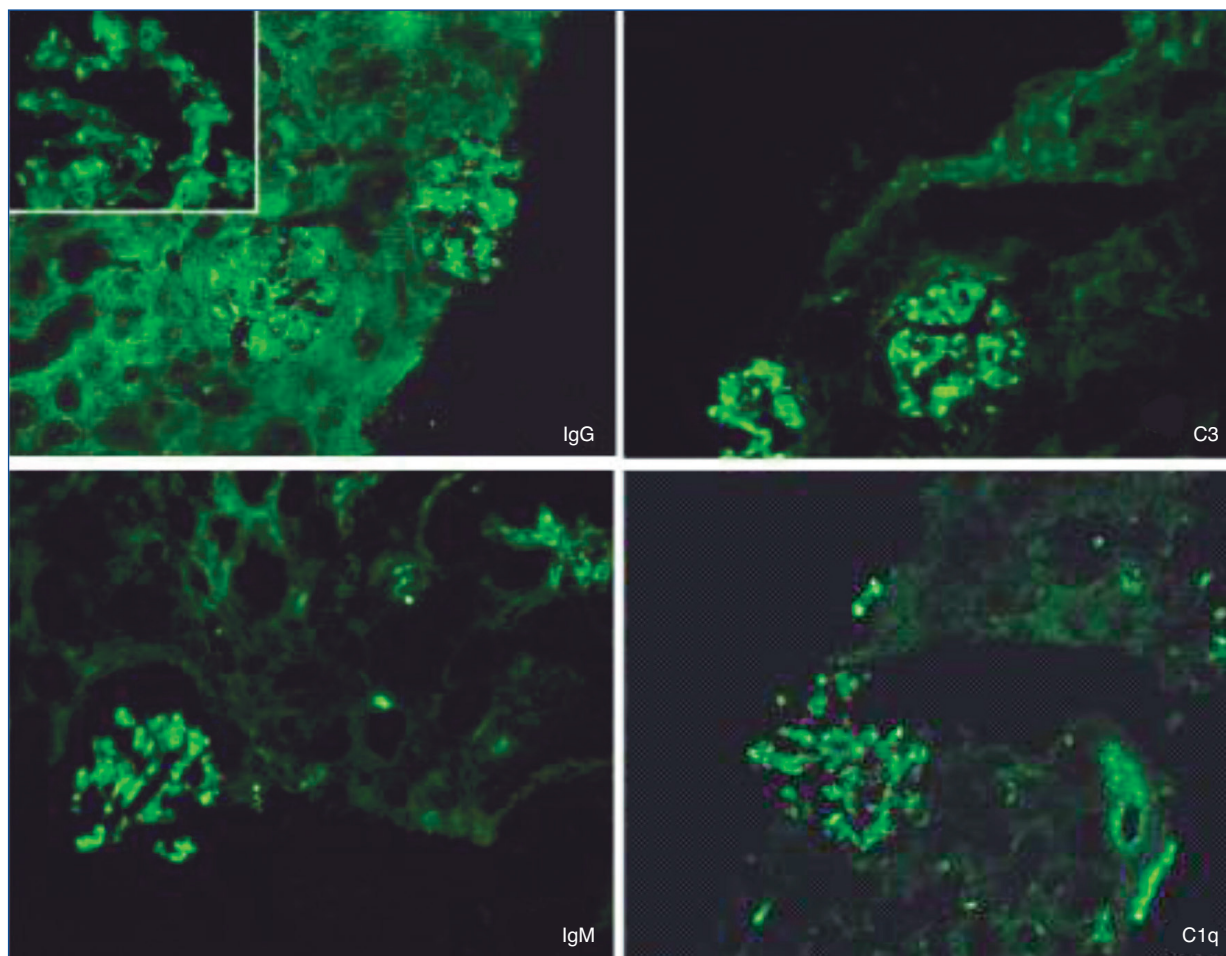
**Figure 1. Glomerulus increased of size, with diffuse mesangial expansion and lobulated aspect; this appearance is very characteristic of membranoproliferative GN (H&E, ×400).**

A and B) There are tuft lobulation and mesangial hypercellularity, more accentuated in some areas (arrows). Large glomeruli with accentuation of lobule endocapillary proliferation focal and segmental. Neutrophils often present. C and D) There is tubular epithelial damage cellular desquamation, brush border loss, and tubular dilatation. There is not intimal fibrosis of arteries, inflammation and hyaline arteriolar deposits. E) Irregular thickening of glomerular basement membrane by interposition of mesangial cells between endothelium and basement membrane. The capillary membranes are linear and show focal thickening. A double contour appearance (silver stain ×400). F and H) May have hyaline aggregates of immune complexes in capillary lumina. There is capillary lumen diminution (PAS, ×400). G) Gomori's trichrome, ×400 with area with fibrinoid necrosis of the wall, polymorphous and cellular detritus.

## DISCUSSION AND CONCLUSION

Diagnostic criteria of urticarial vasculitis hypocomplementemic syndrome were proposed by Schwartz et al in 1982 (see Table 1). Our patient presents all criteria except recurrent ab-

dominal pain. It is necessary to have excluded any secondary form. The renal injury is most often benign and consists of proteinuria and hematuria.<sup>7</sup> The histopathological manifestation is mainly membranoproliferative or mesangial glomerulonephritis.



**Figure 2. Irregularly granular capillary loop and mesangial staining. Lumpy bumpy (granular) for C3 (++) , IgG (++) , IgM (++) and complement C1q (+). Pattern is mesangial and subendothelial. C3 with mesangial ring on IF.**

Renal involvement affects between 20% to 50% of patients.<sup>8</sup> One of the hypotheses of the pathogenesis of HUVS is the consumption of C1q by a circulating antibody, this could trigger an activation of the classic pathway of complement and be associated with membranoproliferative glomerulonephritis.<sup>9</sup>

To our knowledge, the association of HUVS and AAV has been reported, but in our case a false positive it's the main option since it does not meet criteria for entities that include AAV.<sup>10</sup> Nevertheless, there is no evidence that shows if the elevation of ANCA is related to HUVS. Polyadenopathy has been rarely described in some publications and secondary cause must be the first option. Lymph node biopsy should always be practiced to search for an underlying hematological cause; at our case, the absence of histological criteria has made it possible to assert the reactive character of its adenopathies to hypocomplementemic vasculitis.<sup>11</sup> The presence of angioedema at the diagnosis is found in less than 5% of cases.<sup>12</sup>

There is no consensus on the appropriate treatment of HUVS. Corticosteroid therapy is reportedly effective in many cases of

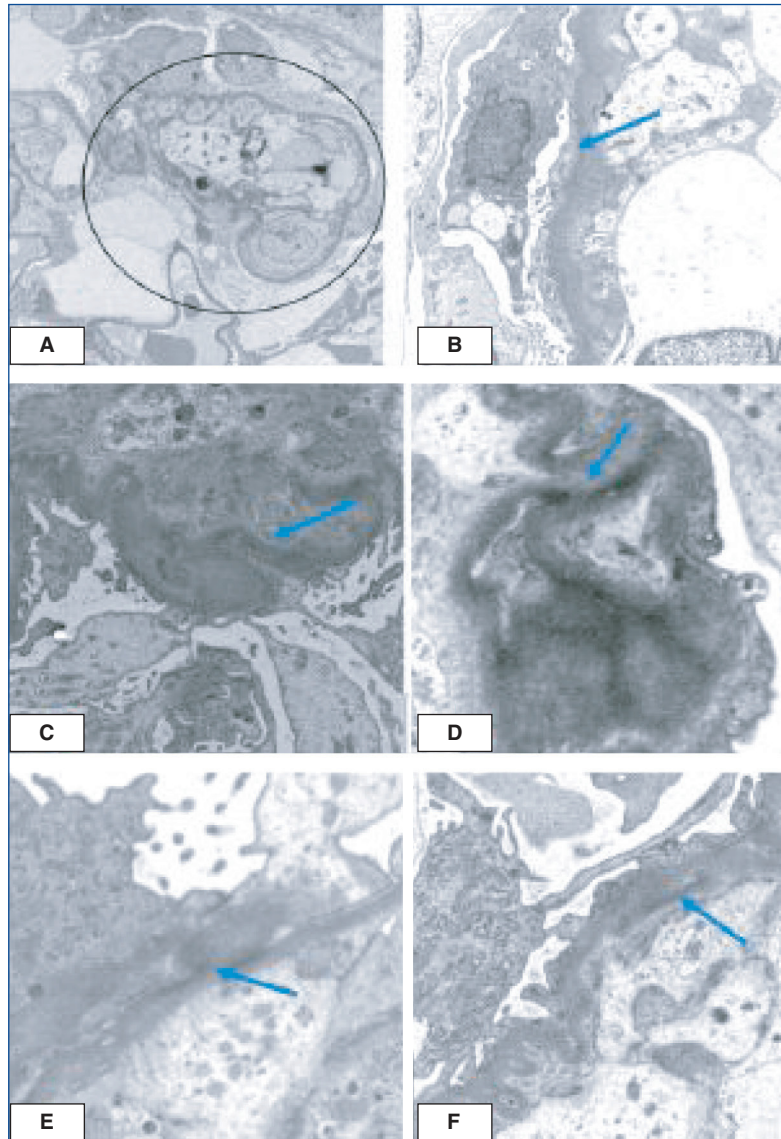
HUVS. In several cases in adults have progressed to end-stage renal disease, for this reason other immunosuppressive agents, especially cyclophosphamide, is necessary for some serious or recurrent cases.<sup>13,14</sup>

In contrast, complete remission was achieved by steroid monotherapy in the present case. The favorable outcome in our case might be explained by the early initiation of treatment at the acute stage of the disease.

In conclusion, we describe a rare case of idiopathic HUV with polyadenopathies and renal involvement. The evolution has been favorable under corticosteroids. HUV is a rare disease, and the further accumulation of cases is necessary to understand the pathogenesis and best treatment options for this entity.

#### Disclosure statement

The authors have no conflicts of interest to declare.



**Figure 3.** A-F). The location of electron-dense deposits (immune): subendothelial, subepithelial deposits and mesangial interposition associated with basement membrane. Subendothelial and mesangial electron dense deposits, increased mesangial matrix, mesangialization of capillary loops and foot process fusion. B) Diffuse thinning of glomerular basement membranes. The blue arrow indicates an area of the podocyte fusion. EM, original magnification,  $\times 8000$  Splitting and reduplication of basement membrane. C) Large subendothelial electron dense deposit along glomerular basement membrane. D) Mesangial electron-dense deposits EM, original magnification,  $\times 6000$ . F) Subendothelial deposits in membranoproliferative GN indicated with the blue arrow. Notice also a capillary segment with double contour. EM original magnification,  $\times 6000$ .

## REFERENCES

1. McDuffie FC, Sams WM Jr, Maldonado JE, Andreini PH, Conn DL, Samayoa EA. Hypocomplementemia with cutaneous vasculitis and arthritis. Possible immune complex syndrome. *Mayo Clin Proc.* 1973;48:340-8.
2. Huston DP, Bressler RB. Urticaria and angioedema. *Med Clin North Am.* 1992;76:805-40.
3. Zeiss CR, Burch FX, Marder RJ, Furey NL, Schmid FR, Gewurz H. A hypocomplementemic vasculitic urticarial syndrome. Report of four new cases and definition of the disease. *Am J Med.* 1980;68: 867-75.
4. Chen HJ, Bloch KJ. Hypocomplementemic urticarial vasculitis, jacquod's arthropathy, valvular heart disease, and reversible tracheal stenosis: a surfeit of syndromes. *J Rheumatol.* 2001;28:383-6.
5. Davis MD, Brewer JD. Urticarial vasculitis and hypocomplementemic urticarial vasculitis syndrome. *Immunol Allergy Clin North Am.* 2004;24:183-213.

6. Wisnieski JJ. Urticarial vasculitis. *Curr Opin Rheumatol*. 2000;12:24-31.
7. Schwartz HR, McDuffie FC, Black LF, Schroeter AL, Conn DL. Hypocomplementemic urticarial vasculitis: association with chronic obstructive pulmonary disease. *Mayo Clin Proc*. 1982;57:231-8.
8. Jachiet M, Flageul B, Deroux A, Le Quellec A, Maurier F, Cordoliani F, et al; French Vasculitis Study Group. The clinical spectrum and therapeutic management of hypocomplementemic urticarial vasculitis: data from a French nationwide study of fifty-seven patients. *Arthritis Rheumatol*. 2015;67:527-34.
9. Wisnieski JJ, Jones SM. IgG autoantibody to the collagen-like region of C1q in hypocomplementemic urticarial vasculitis syndrome, systemic lupus erythematosus, and 6 other musculoskeletal or rheumatic diseases. *J Rheumatol*. 1992;19:884-8.
10. Tanaka M, Moniwa N, Mita T, Tobisawa T, Matsumoto T, Mochizuki A, et al. A Case of Crescentic Glomerulonephritis Complicated with Hypocomplementemic Urticarial Vasculitis Syndrome and ANCA-Associated Vasculitis. *Case Rep Nephrol Dial*. 2017;7:144-53.
11. Sheffer AL, Austen KF, Rosen FS, Fearon DT. Acquired deficiency of the inhibitor of the first component of complement: Report of five additional cases with commentary on the syndrome. *J Allergy Clin Immunol*. 1985;75:640-6.
12. Wisnieski JJ, Baer AN, Christensen J, Cupps TR, Flagg DN, Jones JV, et al. Hypocomplementemic urticarial vasculitis syndrome. Clinical and serologic findings in 18 patients. *Medicine (Baltimore)*. 1995;74:24-41.
13. Jara LJ, Navarro C, Medina G, Vera-Lastra O, Saavedra MA. Hypocomplementemic urticarial vasculitis syndrome. *Curr Rheumatol Rep*. 2009;11:410-5.
14. Sanchez NP, Winkelmann RK, Schroeter AL, Dicken CH. The clinical and histopathologic spectrums of urticarial vasculitis: study of forty cases. *Am Acad Dermatol*. 1982;7:599;-605.