

Genome Biol. 2005;6:209,  
<http://dx.doi.org/10.1186/gb-2005-6-2-209>.

Francisco Valga<sup>a,b,\*</sup>, Tania Monzón<sup>c</sup>, Marian Rincón<sup>a</sup>,  
 Nicanor Vega-Díaz<sup>a,b</sup>, Jose Carlos de la Flor<sup>d</sup>,  
 Sara Aladro-Escribano<sup>a</sup>, Adonay Santana-Quintana<sup>a</sup>,  
 Raquel Santana-Estupiñan<sup>a</sup>, José Carlos Rodríguez-Pérez<sup>a,b</sup>

<sup>a</sup> Nephrology Department, Doctor Negrín University Hospital of  
 Gran Canaria, Las Palmas de Gran Canaria, Las Palmas, Spain

<sup>b</sup> Doctoral Programme in Biomedical Research, Health Sciences  
 Faculty, Clinical Sciences Department, University of Las Palmas de  
 Gran Canaria, Las Palmas de Gran Canaria, Las Palmas, Spain

<sup>c</sup> Avericum Negrín Haemodialysis Centre, Las Palmas de Gran  
 Canaria, Las Palmas, Spain

<sup>d</sup> Nephrology Department, Gómez Ulla Central Military Hospital,  
 Madrid, Spain

\* Corresponding author.

E-mail address: [fvalga@hotmail.com](mailto:fvalga@hotmail.com) (F. Valga).

<https://doi.org/10.1016/j.nefro.2022.09.001>  
 2013-2514/© 2021 Sociedad Española de Nefrología. Published  
 by Elsevier España, S.L.U. This is an open access article  
 under the CC BY-NC-ND license (<http://creativecommons.org/licenses/by-nc-nd/4.0/>).

## Acute kidney injury following naphthalene poisoning in children

### Lesión renal aguda después de la intoxicación por naftalina en niños

Dear Editor:

Acute poisoning in children is a frequent cause of admission to emergency units and can lead to death and acute kidney injury (AKI). The incidence of poisoning in children varies from 0.33% to 7.6%.<sup>1</sup> Naphthalene poisoning can lead to a severe clinical

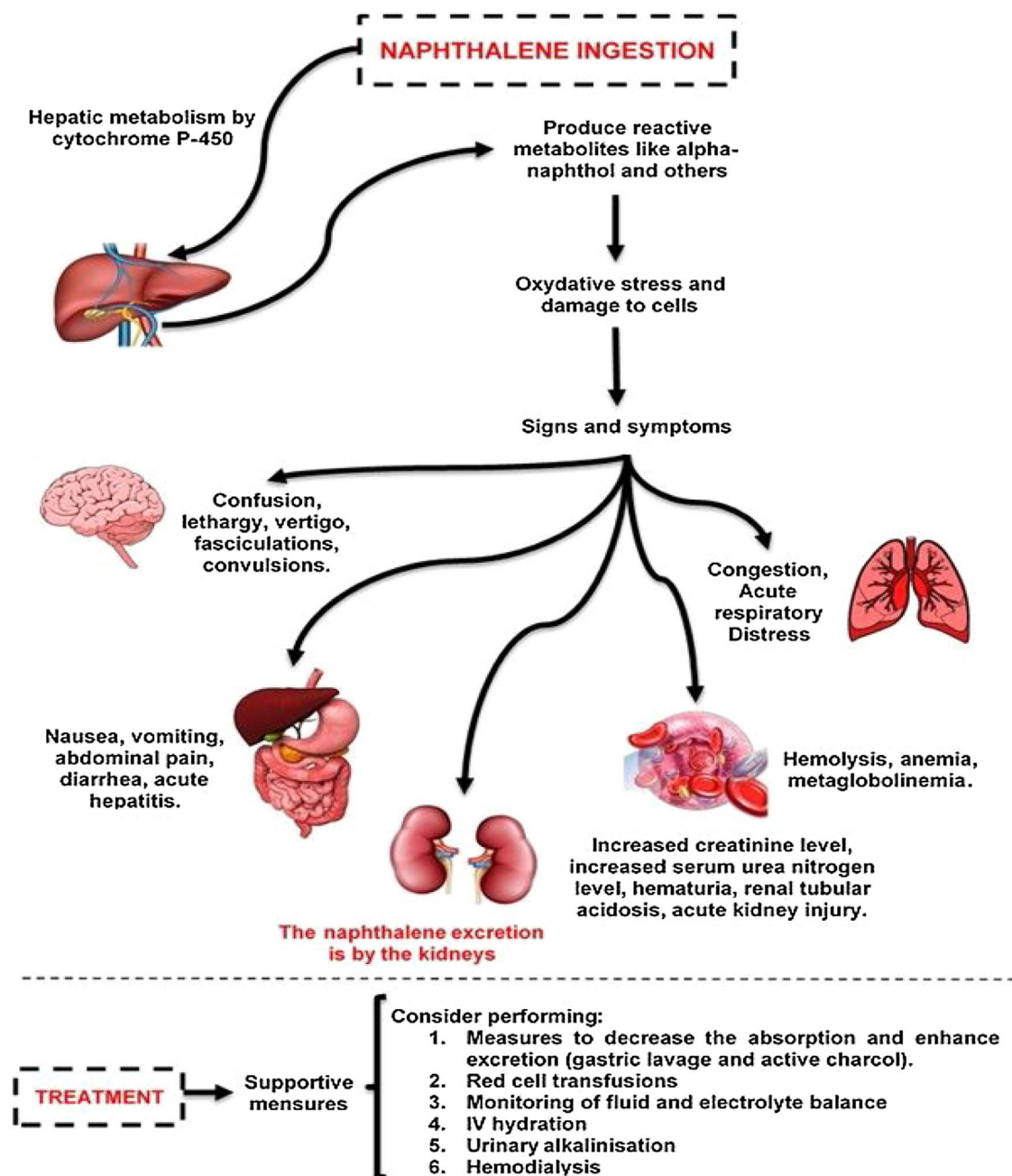
Picture.<sup>2</sup> AKI due to naphthalene poisoning is very uncommonly reported in the literature, especially if it requires renal replacement therapy. Acute intravascular hemolysis may be the major mechanism of AKI in naphthalene poisoning.<sup>3,4</sup> In this study, we described a rare case of AKI following naphthalene poisoning in a pediatric patient successfully treated.

**Table 1 – Laboratory findings on admission and during the follow-up of the patient.**

Parameters	Admission	9 h	24 h	3rd Day	5th Day	10th Day	12th Day	13th Day	Discharge
Potassium	4.09	4.04	4.53	4.23	3.33	5.39	6.93	5.63	3.83
Sodium	135	136	130	137	139	137	135	136	134
Urea	45	62	55	80	51	67	79	65	69
Creatinine	0.7	1.4	1.4	2.1	1.9	2.2	2.6	1.7	1.2
eGFR	51	25.5	0	0	0	16.2	21	32.4	30
AST	75	1281	738	64	**	**	**	**	23
ALT	22	687	569	139	**	**	**	**	10
DB	0.23	**	2.87	1.31	0.33	**	**	**	**
IB	0.34	**	3.14	1.23	1.02	**	**	**	**
PT	12.1	12.2	13.8	11.6	11.2	12	**	12.5	**
aPTT	26.7	25.9	32	27.5	23.8	31.3	**	31.7	**
D-LDH	**	3205	**	972	**	**	**	**	**
Hemoglobin	13	11.1	10.1	8.5	7.8	7.4	8.1	9.5	10.1
Leukocytes	12,420	7940	8020	15,820	11,170	10,230	**	11,000	7530
Platelets	479,000	281,000	209,000	188,000	139,000	323,000	**	403,000	367,000
PH***	**	7.38	**	**	**	**	**	**	**
pCO2***	**	30.5	**	**	**	**	**	**	**
HCO3***	**	19.5	**	**	**	**	**	**	**

AST: Aspartate aminotransferase; ALT: Alanine aminotransferase; D-LDH: D-lactate dehydrogenase; CK: Creatine phosphokinase; PT: Prothrombin time; aPTT: partial time of thromboplastin; DB: direct bilirubin; IB: Indirect bilirubin; eGFR: estimated Glomerular Filtration Rate. \*\* Not available. \*\*\*Arterial Gasometry.

Reference values: Potassium (3.5–5.5 mmol/L); Sodium (135–145 mmol/L); Chloride (96–109 mmol/L); Glucose (74–106 mg/dL); Urea (13–43 mmol/L); Creatinine (0.6–1.1 mmol/L); AST (<32 mg/dL); ALT (< 31 mg/dL); DB (< 1 UI/L); DI (< 1 UI/L); PT (10–14 s); aPTT (22–28 s); D-LDH (230–460 UI/L); Albumin (>3.5 UI/L); Hemoglobin 11.3/15.2 g/dL; leukocytes (3600–10,000/mm<sup>3</sup>); platelets (150,000–450,000/mm<sup>3</sup>); PH (7.35–7.45); pCO2 (35/45 mmHg); pO2 (85–100 mmHg); HCO3 (22/26 mmol/L); BE (–4/+4).



**Fig. 1 – Physiopathology and systemic effects following human naphthalene exposure.**

Naphthalene is metabolized in the liver and is oxidized to alpha-naphthol and other metabolites. The cytochrome P450 enzymes are capable of catalyzing these metabolic transformation reactions. Toxic manifestations are mainly due to production of oxygen free radicals leading to lipid peroxidation and deoxyribonucleic acid (DNA) damage, as well as produce oxidative stress. This poisoning could affect various body systems, such as the liver, skin, lungs, kidney, central and peripheral nervous system. The treatment in these cases are mainly supportive.

A 1-year-old girl was admitted to the emergency department after accidental consumption of naphthalene balls. The time elapsed until emergency admission was five hours from the ingestion. The patient presented with severe abdominal pain, emesis, serious general condition, and a decreased consciousness level.

In the emergency unit, gastric lavage and activated charcoal were administered. Moreover, she received pri-

mary medical care and vigorous intravenous hydration. Results of initial laboratory tests were in the normal range (Table 1), and initial estimated glomerular filtration rate (eGFR) was 51 mL/min/1.73 m<sup>2</sup>. Nine hours later, the patient had acute respiratory failure, requiring intubation and ventilatory support. The patient had a left hemorrhagic pleural effusion and severe and acute anemia. Transfusion therapy (1 unit of packed red blood cells) was required

and a thoracic surgeon performed chest drainage due to hemothorax.

Schistocytes on peripheral smear were demonstrated. Moreover, the increase in indirect bilirubin and D-LDH (D-lactate dehydrogenase) suggested an intravascular hemolysis in progress (Table 1). G6PD levels remained in the normal range. She developed laboratory worsening with abnormal renal markers, suggesting oliguric AKI in progress according KDIGO's criteria (eGFR = 14 mL/min/1.73 m<sup>2</sup>). The increase in markers in the liver test indicated acute liver damage.

Moreover, she developed signs of hypervolemia and the nephrologist's assistance was requested, who prescribed hemodialysis. Intravenous sodium bicarbonate was used to prevent renal tubular damage due to hemolysis. The patient had hypertension and medications were started. On the 5th day, she began to recover and was successfully extubated. The patient's urine output improved after eleven hemodialysis sessions, and after 20 days, she was discharged as clinically stable. However, she continued with high blood pressure and only partial recovery of her kidney functions was observed (eGFR = 30 mL/min/1.73 m<sup>2</sup>).

Naphthalene poisoning is a relevant health issue due to the easy availability of this toxic agent, especially in low- and middle-income countries. Small doses of naphthalene in humans can affect various body systems – Fig. 1.<sup>5</sup> The patient reported here was a female child presenting with compromised serious general condition, emesis, and abdominal pain due to naphthalene poisoning within a period of 5 h from sucking a naphthalene ball. In this patient, the diagnosis of severe acute hepatitis was established from the clinical status, and the liver damage (observed in laboratory tests) should be attributed to naphthalene poisoning.<sup>6</sup>

Hemolysis is very often a consequence of naphthalene poisoning, and it can be worsened by G6PD deficiency. In this case, the diagnosis was suggested by schistocytes on peripheral smear, a high D-LDH level, and increased indirect bilirubin. In addition, G6PD deficiency was absent.

Naphthalene excretion occurs through the kidneys.<sup>5</sup> The major pathophysiologic mechanism of AKI is related to intravascular hemolysis and hemoglobinuria.<sup>4</sup> Despite the mild hemolytic anemia, the patient had severe AKI and required renal replacement therapy. This fact suggests other mechanisms for AKI development, such as direct nephrotoxicity and acute ischemic tubular necrosis.

There is no specific antidote for naphthalene toxicity and management guidelines are unclear.<sup>7</sup> Management is symptomatic with monitoring of fluid and electrolyte balance. Urinary alkalinization has been recommended in the case of hemoglobinuria to prevent it from being deposited in renal tubules.<sup>4</sup> The treatment in this case was mainly supportive with mechanical ventilation and blood pressure support with the use of inotropes. Nonetheless, gastric lavage and active charcoal were used to decrease absorption due to the severity of the case.

Hemodialysis is established as an important tool in some life-threatening poisoning cases.<sup>8</sup> Hemodialysis was utilized in this case due to the worsening of renal function, oliguria, hyperkalemia, metabolic acidosis, and hypervolemia. Hemodialysis added to the clinical measures promoted the clinical improvement.

Prognosis of naphthalene poisoning is multifactorial.<sup>9</sup> In the case reported, the patient had a remarkable improvement and was discharged on the 20th day. However, she continued to show elevated blood pressure.

Accurate examination of the AKI and CKD relationship has important clinical and public health implications. Complex and imperfect processes could follow AKI, subsequently limiting the repair of damaged cells and the return of their normal functioning. This mechanism appears to be one of the responsible factors for the elevated blood pressure and partial recovery of her kidney functions after AKI.<sup>10</sup>

Acute ingestion of naphthalene is an uncommon cause of poisoning in pediatric patients. Clinicians should be aware of the potential complications in that scenario, such as AKI, and the necessity of early identification, specific management, and follow up of these patients.

### Authors' contributions

KNM, BLC and SMBM contributed to the case data collection. JHHGLP contributed to the draft of the article and the creation of tables and figure. GBSJ, EFD, and PLMMA critically revised the article and approved the version to be published. All authors have read and approved the manuscript.

### REFERENCES

1. Arachchige G, Prasadi M, Mohamed F, Senarathna L, Cairns R, Hangidi P, et al. Paediatric poisoning in rural Sri Lanka: an epidemiological study. *BMC Public Health*. 2018;18:1–8.
2. Kapoor R, Satish PS. Acute intravascular hemolysis and methemoglobinemia following naphthalene ball poisoning. *Indian J Hematol Blood Transfus*. 2014;30:317–9.
3. Kundra TS, Bhutani V, Gupta R, Kaur P. Naphthalene poisoning following ingestion of mothballs: a case report. *J Clin Diagn Res*. 2015;128:8–9.
4. Ekambaram S, Km CK, Mahalingam V. Acute kidney injury: a rare complication of mothball (naphthalene) poisoning. *Saudi J Kidney Dis Transpl*. 2017;28:1412–5.
5. Dubey D, Sharma VD, Pass SE, Sawhney A, Stüve O. Para-dichlorobenzene toxicity – a review of potential neurotoxic manifestations. *Ther Adv Neurol Disord*. 2014;7:177–87.
6. Liu J, Drane W, Liu X, Wu T. Examination of the relationships between environmental exposures to volatile organic compounds and biochemical liver tests: application of canonical correlation analysis. *Environ Res*. 2010;109:423–39.
7. Volney G, Tatusov M, Yen AC, Karamyan N. Naphthalene toxicity: methemoglobinemia and acute intravascular hemolysis. *Cureus*. 2018;10:6–11.
8. Goodman JW, Goldfarb DS. The role of continuous renal replacement therapy in the treatment of poisoning. *Semin Dial*. 2006;19:402–7.
9. Uthuman AAA, Jayasinghe CS, Fernando AHN. Acute intravascular hemolysis due to naphthalene toxicity: a case report. *J Med Case Rep*. 2019;13:4–6.
10. Chou Y, Huang T, Chu T. ScienceDirect Novel insights into acute kidney injury e chronic kidney disease continuum and the role of renin e angiotensin system. *J Formos Med Assoc*. 2017;116:652–9.

José Hicaro Hellano Gonçalves Lima Paiva<sup>a,\*</sup>,  
Geraldo Bezerra Silva Júnior<sup>b</sup>,  
Karla do Nascimento Magalhaes<sup>c</sup>, Bianca Lopes Cunha<sup>d</sup>,  
Sandra Mara Brasileiro Mota<sup>c,e</sup>,  
Elizabeth de Francesco Daher<sup>e</sup>,  
Polianna Lemos Moura Moreira Albuquerque<sup>b,c</sup>

<sup>a</sup> State University of Ceara, Fortaleza, Ceara, Brazil

<sup>b</sup> Faculty of Medicine, Post-Graduate Program in Public Health and Medical Sciences of University of Fortaleza, Fortaleza, Ceara, Brazil

<sup>c</sup> Toxicological Information and Assistance Center, Instituto Doutor Jose Frota Hospital, Fortaleza, Ceara, Brazil

<sup>d</sup> General Hospital of Fortaleza, Fortaleza, Ceara, Brazil

<sup>e</sup> Post-Graduate Program in Medical Sciences of Federal University of Ceara, Fortaleza, Ceara, Brazil

\* Corresponding author.

E-mail addresses: [hellanohicaro@gmail.com](mailto:hellanohicaro@gmail.com),  
[pollylemos78@gmail.com](mailto:pollylemos78@gmail.com) (J.H.H.G.L. Paiva).

<https://doi.org/10.1016/j.nefro.2020.11.008>

0211-6995/© 2021 Sociedad Española de Nefrología. Published by Elsevier España, S.L.U. This is an open access article under the CC BY-NC-ND license (<http://creativecommons.org/licenses/by-nc-nd/4.0/>).

## SARS-CoV-2 and *Aspergillus* pneumonia in kidney transplantation: More frequent than we think?

### Neumonía por SARS-COV-2 y *Aspergillus* en trasplante renal: ¿más frecuente de lo que pensamos?

Dear Editor,

Invasive pulmonary aspergillosis can complicate some viral infections, such as the flu, and we are starting to perceive it as a poor prognostic factor in patients co-infected with SARS-CoV-2 pneumonia.

We report the case of a 67-year-old man with chronic kidney disease secondary to focal segmental glomerulonephritis, that was on haemodialysis. In June 2020, he received a kidney transplant, with induction with basiliximab and treatment with tacrolimus, mycophenolate and steroids. Also received combined prophylaxis with cotrimoxazole and valganciclovir.

Thirty (30) days after transplantation, the patient was diagnosed with SARS-CoV-2. The dose of immunosuppressants was reduced, and azithromycin and hydroxychloroquine were started. On day +14, he was admitted to the hospital due to fever and respiratory failure. Chest X-ray revealed bilateral infiltrates and laboratory tests showed creatinine 1.5 mg/dl, CRP 72 mg/l, Hb 10.6 g/dl, lymphocytes 340/ $\mu$ l, D-dimer 1.021 ng/ml and interleukin-6 31.9 pg/l. On admission, mycophenolate was discontinued and treatment was started with dexamethasone + remdesivir + ceftriaxone + prophylactic heparin. Based on criteria of severity it was decided to administer tocilizumab on the third day after admission and tacrolimus was suspended on the fifth day due to poor clinical course and supratherapeutic levels.

On day +7, he was admitted to the ICU due to reduced level of consciousness and respiratory failure requiring mechanical ventilation. Antibiotics were added, meropenem, amikacin, linezolid and voriconazole, maintaining prophylactic valganciclovir and Soltrim (trimethoprim/sulfamethoxazole). In addition to persistent positive PCR for SARS-CoV-2, *Aspergillus fumigatus* was found in the routine bronchial aspirate and

serum galactomannan was 4.5. Given the persistence of high levels of tacrolimus, voriconazole was replaced by intravenous isavuconazole. After 13 days of hospitalisation, the patient's clinical course deteriorated with massive cerebral haemorrhage and he died that same day.

In November 2020, the COVID-19 Registry of the Spanish Society of Nephrology (SEN) reported 2,474 patients on renal replacement therapy, 37% of which were kidney transplants.<sup>1</sup> This population is considered to be at higher risk due to their state of immunosuppression and frequent contact with health centres.<sup>2</sup>

Severely ill COVID-19 patients have higher concentrations of proinflammatory cytokines (IL-1, IL-2, IL-6 and tumour necrosis factor alpha) and anti-inflammatory cytokines (IL-4 and IL-10), with lower expression of interferon gamma, and they have lower numbers of CD4 and CD8 cells.<sup>3</sup> Therefore, the risk of suffering from fungal co-infections is greater.<sup>4</sup> In fact, an incidence of invasive aspergillosis of up to 0.65% has been described within the first year in kidney transplant recipients, with a mortality rate of up to 39% in the first 12 weeks.<sup>5</sup>

Despite the high number of COVID-19 cases reported, its association with invasive aspergillosis has not been well established. The EORTC/MSG European group concludes that the diagnosis of COVID-19-associated pulmonary aspergillosis (CAPA) is a challenge, since the radiological characteristics of the invasive fungal lesion overlap with the pre-existing alterations as a result of viral SARS-CoV-2 pneumonia.<sup>6,7</sup> In addition in COVID-19 patients, the high risk of aerosol generation limits the collection of respiratory samples (bronchial aspirate or bronchoalveolar lavage), so the diagnosis is often based on serum galactomannan antigen, and an index >0.7 is considered positive.<sup>8</sup>

There are many species of *Aspergillus* spp., but *Aspergillus fumigatus* complex is the most common aetiological agent. The