

transplant recipient with parvovirus B19 infection. Saudi J Kidney Dis Transpl. 2017;28:1447–50.

Lorena Noriega-Salas*, Jose Cruz-Santiago, Bibiana Lòpez-Lòpez, Catalina del Rosario Garcia-Ramirez, Arlette Robledo-Melendez

Unidad de Trasplante Renal, Instituto Mexicano del Seguro Social Centro Médico Nacional La Raza, Hospital de Especialidades “Dr. Antonio Fraga Mouret”, Centro Médico Nacional La Raza, Ciudad de México, Mexico

*Corresponding author.

E-mail address: noriega.lorena@hotmail.com (L. Noriega-Salas).

2013-2514/© 2021 Sociedad Española de Nefrología. Published by Elsevier España, S.L.U. This is an open access article under the CC BY-NC-ND license (<http://creativecommons.org/licenses/by-nc-nd/4.0/>). <https://doi.org/10.1016/j.nefro.2021.11.005>

Aplastic anemia associated with parvovirus B19 in living donor kidney transplantation: experience of a reference center[☆]

Dosis única de rituximab como tratamiento de recidiva de glomerulonefritis membranoproliferativa en trasplante renal

Dear Editor,

The current classification of membranoproliferative glomerulonephritis (MPGN) is based on immunofluorescence findings, with aetiological and therapeutic implications.¹

Idiopathic MPGN is uncommon.² Treatment recommendations are therefore based on case series and non-randomised clinical trials. Current therapy consists of corticosteroids and antiproliferative agents (mycophenolate, cyclophosphamide), monoclonal antibodies (rituximab, bortezomib) or plasmapheresis.^{3–5}

Worse kidney graft survival and a higher risk of relapse in kidney transplantation have been demonstrated in patients with MPGN compared to other forms of glomerulonephritis.²

We report the case of a 66-year-old man with a history of arterial hypertension and diabetes mellitus who, in 2012, developed kidney failure (creatinine 1.5 mg/dl, glomerular filtration rate [GFR] 50 ml/min) associated with nephrotic syndrome (proteinuria >15 g/24 h, hypoalbuminaemia and dyslipidaemia), with microscopic haematuria, without casts. The initial workup included antineutrophil cytoplasmic antibodies (ANCAs), antinuclear antibodies (ANAs), rheumatoid factor, protein electrophoresis in serum and urine (negative, normal C3 and C4).

The results of a kidney biopsy were consistent with type 1 MPGN. Immunofluorescence showed deposits of

immunoglobulin G (IgG) (3+), C3 (3+) and immunoglobulin M (IgM) (+) in the mesangium and capillary walls. Neoplasms and infections were ruled out as causes of glomerular injury (Fig. 1).

Treatment was started with angiotensin-converting enzyme (ACE) inhibitors plus mycophenolate and steroids, with no response after three months. Given the patient's progressive decline in kidney function, a decision was made to switch to oral cyclophosphamide plus steroids. This treatment was suspended after four months due to lack of response. In 2014, the patient started peritoneal dialysis.

In 2016, he received his first kidney graft from a cadaver donor, with five human leukocyte antigen (HLA) incompatibilities. Induction therapy was administered with thymoglobulin (6 mg/kg), mycophenolate, prednisone and tacrolimus. In the post-transplantation period, he showed slow recovery of kidney function with creatinine levels of up to 1 mg/dl (GFR > 70 ml/min) and proteinuria levels around 1.5 g/24 h, on treatment with ACE inhibitors. Three months after transplantation, he presented cytomegalovirus infection, which was treated with valganciclovir with a good response.

Six months after transplantation, the patient presented nephrotic syndrome of new onset, with proteinuria levels of 12 g/day and hypoalbuminaemia, with stable kidney function. An immunology workup and HLA antibodies were negative. The results of a kidney graft biopsy were consistent with immune complex-mediated diffuse endocapillary proliferative glomerulonephritis and C3 deposits. Immunofluorescence showed IgG (3+) and C3 (2+) with a diffuse subepithelial and mesangial granular pattern. The C4d antibody was negative.

DOI of original article:

<https://doi.org/10.1016/j.nefro.2021.11.010>

[☆] Please cite this article as: Cruzado Vega L, Santos García A., Dosis única de rituximab como tratamiento de recidiva de glomerulonefritis membranoproliferativa en trasplante renal. Nefrologia. 2021;41:601–603.

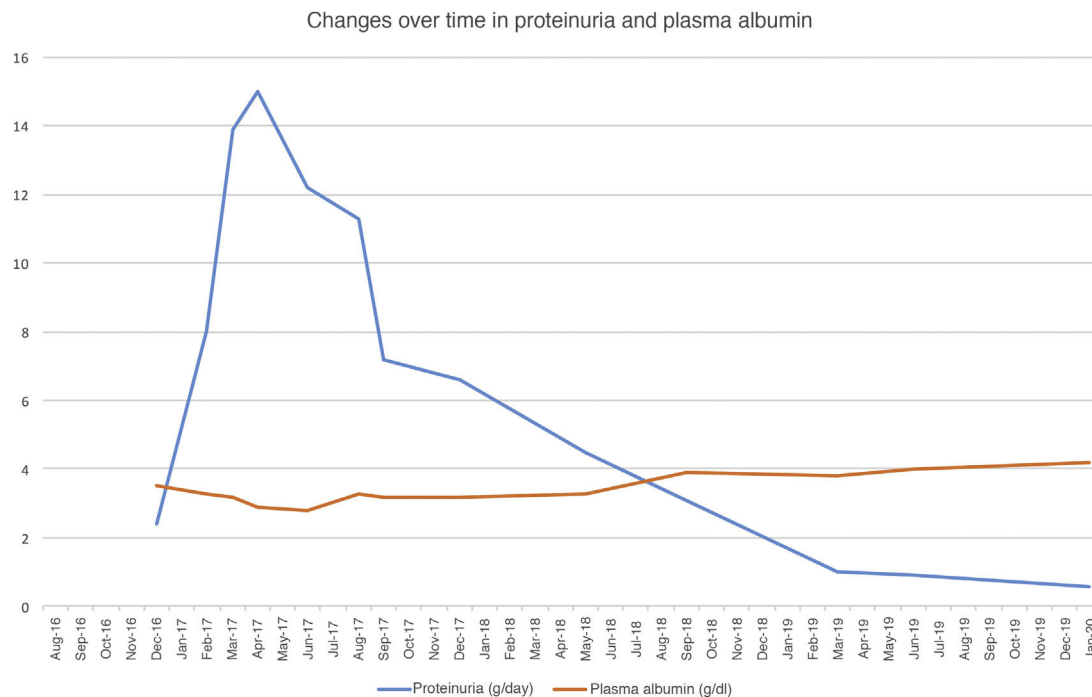


Fig. 1 – Changes over time in proteinuria and plasma albumin.

To treat MPGN recurrence, the patient's initial therapy included increasing mycophenolate to a dose of 2 g/day and increasing prednisone to a dose of 50 mg/day. He presented moderate cytomegalovirus viral load reactivation. Despite treatment, his nephrotic syndrome did not improve, reaching proteinuria levels as high as 17 g/24 h and serum albumin concentration of 2 g/dl. Changes over time in proteinuria and plasma albumin following transplantation are shown in Fig. 1.

Given that the prior cycle of cyclophosphamide had no response, a decision was made to administer treatment with rituximab (375 mg/m²). He received a dose of 1 g, with no complications. His CD19 lymphocyte levels, monitored every three months, were suppressed during the first year. After starting rituximab, the patient showed gradual resolution of proteinuria as of the first month, and after one year his nephrotic syndrome resolved. As of 2019, he has developed skin spinocellular and squamous cell carcinoma; consequently, he has been switched from mycophenolate to a mammalian target of rapamycin (m-TOR) inhibitor and his tacrolimus dose has been reduced, with no repercussions on his proteinuria. Two years after treatment with rituximab, his proteinuria has continued to drop (<1 g/day) and his kidney function is stable.

Post-transplant MPGN recurrence is very common; some series have reported rates as high as 50% in the first 24 months.⁶ At present, the optimum treatment for recurrence is not clear.

Rituximab (an anti-CD20 monoclonal antibody) has been used in case series, achieving complete or partial remission, although its dosing remains unclear.⁷

Other authors have used bortezomib in cases of MPGN with kappa chain deposits, with no prior diagnosis of dysproteinaemia, with a good clinical response.⁸

In our case, a single dose of 1 g was administered with regular monitoring of CD19 lymphocyte levels. As they remained reduced for up to approximately one year, no new doses were proposed. In conclusion, in our case, rituximab was effective in achieving remission of post-transplant recurrent MPGN. Complete response to treatment with rituximab is not immediate, with effects beyond one year following administration. Monitoring of CD19 lymphocyte levels may be useful to minimise the dose taken, and is particularly useful in transplant recipients given the cumulative immunosuppression load with the onset of undesirable effects, such as tumours and infections.

Conflicts of interest

The authors have no conflicts of interest to declare.

REFERENCES

- Pickering MC, D'Ágati VD, Nester CM, Smith RJ, Haas M, Appel GB, et al. C3 glomerulopathy: consensus report. *Kidney Int.* 2013;84:1079-89.
- Wilson GJ, Cho Y, Texeira-Pinto A, Isabel N, Campbell S, Hawley C, et al. Long-term outcomes of patients with end-stage kidney disease due to membranoproliferative glomerulonephritis: an ANZDATA registry study. *BCM Nephrol.* 2019;20:417.
- Hohenstein B. C3 glomerulopathy and MPGN – current classification. *Dtsch Med Wochenschr.* 2020;145:232-9.
- Töz H, Ok E, Unsal A, Aşçı G, Başdemir F G., Başçı A. Effectiveness of pulse cyclophosphamide plus oral steroid therapy in idiopathic membranoproliferative glomerulonephritis. *Nefrol Dial Transplant.* 1997;12:1081-2.
- Yuan M, Zou J, Zhang X, Liu H, Teng J, Zhong Y, et al. Combination therapy with mycophenolate mofetil and

prednisone in steroid-resistant idiopathic membranoproliferative glomerulonephritis. *Clin Nephrol.* 2010;73:354-9.

6. Lim WH, Shingde M, Wong G. Recurrent and de novo glomerulonephritis after kidney transplantation. *Front Immunol.* 2019;10:1944.
7. Allen PJ, Chadban SJ, Craig JC, Lim WH, Allen RDM, Clayton PA, et al. Recurrent glomerulonephritis after kidney transplantation: risk factors and allograft outcomes. *Kidney Int.* 2017;92:461-9, <http://dx.doi.org/10.1016/j.kint.2017.03.015>.
8. Von Visger J, Cassol C, Nori U, Franco-Ahumada G, Nadasdy T, Satoskar AA. Complete biopsy-proven resolution of deposits in recurrent proliferative glomerulonephritis with monoclonal IgG deposits (PGNMIGD) following rituximab treatment in renal allograft. *BCM Nephrol.* 2019;20:53.

Leonidas Cruzado Vega*, Alba Santos García

Hospital General Universitario de Elche, Alicante, Spain

*Corresponding author.

E-mail address: leocruzadov@hotmail.com (L. Cruzado Vega).

2013-2514/© 2021 Sociedad Española de Nefrología. Published by Elsevier España, S.L.U. This is an open access article under the CC BY-NC-ND license (<http://creativecommons.org/licenses/by-nc-nd/4.0/>).
<https://doi.org/10.1016/j.nefro.2021.11.003>

Clinical utility of hybrid (SPECT/CT) imaging in calciphylaxis

Utilidad clínica de las imágenes híbridas (SPECT/CT) en la calcifilaxis

Dear Editor,

We congratulate Herrera-Martínez et al. for the excellent management of their patient with calciphylaxis.¹ With regards to the role of hybrid imaging in calciphylaxis we would like to mention few additional points which we believe could add to the fund of knowledge of our readers.

The important question to the research bodies working on calciphylaxis will be would hybrid image (SPECT/CT) replace skin biopsy. As suggested by Herrera-Martínez et al., skin biopsy has its own limitations and complications and any test like SPECT/CT hold that potential. However, we want to bring into the discussion regarding the close differentials of calciphylaxis. Will SPECT/CT be able to differentiate the various skin lesions like cellulitis, vasculitis, or atherosclerosis or warfarin necrosis? Other questions that require immediate attention are: cost effectiveness and clinical utility of early vs late SPECT/CT, clinical benefit of combined diagnostic approach (SPECT/CT plus skin biopsy) versus SPECT/CT alone, random skin biopsy of skin lesions vs SPECT/CT guided biopsy of the most intense uptake site. Most common site of calciphylaxis is lower limbs which is usually amenable site for skin biopsy. There are specific locations like penis where skin biopsy is contraindicated.^{2,3} In such locations, we believe that the clinical utility of SPECT/CT alone could potentially of extreme importance. Successful treatment by Herrera-Martínez et al. also encourages us to think that is there any correlation between the differential responses to therapy depending on extent of calciphylactic lesions detected on SPECT/CT?

Due to lower specificity of SPECT/CT, should we limit this study only to long-term non-healing ulcers in the setting of

end-stage renal failure? We highlight this point due to the fact that there are many other clinical differentials for the skin lesions in ESRD patients and doing a SPECT/CT in all cases may not be justified. The skin lesions in Herrera-Martínez et al. case was just few days old for which SPECT/CT was done. We wish to educate our readers not to make any general inference to do SPECT/CT in all cases of newly evolved skin lesions in ESRD. Ideal would be to diligently rule out all the other differentials as mentioned above.⁴ Another point on which future studies can be directed is to study the follow up SPECT/CT to see the follow up response of calciphylaxis to treatment of sodium thiosulphate.

In conclusion, newer non-invasive advancements in detecting calciphylaxis are encouraging but there are still many questions that needs to be settled before any guidelines can be laid down.⁵

Ethical statement

The article does not contain the participation of any human being and animal.

Funding

None declared.

Conflict of interest

Authors have no conflicts of interest to declare.