

Our patient had the distinguishing feature of the disease on the basis of clinical symptoms: hypertension, proteinuria, microhematuria, family history and pathological manifestation: intense staining for the serum fibronectin, Congo red staining negative. At present, there are no specific treatments for FNG. Our patient had received angiotensin receptor blocker (ARB) and Shenyanhu tablets. After 3 months of follow-up, the urine protein was 2.85 g/day. The proteinuria became less. However, further observation was needed to the proteinuria and renal function.

### Conflict of interest

The authors declare that they have no conflict of interest.

### REFERENCES

- Burgin M, Hofmann E, Reutter FW, et al. Familial glomerulopathy with giant fibrillar deposits. *Vinchows Arch A Pathol Anat Histol.* 1980;338:313–26.
- Strøm EH, Benfi G, Krapf R, et al. Glomerulopathy associated with predominant fibronectin deposits: a newly recognized hereditary disease. *Kidney Int.* 1995;48:163–70.
- Cheng G, Wang Z, Yuan W, et al. Fibronectin glomerulopathy in a 88 year-old male with acute kidney injury on chronic kidney disease: a case report and a review of the literature. *Nefrologia.* 2017;37:93–6.
- Deltas C, Pierides A, Voskarides K. Molecular genetics of familial hematuric diseases. *Nephrol Dial Transplant.* 2013;28:2946–60.

- Ohashi T, Lemmon CA, Erickson HP. Fibronectin conformation and assembly: analysis of fibronectin deletion mutants and fibronectin Gglomerulopathy (GFND) mutants. *Biochemistry.* 2017;56:4584–91.
- Ohtsubo H, Okada T, Nozu K, et al. Identification of mutations in FN1 leading to glomerulopathy with fibronectin deposits. *Pediatr Nephrol.* 2016;31:1459–67.
- Yong JL, Killingsworth MC, Spicer ST, et al. Fibronectin non-amyloid glomerulopathy. *Int J Clin Exp Pathol.* 2009;210–6.
- Zeng CH, Liu ZH, Zheng CX, et al. Fibronectin glomerulopathy. *J Nephrol Dialy Transplant.* 2007;16:488–93 [Chinese].
- Nadamuni M, Piras R, Mazbar S, et al. Fibronectin glomerulopathy: an unusual cause of adult-onset nephritic syndrome. *Am J kidney.* 2012;60:839–42.
- Otsuka Y, Takeda A, Horike K, et al. A recurrent fibronectin glomerulopathy in a renal transplant patient: a case report. *Clin Transplant.* 2012;26 Suppl. 24:58–63.

Ting Wang\*, Hong Bw

Department of Nephrology, The Third Hospital of Mian Yang (Sichuan Mental Health Center), Mian Yang, Si Chuan, PR, China

\* Corresponding author.

E-mail address: 21917708@qq.com (T. Wang).

<https://doi.org/10.1016/j.nefro.2020.01.004>

0211-6995/© 2020 Published by Elsevier España, S.L.U. on behalf of Sociedad Española de Nefrología. This is an open access article under the CC BY-NC-ND license (<http://creativecommons.org/licenses/by-nc-nd/4.0/>).

## Letter to the Editor

# Treatment with alirocumab in a patient on peritoneal dialysis with statin intolerance<sup>☆</sup>

## Tratamiento con alirocumab en paciente en diálisis peritoneal con intolerancia a estatinas

### ARTICLE INFO

Article history:

Dear Editor,

Statin intolerance affects 10–20% of patients who start treatment with these drugs.<sup>1</sup> Discontinuation of the drug is

mainly due to the muscular side effects associated with the medication.<sup>2</sup>

In recent years, studies have been conducted with pro-protein convertase subtilisin/kexin type 9 inhibitor (PCSK9i) monoclonal antibodies<sup>3</sup> that have proven to be effective in

DOI of original article:

<https://doi.org/10.1016/j.nefro.2020.04.015>.

<sup>☆</sup> Please cite this article as: Rivas Oural A, Astudillo Cortés E, Bande Fernández JJ, Rodríguez Suárez MDC, Díaz Corte MDC. Tratamiento con alirocumab en paciente en diálisis peritoneal con intolerancia a estatinas. *Nefrologia.* 2021;41:76–79.

**Table 1 – Lipid profile of a PD patient receiving treatment with alirocumab.**

	Aug. 17	Nov. 17	Start of treatment with alirocumab							
			Jan. 18	Feb. 18	Apr. 18	Jun. 18	Sep. 18	Dec. 18	Jan. 19	Mar. 19
TC (mg/dL)	255	249	246	102	122	135	141	155	171	168
HDL-C (mg/dL)	26	30	27	31	31	27	36	30	30	37
TGC (mg/dL)	375	473	448	188	216	341	231	321	353	307
LDL-C (mg/dL)	138	143	137	69	48	47	59	59	70	68

reducing levels of low-density lipoprotein cholesterol (LDL-C) and a safe alternative for those patients in whom the use of statins is contraindicated.

In addition, both the ODYSSEY<sup>4</sup> (alirocumab) and FOURIER<sup>5</sup> (evolocumab) trials showed a reduction in non-fatal infarction, ischaemic stroke and hospitalisation for stable angina, plus a 15% decrease in cardiovascular events with no reduction in mortality. Taking all this into consideration, in September 2015 the European Community authorised the use of alicumab<sup>6</sup> as a lipid-lowering treatment.

In these two trials, only patients with a glomerular filtration rate (GFR) of  $\geq 30$  mL/min/1.73 m<sup>2</sup> and  $\geq 20$  mL/min/1.73 m<sup>2</sup> were included, respectively. In addition, in the study with alicumab,<sup>7</sup> a subgroup analysis was performed according to their stage of chronic kidney disease (CKD),<sup>8</sup> showing a similar reduction in LDL-C levels in both groups, without changes in kidney disease progression and with good drug tolerance and safety levels. None of these trials included patients on renal replacement therapy.<sup>8</sup>

We present the case of a 58-year-old male patient with a personal history of arterial hypertension being treated with three drugs, including an angiotensin II receptor antagonist and a diuretic. He has insulin-dependent type 2 diabetes mellitus with micro- and macrovascular involvement; a body mass index of 31.1 kg/m<sup>2</sup>; ischaemic-valvular heart disease with a revascularised anterior descending artery and surgical aortic valve replacement in 2012; preserved left ventricular ejection fraction; and chronic lower limb ischaemia due to femoropopliteal stenosis.

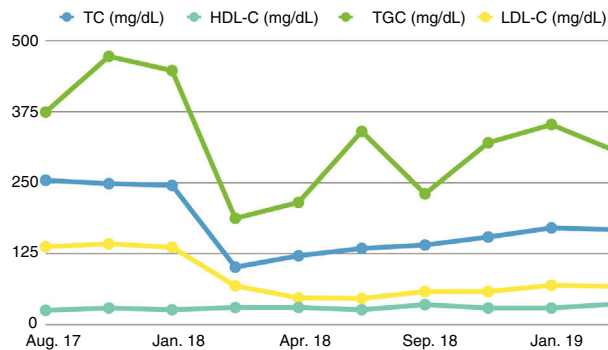
The patient has chronic kidney disease (CKD) stage 5D secondary to diabetic nephropathy, which has never been biopsied. He has been on peritoneal dialysis since October 2012, currently on automated peritoneal dialysis with a wet day. Total volume: 15l. Tests reveal a Kt/V of 1.78 and a total weekly clearance of 67.52. The patient maintains a residual diuresis of 700–1,000 mL/day.

Regarding treatment, in 2004 he started treatment with statins (pravastatin) at 20 mg/day. Due to myalgia and elevated creatine kinase (CK), he was changed to atorvastatin 20 mg/day and he also presented levels of CK > 900 mg/dL, leading to discontinuation of the treatment. Subsequently, other drugs such as ezetimibe, fenofibrate and Omacor have been administered, without achieving LDL-C targets.

In November 2017, he had a total cholesterol (TC) level of 249 mg/dL, triglycerides (TGC) 473 mg/dL, high-density lipoprotein (HDL) cholesterol 30 mg/dL and LDL-C levels of 143 mg/dL. As a result, treatment with PCSK9i was proposed in order to achieve target levels in line with his cardiovascular profile (LDL-C 70 mg/dL).

There are no studies that analyse the use of PCSK9i in patients with stage 4–5 CKD or who are receiving renal replacement therapy, but the use of alicumab is not contraindicated in its summary of product characteristics. As a result, after being approved by the pertinent committee, the decision was made to start treatment at a dose of 75 mg every 2 weeks, with continuation of treatment with ezetimibe.

The patient's TC levels improved from the onset of treatment, reaching target levels of LDL-C from the third month of treatment that have been maintained to date, as can be seen in the lipid profile shown in Table 1 and Fig. 1. During this time, only a flu-like illness was detected as an adverse



**Fig. 1 – Lipid profile evolution in a PD patient receiving treatment with alicumab.**

effect, with myalgia and cramps following the first administrations of the drug, with no subsequent symptoms or added adverse reactions. As such, the treatment has been maintained.

In conclusion, in this patient on peritoneal dialysis, alicumab treatment has proven to be useful and safe in lowering LDL-C levels, reaching the target levels for his cardiovascular risk profile and maintaining these figures during the follow-up period, with no associated complications.

This case may be of particular interest since there are no studies reported in the literature that analyse the use of this drug in patients on renal replacement therapy, mainly because these patients have not been included in clinical trials.<sup>9</sup> In addition, it is noteworthy that the treatment continues to be effective in achieving LDL-C targets without the onset of side effects. It would be necessary to perform controlled and randomised clinical trials in patients with end-stage renal disease, GFR < 15 mL/min, in order to gather a more substantial case history with a longer follow-up period and assess whether the beneficial effects in terms of cardiovascular morbidity and mortality are reproduced without serious adverse effects.<sup>10</sup>

## REFERENCES

- Maningat P, Breslow JL. Needed: pragmatic clinical trials for statin-intolerant patients. *N Engl J Med.* 2011;365:2250–1 <https://doi.org/10.1056/NEJMp1112023>
- Wilson PWF, Polonsky TS, Miedema MD, Khera A, Kosinski AS, Kuvin JT. Systematic review for the 2018AHA/ACC/AACVPR/AAPA/ABC/ACPM/ADA/AGS/APhA/ASPC/NLA/PCNA guideline on the management of blood cholesterol. *Circulation.* 2019;139:e1144–210.
- Burnett JR, Hooper AJ. PCSK9 - a journey to cardiovascular outcomes. *N Engl J Med.* 2018;379:2161–2, <http://dx.doi.org/10.1056/NEJMe1813758>.
- Schwartz GG, Bessac L, Berdan LG, Bhatt DL, Bittner V, Diaz R, et al. Effect of alicumab, a monoclonal antibody to PCSK9, on long-term cardiovascular outcomes following acute coronary syndromes: rationale and design of the ODYSSEY outcomes trial. *Am Heart J.* 2014;168(5):682–9, <http://dx.doi.org/10.1016/j.ahj.2014.07.028>.
- Sabatine MS, Giugliano RP, Keech AC, Honarpour N, Wiviott SD, Murphy SA, et al. FOURIER Steering Committee and Investigators. Evolocumab and clinical outcomes in patients with cardiovascular disease. *N Engl J Med.* 2017;376:1713–22, <http://dx.doi.org/10.1056/NEJMoa1615664>.

6. Ficha Técnica de Praluent® (alirocuma). [Internet]. Disponible en [http://www.ema.europa.eu/docs/es\\_ES/document\\_library/EPAR\\_-Product\\_Information/human/003882/WC500194521.pdf](http://www.ema.europa.eu/docs/es_ES/document_library/EPAR_-Product_Information/human/003882/WC500194521.pdf).
7. Toth PP, Dwyer JP, Cannon CP, Colhoun HM, Rader DJ, Upadhyay A, et al. Efficacy and safety of lipid lowering by alirocumab in chronic kidney disease. *Kidney International*. 2018;93:1397–408, <http://dx.doi.org/10.1016/j.kint.2017.12.011>.
8. Mafham M, Haynes R. PCSK9 inhibition: ready for prime time in CKD? *Kidney Int*. 2018;93:1267–9, <http://dx.doi.org/10.1016/j.kint.2018.01.030>.
9. Del Vecchio L, Baragetti I, Locatelli F. New agents to reduce cholesterol levels: implications for nephrologists. *Nephrol Dial Transplant*. 2020;35:213–8 <https://doi.org/10.1093/ndt/gfz013>
10. Shrestha P, van de Sluis B, Dullaart RPF, van den Born J. Novel aspects of PCSK9 and lipoprotein receptors in renal disease-related dyslipidemia. *Cell Signal*. 2019;55(53) <https://doi.org/10.1016/j.cellsig.2018.12.001>
- Alba Rivas Oural\*, Elena Astudillo Cortés, Jose Joaquín Bande Fernández, María del Carmen Rodríguez Suárez, María del Carmen Díaz Corte
- Departamento de Nefrología, Hospital Universitario Central de Asturias, Oviedo, Asturias, Spain*
- \*Corresponding author.
- 6 November 2019  
<https://doi.org/10.1016/j.nefro.2020.04.006>
- 2013-2514/© 2020 Sociedad Española de Nefrología. Published by Elsevier España, S.L.U. This is an open access article under the CC BY-NC-ND license (<http://creativecommons.org/licenses/by-nc-nd/4.0/>).

## Letter to the Editor

# Intravesical cidofovir, use in BK polyomavirus-associated haemorrhagic cystitis after haematopoietic stem cell transplantation: off-label<sup>☆</sup>

## Cidofovir intravesical, uso en cistitis hemorrágica por poliomavirus bk tras un trasplante de progenitores hematopoyéticos: off-label

### ARTICLE INFO

#### Article history:

Dear Editor,

Haemorrhagic cystitis is defined as inflammation of the bladder mucosa that causes acute or subacute diffuse bleeding.<sup>1</sup> It is caused by the inappropriate activation of proinflammatory cytokines, which destroy the mucosa and chorion through inflammatory apoptosis (pyroptosis), which leads to the opening of the microvessels to the bladder lumen. The main causes of bladder pyroptosis are bacterial or viral pathogens, ionising radiation or acrolein, a urinary metabolite of cyclophosphamide and ifosfamide.<sup>2</sup>

The BK virus is one of the most important causes of late-onset haemorrhagic cystitis in patients undergoing haematopoietic cell transplantation (HCT). The evidence for the treatment of BK virus-associated haemorrhagic cystitis

(BKV–HC) is limited, with cidofovir being one of the treatment options.<sup>3</sup> Cidofovir is a cytidine analogue that demonstrates in vitro and in vivo activity against human cytomegalovirus (HCMV) because it suppresses replication by selective inhibition of viral DNA synthesis.<sup>4</sup> The use of this drug in BKV–HC would be off-label.

This is the case of a 53-year-old man with no known drug allergies and with a personal history of dyslipidaemia and arterial hypertension.

The patient was diagnosed in 2016 with chronic myelomonocytic leukaemia (CML) and, after several cycles of chemotherapy (MAZE: amsacrine-azacitidine-etoposide; IDA-ARA-C: idarubicin-cytarabine), he underwent allogeneic haematopoietic stem cell transplantation (Allo-HSCT) in May 2018.

DOI of original article:

<https://doi.org/10.1016/j.nefro.2020.02.005>.

<sup>☆</sup> Please cite this article as: Ferrer A, Viña MM, Limiñana EP, Merino J. Cidofovir intravesical, uso en cistitis hemorrágica por poliomavirus BK tras un trasplante de progenitores hematopoyéticos: off-label. *Nefrología*. 2021;41:79–80.