

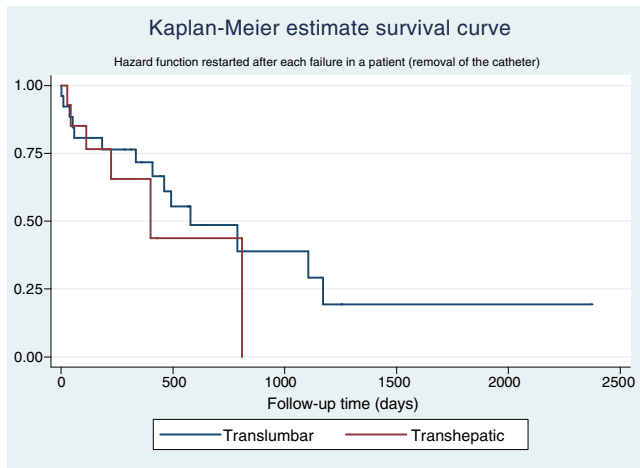Fig. 1 – Catheter survival by insertion site.

REFERENCES

1. Younes H, Pettigrew C, Anaya-Ayala J, Soltes G, Saad W, Davies M, et al. Transhepatic hemodialysis catheters: functional outcome and comparison between early and late failure. *J Vasc Interv Radiol.* 2011;22:183–91.
2. Power A, Singh S, Ashby D, Hamady M, Moser S, Gedroyc W, et al. Translumbar central venous catheters for long-term haemodialysis. *Nephrol Dial Transplant.* 2010;25:1588–95.
3. El Gharib M, Niazi G, Hetta W, Makkeyah Y. Transhepatic venous catheters for hemodialysis. *Egypt J Radiol Nucl Med.* 2014;45:431–8.
4. Smith T, Ryan M, Reddan D. Transhepatic catheter access for hemodialysis. *Radiology.* 2004;232:246–51.
5. da Motta M, Carnevale F, Nasser F, de Oliveira W, Zurtrassen C, Motta A, et al. Percutaneous transhepatic venous access for hemodialysis: an alternative route for patients with end-stage renal failure. *J Vasc Bras.* 2010;9, <http://dx.doi.org/10.1590/S1677-54492010000300006>.
6. Liu F, Bennett S, Arrigain S, Schold J, Heyka R, McLennan G, et al. Patency and complications of translumbar dialysis catheters. *Sem Dial.* 2015;28:E41–7.
7. Stavropoulos SW, Pan JJ, Clark TWI, Soulen MC, Shlansky-Golberg RD, Itkin M, et al. Percutaneous transhepatic venous access for hemodialysis. *J Vasc Interv Radiol.* 2003;14:1187–90.
8. Lund GB, Lieberman RP, Haire WD, Martin VA, Kessinger A, Armitage JO. Translumbar inferior vena cava catheters for long-term venous access. *Radiology.* 1990;174:31–5.
9. Nadolski G, Trerotola S, Stavropoulos W, Shlansky-Goldberg R, Soulen M, Farrelly C. Translumbar hemodialysis catheters in patients with limited central venous access: does patient size matter? *J Vasc Interv Radiol.* 2013;24:997–1002.

Juan Rodriguez Mori*, Jhony Ramirez Alguier, Carla Postigo Oviedo, Piero Mora Munares, Manuel Llaró Sánchez, Max Caballero Linares, Manuel Castillo Zegarra

Unidad de Radiología Intervencionista, Servicio de Nefrología, Hospital Nacional Alberto Sabogal Sologuren, Lima, Peru

* Corresponding author.

E-mail addresses: kiker98@hotmail.com, rodriguezemori.juan@gmail.com (J.R. Mori).

2013-2514/© 2018 Sociedad Española de Nefrología. Published by Elsevier España, S.L.U. This is an open access article under the CC BY-NC-ND license (<http://creativecommons.org/licenses/by-nc-nd/4.0/>). <https://doi.org/10.1016/j.nefro.2017.12.006>

Improvement of bilateral lower-limb muscle oxygenation by low-density lipoprotein apheresis in a patient with peripheral artery disease undergoing hemodialysis

Mejora de la oxigenación en los músculos de ambos miembros inferiores mediante aféresis de lipoproteínas de baja densidad en un paciente con arteriopatía periférica sometido a diálisis

Dear Editor:

Low-density lipoprotein apheresis (LDL-A), frequently used for peripheral artery disease (PAD) treatment, is expected

to induce the improvement of systemic microcirculation.¹ Recently, near-infrared spectroscopy was used to evaluate tissue regional oxygen saturation (rSO₂) in haemodialysis (HD) patients.²⁻⁵ However, there is no report regarding the relation

between LDL-A and changes in tissue oxygenation. In our HD patient, we confirmed an improvement in lower-limb muscle oxygenation during LDL-A.

An 82 year-old woman receiving HD was referred to our hospital for treatment of PAD recurrence. Her past medical history included hypertension and insulin-dependent diabetes. HD was initiated beginning 5-years prior. She was diagnosed with PAD and underwent bypass surgery for the right lower leg 4-years ago. Deteriorations of colour of foot skin and foot ulceration were recently confirmed bilaterally in the lower legs; therefore, LDL-A was performed for preventing PAD progression in our dialysis centre. Blood circuits of each LDL-A and HD were tandemly connected: each therapy was simultaneously performed. LDL-A was performed using Plasmaflo OP (Asahi Kasei Medical, Tokyo, Japan) as a plasma separator, a dextran sulfate cellulose column (Liposorba 15, Kaneka, Osaka, Japan) as a LDL absorber, and 1000 U/h of heparin sodium as an anti-coagulant. Plasma volume was treated at a rate of 50 mL/kg per LDL-A session. The duration of LDL-A with HD was 4-h: totally, she received LDL-A once a week for 10 consecutive weeks. During these 10 weeks of LDL-A with HD, other sessions of HD therapy twice a week was performed at a dialysis clinic that she had been receiving that therapy. To confirm LDL-A's influence on microcirculation impairment, tissue rSO_2 values in brain and lower-limb muscle were monitored from LDL-A with HD initiation to the end. Written informed consent for rSO_2 monitoring during that therapy was obtained. Values of rSO_2 were monitored at forehead and bilateral lower-limbs above the gastrocnemii using INVOS 5100c (Covidien Japan, Tokyo, Japan) during second, sixth and 10th sessions of LDL-A with HD. Fluid was removed by ultrafiltration at the level of 1.3 ± 0.4 L/session, and haemoglobin levels increased from 9.9 ± 0.4 g/dL before LDL-A with HD to 11.0 ± 0.2 g/dL after therapy. The rSO_2 ratios (mean \pm standard deviation) in bilateral lower-limb muscles rapidly increased from LDL-A with HD initiation to the end, whereas cerebral rSO_2 ratio did not change during that therapy (Fig. 1). Notably, changes in the colour of the foot skin and foot ulceration status improved by LDL-A with HD for 10 consecutive weeks.

LDL-A has been applied in PAD patients in whom efficacy of conventional pharmacological therapy is insufficient and/or those who are unavailable for surgical therapy because LDL-A itself improves peripheral microcirculation via blood rheology amelioration; reduction of blood and plasma viscosity; production of vasodilating nitric oxide, eicosanoids, and bradykinin; improvement of endothelial function through reduction of total LDL and oxidized LDL concentrations; and reduction of circulating inflammatory cytokines and chemokines.⁶ Improvement of peripheral microcirculation associated with LDL-A would also be expected to improve tissue oxygenation via increased oxygen supply in peripheral tissues. Indeed, oxygen partial pressure (pO_2) in the anterior tibial muscle rapidly and significantly increased during LDL-A in cardiac allograft vasculopathy patients.⁷ In the present case, bilateral lower-limb muscle oxygenation rapidly improved from LDL-A with HD initiation to the end; our result is consistent with a previous report.⁷ Ebihara et al. measured systemic blood flow using a laser doppler blood flowmeter during LDL-A, and reported significant increases in tissue blood flow in the head and lower limbs, in which the increase

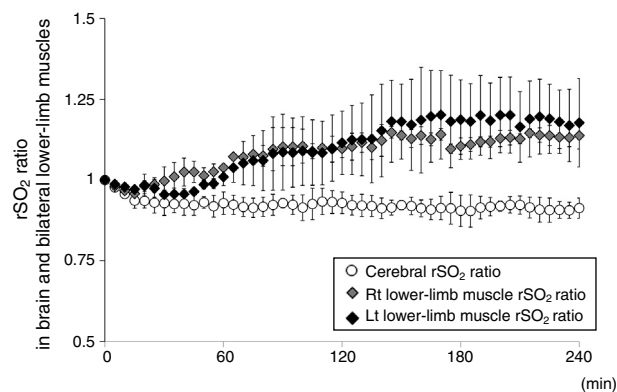


Fig. 1 – The changes in rSO_2 of the forehead and bilateral lower-limb muscle as per the oxygenation values of cerebral and muscle tissues, respectively, under LDL-A with HD. rSO_2 ratio is defined as the ratio of rSO_2 value at t (min) during HD and initial rSO_2 value before HD (rSO_2 at t (min) during HD/initial rSO_2 before HD). The open circle represents the changes in cerebral rSO_2 values, the grey diamond shape represents the changes in right lower-limb muscle rSO_2 values, and the block diamond shape represents the changes in left lower-limb muscle rSO_2 values.

of blood flow was significantly higher in the lower limbs than in the head.¹ We did not evaluate the level of tissue blood flow during LDL-A with HD in this case; therefore, we cannot comment on LDL-A-induced blood flow changes in systemic tissues. However, regarding cerebral oxygenation, little changed despite the increase in lower-limb muscle oxygenation; these differences in tissue oxygenation in the brain and lower-limb muscle might be explained by differences in blood flow increase in the head and lower-limb muscle previously reported.¹ Additionally, our patient simultaneously received LDL-A and HD therapy; therefore, it could not be definitively determined that the improvement in bilateral lower-limb muscle oxygenation was derived only from the application of LDL-A itself. Regarding tissue oxygenation during HD, there were reportedly no significant changes in cerebral and lower-limb muscle rSO_2 values during HD, respectively, although Hb levels after HD increased compared with those before HD.^{2,8} Therefore, the improvement in muscle oxygenation seen in this case might be caused not by HD therapy but by LDL-A itself.

In conclusion, LDL-A may have improved lower-limb muscle oxygenation in our patient. Thus, it might have positive effects for lower-limb muscle microcirculation.

Conflict of interest statement

The authors have declared that no conflict of interest exists.

Acknowledgement

We thank the monitored HD patient and dialysis staffs members in our hospital. This work was supported with a grant

from the Japanese Association of Dialysis Physicians (No. 27088) provided to S.O., and a grant from The Kidney Foundation, Japan (JKFB16-3) provided to S.O.

REFERENCES

- Ebihara I, Sato T, Hirayama K, Seki M, Enami T, Kawahara H, et al. Blood flow analysis of the head and lower limbs by the laser Doppler blood flowmeter during LDL apheresis. *Ther Apher Dial.* 2007;11:325-30.
- Hoshino T, Ookawara S, Goto S, Miyazawa H, Ito K, Ueda Y, et al. Evaluation of cerebral oxygenation in patients undergoing long-term hemodialysis. *Nephron Clin Pract.* 2014;126:57-61.
- Ito K, Ookawara S, Ueda Y, Goto S, Miyazawa H, Yamada H, et al. Factors affecting cerebral oxygenation in hemodialysis patients: cerebral oxygenation associates with pH, hemodialysis duration, serum albumin concentration, and diabetes mellitus. *PLOS ONE.* 2015;10:e0117474.
- Malik J, Kudlicka J, Lachmanova J, Valerianova A, Rocinova K, Bartkova M, et al. Tissue ischemia worsens during hemodialysis in end-stage renal disease patients. *J Vasc Access.* 2017;18:47-51.
- Ito K, Ookawara S, Ueda Y, Uchida T, Kofuji M, Hayasaka H, et al. Blood transfusion during haemodialysis improves systemic tissue oxygenation: a case report. *Nefrologia.* 2017;37:435-7.
- Hirai K, Ookawara S, Miyazawa H, Ito K, Ueda Y, Kaku Y, et al. Low-density lipoprotein apheresis ameliorates monthly estimated glomerular filtration rate declines in patients with renal cholesterol crystal embolism. *J Artif Organs.* 2015;18:72-8.
- Matschke K, Mrowietz C, Stemitzky R, Jung F, Park JW. Effect of LDL apheresis on oxygen tension in skeletal muscle in patients with cardiac allograft vasculopathy and severe lipid disorder. *Clin Hemorheol Microcirc.* 2004;30:263-71.
- Ookawara S, Ito K, Ueda Y, Miyazawa H, Hayasaka H, Kofuji M, et al. Differences in tissue oxygenation and changes in total hemoglobin signal strength in the brain, liver, and lower-limb muscle during hemodialysis. *J Artif Organs.* 2017 Aug 7, <http://dx.doi.org/10.1007/210047-017-0978-1>.

Kiyonori Ito^a, Susumu Ookawara^{a,*}, Yuichiro Ueda^a, Hideyuki Hayasaka^b, Masaya Kofuji^b, Takayuki Uchida^b, Harunobu Matsumoto^c, Atsushi Yamaguchi^c, Yoshiyuki Morishita^a

^a Division of Nephrology, First Department of Integrated Medicine, Saitama Medical Center, Jichi Medical University, Saitama, Japan

^b Department of Clinical Engineering, Saitama Medical Center, Jichi Medical University, Saitama, Japan

^c Department of Cardiovascular Surgery, Saitama Medical Center, Jichi Medical University, Saitama, Japan

* Corresponding author.

E-mail address: su-ooka@hb.tp1.jp (S. Ookawara).

2013-2514/© 2018 Sociedad Española de Nefrología. Published by Elsevier España, S.L.U. This is an open access article under the CC BY-NC-ND license (<http://creativecommons.org/licenses/by-nc-nd/4.0/>).

<https://doi.org/10.1016/j.nefro.2018.12.001>

Potentially inappropriate prescribing in patients on dialysis using STOPP-START criteria[☆]

Prescripción potencialmente inapropiada en pacientes en diálisis utilizando los criterios STOPP-START

Dear Editor,

Potentially inadequate prescription (PIP) are prescription with a risk of adverse effects that are superior to the clinical benefit. PIP is also considered if doses or duration of treatment are more than optimal, with potential interactions with other medications and with the patient's diseases, also includes therapeutic duplicities. In addition, it is inadequate the omission of medications with established indication in a specific patient.

One of the most used tools in Europe for the detection of PIP is the criteria of Screening Tool of Older Person's inappropriate

Prescription (STOPP)/Screening Trial to Alert Doctor to Right Treatment (START) proposed by Gallagher et al. in 2008¹ and accepted by the Spanish Society of Geriatric.² They have been recently updated with incorporating new data, or the arrival of new drugs and identification of drugs considered potentially inadequate.^{3,4}

There is little information about PIP in patients with chronic renal failure.⁵⁻⁷ Therefore, we decided to perform a study aiming to detect systematically the PIP, according to the STOPP/START criteria, in the 103 dialysis patients followed in our hospital. For this, the pharmacotherapeutic records of all these patients were reviewed, considering the following

DOI of original article:

<https://doi.org/10.1016/j.nefro.2018.03.001>.

[☆] Please cite this article as: Gonzalez-Lopez A, Nava-Rebollo A, Chocarro-Martinez A, Andres-Martin B, Santana-Zapatero H, Herrera-Gomez F, et al. Prescripción potencialmente inapropiada en pacientes en diálisis utilizando los criterios STOPP-START. *Nefrologia.* 2019;39:92-94.