

Inform consent

Written informed consent for publication of this case report was obtained from the patient

Conflict of interest

The authors declare no conflict of interest regarding the publication of this article.

BIBLIOGRAFÍA

- Ranganathan V, Gracey E, Brown MA, Inman RD, Haroon N. Pathogenesis of ankylosing spondylitis – recent advances and future directions. *Nat Rev Rheumatol*. 2017;13:359–67, <http://dx.doi.org/10.1038/nrrheum.2017.56>.
 - Enginar AU, Kacar C. Neutrophil-lymphocyte and platelet-lymphocyte rate and their seasonal differences in ankylosing spondylitis and rheumatoid arthritis patients using anti-TNF medication. *Bratisl Lek Listy*. 2019;120:586–92, <http://dx.doi.org/10.4149/BLL.2019.096>.
 - Barbouch S, Hajji M, Jaziri F, Aoudia R, Fellah E, Hedri H, et al. Renal amyloidosis in ankylosing spondylitis: a monocentric study and review of literature. *Saudi J Kidney Dis Transpl*. 2018;29:386–91, <http://dx.doi.org/10.4103/1319-2442.229291>.
 - Chen R, Li F, Xie Q, Xue J, Lai L, Liu S, et al. Membranous nephropathy in a patient with ankylosing spondylitis: a case report. *Medicine (Baltimore)*. 2017;96:e8201, <http://dx.doi.org/10.1097/MD.0000000000008201>.
 - Geetha D, Jefferson JA. ANCA-associated vasculitis: core curriculum 2020. *Am J Kidney Dis*. 2020;75:124–37, <http://dx.doi.org/10.1053/j.ajkd.2019.04.031>.
 - Yu DT, Tubergen AV. Diagnosis and differential diagnosis of axial spondyloarthritis (ankylosing spondylitis and nonradiographic axial spondyloarthritis) in adults. Available at: <https://www.uptodate.com/contents/diagnosis-and-differential-diagnosis-of-axial-spondyloarthritis-ankylosing-spondylitis-and-nonradiographic-axial-spondyloarthritis-in-adults> [accessed 29.01.21].
 - Falk RJ, Merkel PA. Granulomatosis with polyangiitis and microscopic polyangiitis: management of disease resistant to initial therapy. Available at: <https://www.uptodate.com/contents/granulomatosis-with-polyangiitis-and-microscopic-polyangiitis-management-of-disease-resistant-to-initial-therapy> [accessed 29.01.21].
 - Fernandes S, Teixeira C, Falcão LP, Costa AC, Raimundo M, Silva S, et al. Anca negative pauci-immune crescentic glomerulonephritis and mixed connective tissue disease: a case study. *J Bras Nefrol*. 2019;42:245–9, <http://dx.doi.org/10.1590/2175-8239-JBN-2019-0003>.
 - Sethi S, Zand L, De Vriese AS, Specks U, Vrana JA, Kanwar S, et al. Complement activation in pauci-immune necrotizing and crescentic glomerulonephritis: results of a proteomic analysis. *Nephrol Dial Transplant*. 2017;32:i139–45, <http://dx.doi.org/10.1093/ndt/gfw299>.
 - Lin L, Zhao L, Huo B, Zheng L, Yu R, Li W, et al. Membranous nephropathy and thymoma in a patient with ankylosing spondylitis: a case report. *Medicine (Baltimore)*. 2020;99:e20111, <http://dx.doi.org/10.1097/MD.00000000000020111>.
- Beyhan Güvercin^a, Kubra Kaynar^{a,*}, Hasibe Bilge Gür^b, Sevdegül Mungan^c, Emre Selim^b, Muammer Cansız^a, Şükrü Ulusoy^a
- ^a Faculty of Medicine, Department of Nephrology, Trabzon 61080, Turkey
^b Faculty of Medicine, Department of Internal Medicine, Trabzon 61080, Turkey
^c Faculty of Medicine, Department of Pathology, Trabzon 61080, Turkey
- * Corresponding author.
 E-mail address: kkaynar@yahoo.com (K. Kaynar).
<https://doi.org/10.1016/j.nefro.2021.01.012>
- 0211-6995/© 2021 Sociedad Española de Nefrología. Published by Elsevier España, S.L.U. This is an open access article under the CC BY-NC-ND license (<http://creativecommons.org/licenses/by-nc-nd/4.0/>).

Subcutaneous tocilizumab in chronic active humoral kidney graft rejection

Tocilizumab subcutáneo en rechazo humoral crónico activo sobre injerto renal

Dear Editor,

Almost 10% of kidney transplants present an episode of humoral rejection during its evolution,¹ which decreases long-term graft survival. There are several published tri-

als about the use of tocilizumab (TCZ) in patients with chronic active humoral rejection as first line therapy and rescue treatment, with good results in graft survival.² The experience thus far has supported intravenous TCZ, so we present a case with administration of subcutaneous TCZ.

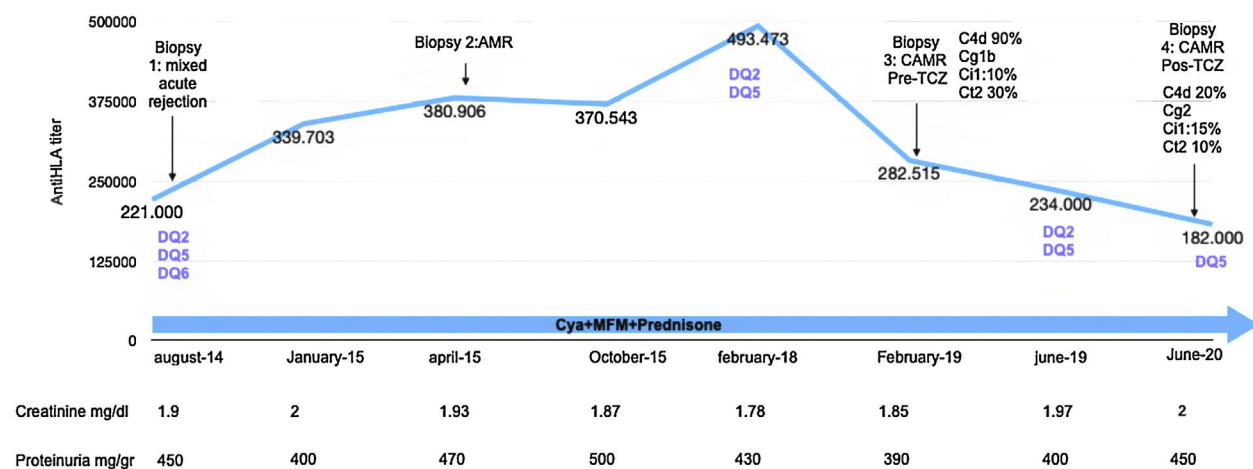


Fig. 1 – Follow-up renal function, proteinuria and histologic findings. AMR: antibody mediated rejection; CAMR: chronic active antibody mediated rejection; Cya: ciclosporin; MFM: mycophenolate mofetil; Cg: transplant glomerulopathy; Ci: interstitial fibrosis; Ct; tubular atrophy; iIFTA: inflammation in areas of interstitial fibrosis/tubular atrophy.

A 25-year-old man with a history of chronic renal disease due to Alport disease, who was in peritoneal dialysis for two years, received a kidney transplant from a living donor in June 2013, with 1 HLA matched (A) and no previous antibodies.

In 2014, the patient developed three de novo donor specific antibodies (DSA). Kidney graft biopsy was performed which showed acute mixed cellular and humoral rejection of renal allograft, treated with a bolus of corticosteroids, plasmapheresis, intravenous immunoglobulin (IVIg) and a cycle of bortezomib.

Eight months later he developed increased antibodies titres. Therefore, a new kidney graft biopsy was performed, showing active humoral rejection that was treated again with IVIg and a second cycle of bortezomib.

In February 2018, DSA DQ6 was no longer detected and in February 2019, a kidney biopsy was performed, confirming a diagnosis of chronic active humoral rejection. He was then started on treatment with IV TCZ (8 mg/kg/monthly). After 12 months (March 2020) of treatment due to the needs of COVID-19 pandemic, the route of administration was changed to subcutaneous (dose 162 mg/weekly).

Histologic control was performed 16 months after the start of treatment (June 2020), showing significant improvement in C4d deposits, reduction in inflammation in areas of interstitial fibrosis/tubular atrophy (IFTA), progression of transplant glomerulopathy and disappearance of DSA DQ2.

At the present moment, he continues treatment with SC TCZ weekly with good tolerance and without complications. During the entire follow-up, he has presented stable kidney renal function and proteinuria of less than 500 mg/g (Fig. 1).

Intravenous TCZ was approved for use in the European Union (EU) in 2009 to treat rheumatoid arthritis (RA) and juvenile idiopathic arthritis.³

In October 2013, US FDA approved a subcutaneous formulation of TCZ for use in RA based on two trials: BREVACTA,³ which compared the subcutaneous TCZ with placebo without differences in articular response at week 24 and with similar adverse reactions, and SUMMACTA⁴ which showed no inferi-

ority of subcutaneous TCZ compared to the intravenous one, with similar safety profile, apart from more injection site reactions with SC TCZ.

Iwamoto et al.,⁵ evaluated a cohort of 58 patients with RA and concluded that after change in formulation from IV TCZ to SC TCZ, the joint response was maintained.

In kidney transplant, there is no data regarding the use of subcutaneous TCZ; nevertheless, based on the trials reported and the favourable outcome of our patient, we could consider this form of administration, a treatment option that benefits patients.

Conflict of interest

The authors declare that the research was conducted in the absence of any commercial or financial relationships that could be construed as a potential conflict of interest.

BIBLIOGRAFÍA

- Chehade H, Pascual M. The challenge of acute antibody-mediated rejection in kidney transplantation. *Transplantation*. 2016;100:264–5.
- Choi J, Aubert O, Vo A, Loupy A, Haas M, Puliya D, et al. Assessment of tocilizumab (anti-interleukin-6 receptor monoclonal) as a potential treatment for chronic antibody-mediated rejection and transplant glomerulopathy in HLA-sensitized renal allograft recipients. *Am J Transplant*. 2017;17:2381–9.
- Sheppard M, Laskou F, Stapleton P, Hadavi S, Dasgupta B. Tocilizumab (actemra). *Hum Vaccin Immunother*. 2017;13:1972–88.
- Burmester G, Rubbert-Roth A, Cantagrel A, Hall S, Leszczynski P, Feldman D, et al. A randomised, double-blind, parallel-group study of the safety and efficacy of subcutaneous tocilizumab versus intravenous tocilizumab in combination with traditional disease-modifying antirheumatic drugs in patients with moderate to severe rheumatoid arthritis (SUMMACTA study). *Ann Rheum Dis*. 2013;73:69–74.

5. Iwamoto N, Fukui S, Umeda M, Nishino A, Nakashima Y, Suzuki T, et al. Evaluation of switching from intravenous to subcutaneous formulation of tocilizumab in patients with rheumatoid arthritis. *Mod Rheumatol*. 2016;26:662-6.

Lina M. León Machado*, María O. López Oliva, Yanieli H. Hernandez Perdomo, Tamara Pérez, Elena González Garcia, Rafael Selgas Gutierrez, Carlos Jiménez Martín

Hospital Universitario La Paz, Madrid, Spain

* Corresponding author.

E-mail address: linamaria.leon@salud.madrid.org
(L.M. León Machado).

<https://doi.org/10.1016/j.nefro.2021.01.011>

0211-6995/© 2021 Sociedad Española de Nefrología. Published by Elsevier España, S.L.U. This is an open access article under the CC BY license (<http://creativecommons.org/licenses/by/4.0/>).