

Review

Effect of cilostazol on arteriovenous fistula in hemodialysis patients

Jae Wan Jeon^{a,b}, Hae Ri Kim^{a,b}, Eujin Lee^c, Jong In Lee^c, Young Rok Ham^{a,c},
Ki Ryang Na^{a,c}, Kang Wook Lee^{a,c}, Jwa-Jin Kim^a, Dae Eun Choi^{a,c,*}

^a Department of Internal Medicine, Chungnam National University School of Medicine, Daejeon, Republic of Korea

^b Department of Nephrology, Chungnam National University Sejong Hospital, Sejong, Republic of Korea

^c Department of Nephrology, Chungnam National University Hospital, Daejeon, Republic of Korea

ARTICLE INFO

Keywords:

Arteriovenous fistula
Cilostazol
Maturation failure

ABSTRACT

Background: The maturation and patency of permanent vascular access are critical in patients requiring hemodialysis. Although numerous trials have been attempted to achieve permanently patent vascular access, little have been noticeable. Cilostazol, a phosphodiesterase-3 inhibitor, has been shown to be effective in peripheral arterial disease including vascular injury-induced intimal hyperplasia. We therefore aimed to determine the effect of cilostazol on the patency and maturation of permanent vascular access.

Methods: This single-center, retrospective study included 194 patients who underwent arteriovenous fistula surgery to compare vascular complications between the cilostazol ($n = 107$) and control ($n = 87$) groups.

Results: The rate of vascular complications was lower in the cilostazol group than in the control group (36.4% vs. 51.7%; $p = 0.033$), including maturation failure (2.8% vs. 11.5%; $p = 0.016$). The rate of reoperation due to vascular injury after hemodialysis initiation following fistula maturation was also significantly lower in the cilostazol group than in the control group (7.5% vs. 28.7%; $p < 0.001$). However, there were no significant differences in the requirement for percutaneous transluminal angioplasty (PTA), rate of PTA, and the interval from arteriovenous fistula surgery to PTA between the cilostazol and control groups.

Conclusion: Cilostazol might be beneficial for the maturation of permanent vascular access in patients requiring hemodialysis.

© 2021 Sociedad Española de Nefrología. Published by Elsevier España, S.L.U. This is an open access article under the CC BY-NC-ND license (<http://creativecommons.org/licenses/by-nc-nd/4.0/>).

* Corresponding author.

E-mail address: daenii@cnu.ac.kr (D.E. Choi).

<https://doi.org/10.1016/j.nefro.2020.12.013>

0211-6995/© 2021 Sociedad Española de Nefrología. Published by Elsevier España, S.L.U. This is an open access article under the CC BY-NC-ND license (<http://creativecommons.org/licenses/by-nc-nd/4.0/>).

Efecto del cilostazol en una fístula arteriovenosa en pacientes en hemodiálisis

RESUMEN

Palabras clave:

Fístula arteriovenosa
Cilostazol
Fracaso de la maduración

Antecedentes: La maduración y la permeabilidad del acceso vascular permanente son fundamentales en los pacientes que requieren hemodiálisis. Aunque se han realizado numerosos ensayos para conseguir un acceso vascular permanentemente permeable, pocos han conseguido resultados destacables. El cilostazol, un inhibidor de la fosfodiesterasa 3, ha demostrado ser eficaz en la enfermedad arterial periférica, incluida la hiperplasia intimal inducida por lesiones vasculares. Por lo tanto, nuestro objetivo era determinar el efecto del cilostazol en la permeabilidad y la maduración del acceso vascular permanente.

Métodos: Este estudio unicéntrico y retrospectivo incluyó 194 pacientes sometidos a una cirugía de fístula arteriovenosa para comparar las complicaciones vasculares entre los grupos de cilostazol ($n = 107$) y de control ($n = 87$).

Resultados: La tasa de complicaciones vasculares fue menor en el grupo de cilostazol que en el grupo de control (36,4% frente a 51,7%; $p = 0,033$), incluido el fracaso de la maduración (2,8% frente a 11,5%; $p = 0,016$). La tasa de reintervención por lesión vascular tras el inicio de la hemodiálisis después de la maduración de la fístula también fue significativamente menor en el grupo de cilostazol que en el grupo de control (7,5% frente a 28,7%; $p < 0,001$). Sin embargo, no hubo diferencias significativas en la necesidad de angioplastia transluminal percutánea (ATP), la tasa de ATP y el intervalo desde la cirugía de la fístula arteriovenosa hasta la ATP entre los grupos de cilostazol y de control.

Conclusión: El cilostazol podría ser beneficioso para la maduración del acceso vascular permanente en pacientes que necesitan hemodiálisis.

© 2021 Sociedad Española de Nefrología. Publicado por Elsevier España, S.L.U. Este es un artículo Open Access bajo la licencia CC BY-NC-ND (<http://creativecommons.org/licenses/by-nc-nd/4.0/>).

Introduction

The growth in the number of patients with end-stage renal disease (ESRD) is continuing at a higher rate than the increase in general population, with a consequent increase in the number of patients receiving hemodialysis. At the end of 2017, the number of patients receiving renal replacement therapy in Korea was 98 746, with 73 059 (73.9%) of those receiving hemodialysis.¹ This rise in hemodialysis patients is considered to be due to an increase not only in the elderly population but also in those with chronic illnesses such as diabetes and hypertension. Indeed, more than two-thirds of ESRD cases are attributed to chronic diseases such as diabetes and hypertension.

Permanent vascular access is important in patients requiring hemodialysis. Unfortunately, maturation failure, which occurs in 30%–55% of patients undergoing arteriovenous fistula (AVF) surgery for hemodialysis, hinders the utility of AVF.^{2–4} Delayed complications of mature fistulas result in reinterventions and hospital admissions as well as a one-year fistula failure rate of 30%–40%.^{4–8}

Intimal hyperplasia (IH) is a vasculopathy characterized by the differentiation of smooth muscle cells that form a multilayer compartment in the tunica intima of blood vessels. Direct endothelial damage is the most important cause of IH in coronary artery disease and peripheral arterial disease.^{9–11} Conversely, both direct vascular damage due to hypertension and indirect vascular injury due to uremia, anemia, or chronic inflammation are responsible for IH in chronic kidney

disease.¹² The effects of cilostazol on direct vascular injury-induced IH have been previously demonstrated,^{9–11} whereas the impact of cilostazol on indirect vascular injury-induced IH in patients with chronic kidney disease remains unclear.¹² In the present retrospective study, we tested the hypothesis that cilostazol might improve the maturation rate and durability of vascular access for hemodialysis.

Materials and methods

Study population

This single-center, retrospective study was approved by the institutional review board of Chungnam National University Hospital (IRB No. 2019-05-039) and included patients undergoing AVF surgery between January 2012 and June 2018 at Chungnam National University Hospital in Daejeon, South Korea.

Patients fulfilling the following criteria were included in the study: (1) more than two months of treatment with cilostazol, (2) hemodialysis initiation at Chungnam National University Hospital, (3) AVF surgery performed at Chungnam National University Hospital, (4) age of more than 18 years, (5) post-AVF surgery follow-up of six months or more, and (6) hemodialysis for more than six months. The exclusion criteria were (1) discontinuation of hemodialysis due to improvement in acute kidney injury within six months after the initiation of hemodialysis, (2) no initiation of hemodialysis within six

months after AVF surgery, (3) less than two months of treatment with cilostazol, and (4) previous AVF surgery.

Forty-three patients received hemodialysis prior to 2012 and underwent reoperation at the study hospital between January 2012 and June 2018, whereas 95 patients were followed in our clinic for less than six months after surgery. Ten patients treated with cilostazol for less than two months were excluded from the study. Of a total of 348 patients, 194 and 154 patients underwent AVF and arteriovenous graft (AVG) surgery, respectively, and the present study included 194 patients who underwent AVF surgery.

Measurements and definitions

The medical records of patients were reviewed to collect data on age, sex, underlying diseases, cause of ESRD (e.g., diabetes mellitus, hypertension, glomerulonephritis, other), follow-up duration, date of hemodialysis initiation, date of AVF surgery, whether treatment with cilostazol, duration of cilostazol treatment, treatment with other anticoagulants (aspirin, clopidogrel, warfarin, sarpogrelate), presence of peripheral arterial disease, vascular complications (e.g., maturation failure, radiological and surgical interventions to maintain patency), number of percutaneous transluminal angioplasty (PTA) procedures, and interval from AVF surgery to PTA.

The cilostazol group included patients who started cilostazol treatment before or within three days after surgery and those who were treated with cilostazol for more than two months, whereas the control group included patients who were not treated with cilostazol within the period between six months before and after surgery. The study cohort of 194 patients who underwent AVF surgery included 107 and 87 patients in the cilostazol and control groups, respectively.

Vascular complications were defined as serious vascular access events and included maturation failure, PTA, and reoperation after fistula maturation. Maturation failure was defined as requirement for reoperation due to an AVF that could not be used clinically after surgery or one that required PTA. PTA was defined as the presence of stenosis or thrombosis of an AVF after surgery requiring intervention. Reoperation after fistula maturation was defined as the clinical necessity for a second AVF or AVG surgery in patients undergoing hemodialysis after the first AVF surgery.

Primary outcome was vascular complications, and secondary outcomes were number of PTA procedures and interval between PTA and vascular surgery (i.e., complication-free days).

Statistical analysis

Continuous variables were analyzed using Student's *t* test, and categorical variables were analyzed using Pearson's chi-square test. Continuous variables are reported as means with standard deviation, whereas discrete variables are reported as percentages (%). Differences in the duration of follow-up between the groups were evaluated using the Student's *t*-test. Survival analysis for vascular complication was performed by Kaplan–Meier curve analysis. All analyses were performed

using the SPSS statistics software version 20 (IBM, Armonk, NY, USA), and *p* values of less than 0.05 were considered to indicate statistical significance.

Results

The patient demographics were similar between the cilostazol and control groups (Table 1). Specifically, the mean ages of the cilostazol and control groups were 64.3 and 65.0 years, respectively, which was not significantly different ($p = 0.726$). Furthermore, there were no differences in comorbidities, other medications including antiplatelet agents and anticoagulation agents, and cause of ESRD between the two groups.

Table 2 shows the patient outcomes between the cilostazol and control groups. The vascular complications were significantly lower in the cilostazol group than in the control group (36.4% [$n = 39$] vs. 51.7% [$n = 45$]; odds ratio [OR] 0.535, 95% confidence interval [CI] 0.301–0.952, $p = 0.033$). The analysis of the vascular complications by subgroups revealed that the rate of maturation failure was significantly lower in the cilostazol group than in the control group (2.8% [$n = 3$] vs. 11.5% [$n = 10$], OR 0.222, 95% CI 0.059–0.834, $p = 0.016$) and that the number of patients undergoing hemodialysis for reoperation after fistula maturation was significantly lower in the cilostazol group than in the control group (7.5% [$n = 8$] vs. 28.7% [$n = 25$], OR 0.200, 95% CI 0.085–0.472, $p < 0.001$). The rate of radiological interventions (PTA) to maintain fistula patency was also lower in the cilostazol group than in the control group, although the difference was not statistically significant (35.5% [$n = 38$] vs. 44.8% [$n = 39$], OR 0.678, 95% CI 0.380–1.209, $p = 0.187$). Furthermore, the number of PTA procedures was not significantly different between the cilostazol (1.7 ± 1.1) and control (2.2 ± 2.0) groups ($p = 0.157$). Finally, there were no statistically significant differences the interval between AVF surgery and PTA between the two groups ($p = 0.300$). The incidence of vascular complication was a significant difference in maturation failure and reoperation after maturation, but there was no statistically significant difference in survival analysis (Fig. 1).

Of the 194 AVF surgical patients, 100 patients underwent radiocephalic (RC) fistula surgery, 93 patients underwent brachiocephalic (BC) fistula surgery, and 1 patient underwent brachio basilic fistula surgery. When comparing the cilostazol group and the control group in patients that underwent RC fistula surgery, vascular complications were significantly lower in the cilostazol group than in the control group (39.3% [$n = 22$] vs. 61.4% [$n = 27$], $p = 0.028$), and reoperation after fistula maturation was also significantly lower in the cilostazol group than in the control group (5.4% [$n = 3$] vs. 27.3% [$n = 12$], $p = 0.002$). The rates of maturation failure ($p = 0.249$) and PTA ($p = 0.081$) were not significantly different between the cilostazol group and the control group. When comparing the cilostazol group and control group in patients that underwent BC fistula surgery, there was no significant difference in the rate of vascular complications between the two groups (33.3% [$n = 17$] vs. 42.9% [$n = 19$], $p = 0.345$). However, the rates of maturation failure (2.0% [$n = 1$] vs. 14.3% [$n = 6$], $p = 0.043$) and reoperation after fistula maturation (9.8% [$n = 5$] vs. 31.0% [$n = 13$], $p = 0.010$) were significantly lower in the cilostazol group than in the control

Table 1 – Demographic and clinical characteristics of patients undergoing AVF surgery.

	Cilostazol group (n = 107)	Control group (n = 87)	p value
<i>Demographic characteristics</i>			
Male	79 (73.8%)	60 (69.0%)	0.455
Age (years)	64.3 ± 12.3	65.0 ± 12.6	0.726
Death	12 (11.2%)	13 (14.9%)	0.441
Follow-up duration (days)	704.1 ± 458.0	940.9 ± 575.1	0.002
<i>Antiplatelet/anticoagulant agents</i>			
Aspirin	26 (24.3%)	21 (24.1%)	0.979
Clopidogrel	21 (19.6%)	27 (31.0%)	0.067
Warfarin	2 (1.9%)	1 (1.1%)	0.686
Sarpogrelate	9 (8.4%)	6 (6.9%)	0.694
<i>Comorbidity</i>			
Diabetes	77 (72.0%)	64 (73.6%)	0.803
Hypertension	92 (86.0%)	68 (78.2%)	0.154
GN	9 (8.4%)	10 (11.5%)	0.472
PAD	10 (9.3%)	12 (13.8%)	0.331
PAD with PTA	6 (5.6%)	10 (11.5%)	0.138
CAD	33 (30.8%)	31 (28.7%)	0.480
HF	29 (27.1%)	24 (27.6%)	0.940
A.fib/A.flutter	9 (8.4%)	8 (7.6%)	0.848
CVA	30 (28.0%)	34 (39.1%)	0.104
<i>Cause of ESRD</i>			
Diabetes	74 (69.2%)	57 (65.5%)	0.686
Hypertension	22 (20.6%)	16 (18.4%)	
GN	6 (5.6%)	8 (9.2%)	
Others	5 (4.7%)	6 (6.9%)	

Afib, atrial fibrillation; A. flutter, atrial flutter; CAD, coronary artery disease; CVA, cerebrovascular accident; GN, glomerulonephritis; HF, heart failure (ejection fraction < 50%); PAD, peripheral artery disease; PTA, percutaneous transluminal angioplasty.

Table 2 – Comparison of vascular complications following AVF surgery between the cilostazol and control groups.

	Cilostazol group (n = 107)	Control group (n = 87)	p value
Vascular complications	39 (36.4%)	45 (51.7%)	0.033
Maturation failure	3 (2.8%)	10 (11.5%)	0.016
Reoperation after maturation	8 (7.5%)	25 (28.7%)	<0.001
PTA (radiological interventions) after maturation	38 (35.5%)	39 (44.8%)	0.187
Number of PTA procedures	1.7 ± 1.1	2.2 ± 2.0	0.157
Interval between first PTA and vascular surgery (days)	337.4 ± 394.7	450.9 ± 543.2	0.300

PTA, percutaneous transluminal angioplasty.

group. The rate of PTA to maintain fistula patency was not significantly different between the two groups ($p = 0.840$) (Table 3).

Discussion

The present single-center, retrospective study was designed to evaluate the potential benefit of cilostazol in patients with hemodialysis access. Several common mechanisms underlie the pathophysiology of AVF maturation failure and vascular complications for all vascular access types, particularly those involved in neointimal hyperplasia.¹⁷⁻²⁰ Studies have consistently demonstrated that changes in the extracellular matrix, which occur early during vascular remodeling, can lead to failed fistula dilation and subsequent stenosis and thrombosis of the access point. A large randomized controlled trial has demonstrated that thrombosis plays only a limited role

in failed fistula maturation and vascular remodeling and that IH is a more prominent mechanism.¹⁷

The pathophysiology of IH is complex, but one central hemodynamic-related mechanism involves the upregulation of mitogen-activated protein kinases.¹⁸ Experimental studies suggest that this pathway may be controlled by cilostazol,¹⁹⁻²¹ a phosphodiesterase (PDE)-3 inhibitor that is used for the treatment of intermittent claudication.^{13,15,16,22-24} PDE-3A and PDE-3B are two members of the PDE-3 enzyme family. PDE-3A is expressed in platelets, vascular smooth muscle cells, and cardiomyocytes, whereas PDE-3B is found in adipocytes, hepatocytes, pancreatic β -cells, and macrophages.^{14,25} Therefore, the pharmacological effects of cilostazol include vasodilation, inhibition of platelet activation and aggregation, inhibition of thrombosis, increased blood flow to extremities, improvement in serum lipids, and inhibition of vascular smooth muscle cell growth; these effects of cilostazol contribute to the reduction

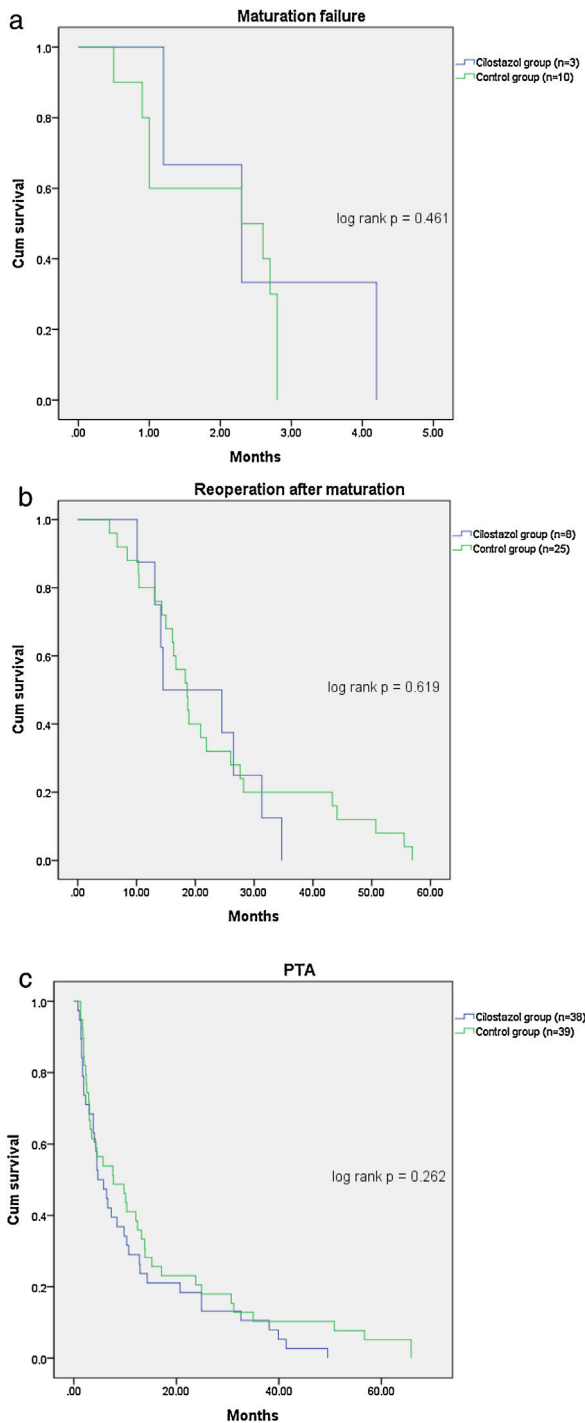


Fig. 1 – AVF survival curves for patients the cilostazol group versus control group. (a) Maturation failure; (b) reoperation after maturation; (c): PTA. PTA, percutaneous transluminal angioplasty.

of AVF maturation failure.¹⁷ The use of cilostazol after vascular surgery may reduce the incidence of maturation failure and subsequent intervention or reoperation by influencing vascular remodeling, in agreement with the results of the present study.¹⁷

The main finding of the present study was the reduction in vascular complications among hemodialysis patients treated with cilostazol. Specifically, the incidence of maturation failure was significantly lower in the cilostazol-treated patients who underwent hemodialysis without maturation failure after vascular surgery. Additionally, the incidence of reoperation was also significantly lower in the patients treated with cilostazol. However, there was no significant difference in vascular complication in survival analysis using Kaplan-Meier curve analysis. It is thought that maturation failure was mostly determined within 2 months after surgery, so it seems that there was no difference in the time factor.

When comparing the vascular complications according to the fistula location, patients that underwent RC fistula surgery experienced fewer vascular complications when taking cilostazol. The analysis of the vascular complications by subgroups revealed that the rate of reoperation after fistula maturation was significantly lower in the cilostazol group than in the control group. However, there were no significant differences in the rates of maturation failure and PTA between the cilostazol and control groups. Patients that underwent BC fistula surgery did not experience fewer vascular complications when taking cilostazol. However, the analysis of the vascular complications by subgroups revealed that the rates of maturation failure and reoperation were significantly lower in the cilostazol group than in the control group. The rate of PTA was not significantly different between the two groups in patients that underwent BC fistula surgery. When cilostazol was administered, the rate of reoperation after fistula maturation was significantly lower in both RC fistula surgery and BC fistula surgery, the rate of maturation failure was significantly lower in BC fistula surgery, not RC fistula surgery. In our study, it is difficult to analyze the preoperative vein diameter because there was no measurement and vascular ultrasound reports, but in the previous study, the vein diameter was found to be an independent predictor of maturation.²⁶ Therefore, in patients that underwent RC fistula surgery, the vein diameter was generally smaller than in patients that underwent BC fistula surgery, so it is expected that these factors may have influenced maturation failure. Therefore, when the vein diameter is large, the effect of cilostazol can be more clearly evaluated, and when the vein diameter is small, it might be difficult to compare the effects of cilostazol because the vein diameter can be a risk factor for maturation failure. In patients that underwent BC fistula surgery, the rates of both maturation failure and reoperation were lower in the cilostazol group, although the rate of vascular complications was not different between the cilostazol group and the control group. In our study, vascular complications were defined as serious vascular access events, including maturation failure, PTA, and reoperation after fistula maturation. In patients who underwent BC fistula surgery, there was no difference in the rate of PTA between the cilostazol group and the control group, and this effect showed no difference in vascular complications.

As cilostazol is a PDE-3 inhibitor, it is expected to reduce the incidence of maturation failure and reoperation by inhibiting IH by reducing vascular smooth muscle cell growth after AVF surgery.^{9–11} However, if PTA is performed owing to stenosis or thrombosis of AVF after maturation, it may occur due

Table 3 – Comparison of vascular complications following AVF site between the cilostazol and control groups between the cilostazol and control groups.

	Radiocephalic fistula (n = 100)			Brachiocephalic fistula (n = 93)		
	Cilostazol group (n = 56)	Control group (n = 44)	p value	Cilostazol group (n = 51)	Control group (n = 42)	p value
Vascular complications	22 (39.3%)	27 (61.4%)	0.028	17 (33.3%)	18 (42.9%)	0.345
Maturation failure	2 (3.6%)	4 (9.1%)	0.401 ^a	1 (2.0%)	6 (14.3%)	0.043 ^a
Reoperation after maturation	3 (5.4%)	12 (27.3%)	0.002	5 (9.8%)	13 (31.0%)	0.010
PTA (radiological interventions) after maturation	22 (39.3%)	25 (56.8%)	0.081	16 (31.4%)	14 (33.3%)	0.840
Number of PTA procedures	1.6 ± 0.9	2.1 ± 1.4	0.107	1.9 ± 1.4	2.4 ± 2.7	0.533
Interval between first PTA and vascular surgery (days)	307.0 ± 421.4	512.1 ± 596.3	0.181	358.9 ± 362.1	230.9 ± 317.1	0.290

PTA, percutaneous transluminal angioplasty.
^a Using Fisher's exact test.

to mechanical trauma from venipuncture or shear stress due to turbulent blood flow rather than IH.^{27,28} Therefore, administration of cilostazol is considered to not have a significant influence on PTA.

The present study has several limitations that should be acknowledged. First, the patient population was relatively small in this single-institution study. However, the study cohort was larger than that of a previously published similar study.¹⁷ Additionally, between January 2012 and June 2018, only one surgeon performed AVF and AVG surgeries which might reduce bias due to differences in surgical skills among different surgeons. The present study did not reveal a difference in the number of PTA procedures between the cilostazol and control groups. Since vascular conditions that require PTA can cause endothelial damage and IH, cilostazol administration might affect the final number of patients undergoing PTA. However, the cilostazol and control groups did not exhibit differences in the efficacy of cilostazol after PTA in the present study and a future controlled study is warranted.

In conclusion, the present retrospective, single-surgeon, single-center study found that there were differences in vascular complications between the patients treated with cilostazol and those who were not administered cilostazol; however, a definitive conclusion requires a larger study cohort. Future well-designed prospective studies with larger populations are necessary to address these issues.

Conflict of interest

Authors declare no conflict of interest.

Acknowledgement

This research was supported by Basic Science Research Program through the National Research Foundation of Korea (NRF) funded by the Ministry of Education (NRF-2017R1D1A03035061).

REFERENCES

1. Current renal replacement therapy in Korea-Insan Memorial Dialysis Registry 2017. In: Annual meeting of KSN. 2018.
2. Dember LM, Beck GJ, Allon M, Delmez JA, Dixon BS, Greenberg A, et al. Effect of clopidogrel on early failure of arteriovenous fistulas for hemodialysis: a randomized controlled trial. *JAMA*. 2008;299:2164–71.
3. Feldman HI, Joffe M, Rosas SE, Burns JE, Knauss J, Brayman K. Predictors of successful arteriovenous fistula maturation. *Am J Kidney Dis*. 2003;42:1000–12.
4. Huijbregts HJT, Bots ML, Wittens CHA, Schrama YC, Moll FL, Blankestijn PJ, et al. Hemodialysis arteriovenous fistula patency revisited: results of a prospective, multicenter initiative. *Clin J Am Soc Nephrol*. 2008;3:714–9.
5. Allon M, Robbin ML. Increasing arteriovenous fistulas in hemodialysis patients: problems and solutions. *Kidney Int*. 2002;64:1109–24.
6. Lee T. Novel paradigms for dialysis vascular access: downstream vascular biology-is there a final common pathway? *Clin J Am Soc Nephrol*. 2013;8:2194–201.
7. Feldman HI, Held PJ, Hutchinson JT, Stoiber E, Hartigan MF, Berlin JA. Hemodialysis vascular access morbidity in the United States. *Kidney Int*. 1993;43:1091–6.
8. Brahmabhatt A, Remuzzi A, Franzoni M, Misra S. The molecular mechanisms of hemodialysis vascular access failure. *Kidney Int*. 2016;89:303–16.
9. Chitalia N, Ross L, Krishnamoorthy M, Kapustin A, Shanahan CM, Kaski JC, et al. Neointimal hyperplasia and calcification in medium sized arteries in adult patients with chronic kidney disease. *Semin Dial*. 2015;28:E35–40.
10. Kokubo T, Ishikawa N, Uchida H, Chasnoff SE, Xie X, Mathew S, et al. CKD accelerates development of neointimal hyperplasia in arteriovenous fistulas. *J Am Soc Nephrol*. 2009;20:1236–45.
11. Heinen Y, Stegemann E, Sansone R, Benedens K, Wagstaff R, Balzer J, et al. Local association between endothelial dysfunction and intimal hyperplasia: relevance in peripheral artery disease. *J Am Heart Assoc*. 2015;4:e001472.
12. Chancharoenthana W, Leelahavanichkul A, Taratummarat S, Wongphom J, Tiranathanagul K, Eiam-Ong S. Cilostazol attenuates intimal hyperplasia in a mouse model of chronic kidney disease. *PLoS One*. 2017;12:e0187872.

13. Russell TE, Kasper GC, Seiwert AJ, Comerota AJ, Lurie F. Cilostazol may improve maturation rates and durability of vascular access for hemodialysis. *Vasc Endovascular Surg*. 2017;51:120–4.
14. Gross P, Massy ZA, Henaut L, Boudot C, Cagnard J, March C, et al. Para-cresyl sulfate acutely impairs vascular reactivity and induces vascular remodeling. *J Cell Physiol*. 2015;230:2927–35.
15. Zhang Q, Huang Jh, Xia RP, Duan XH, Jiang YB, Jiang Q, et al. Suppression of experimental abdominal aortic aneurysm in a rat model by the phosphodiesterase 3 inhibitor cilostazol. *J Surg Res*. 2011;167:e385–93.
16. Begum N, Shen W, Manganiello V. Role of PDE3A in regulation of cell cycle progression in mouse vascular smooth muscle cells and oocytes: implications in cardiovascular diseases and infertility. *Curr Opin Pharmacol*. 2011;11:725–9.
17. Begum N, Hockman S, Manganiello VC. Phosphodiesterase 3A (PDE3A) deletion suppresses proliferation of cultured murine vascular smooth muscle cells (VSMCs) via inhibition of mitogen-activated protein kinase (MAPK) signaling and alterations in critical cell cycle regulatory proteins. *J Biol Chem*. 2011;286:26238–49.
18. Asal NJ, Wojciak KA. Effect of cilostazol in treating diabetes-associated microvascular complications. *Endocrine*. 2017;56:240–4.
19. Kimura Y, Tani T, Kanbe T, Watanabe K. Effect of cilostazol on platelet aggregation and experimental thrombosis. *Arzneimittelforschung*. 1985;35:1144–9.
20. Tanaka K, Gotoh F, Fukuuchi Y, Amano T, Uematsu D, Kawamura J, et al. Effects of a selective inhibitor of cyclic AMP phosphodiesterase on the pial microcirculation in feline cerebral ischemia. *Stroke*. 1989;20:668–73.
21. Shakur Y, Holst LS, Landstrom TR, Movsesian M, Degerman E, Manganiello V. Regulation and function of the cyclic nucleotide phosphodiesterase (PDE3) gene family. *Prog Nucleic Acid Res Mol Biol*. 2001;66:241–77.
22. Allon M, Litovsky S, Young CJ, Deierhoi MH, Goodman J, Hanaway M, et al. Medial fibrosis, vascular calcification, intimal hyperplasia, and arteriovenous fistula maturation. *Am J Kidney Dis*. 2011;58:437–43.
23. Remuzzi A, Bozzetto M. Biological and physical factors involved in the maturation of arteriovenous fistula for hemodialysis. *Cardiovasc Eng Technol*. 2017;8(September):273–9.
24. Remuzzi A, Bozzetto M, Brambilla P. Is shear stress the key factor for AVF maturation? *J Vasc Access*. 2017;18 March, Suppl. 1:10–4.
25. Abeles D, Kwei S, Stavakis G, Zhang Y, Wang ET, Garcia-Cardena G. Gene expression changes evoked in a venous segment exposed to arterial flow. *J Vasc Surg*. 2006;44:863–70.
26. Bashar K, Clarke-Moloney M, Burke PE, Kavanagh EG, Walsh SR. The role of venous diameter in predicting arteriovenous fistula maturation: when not to expect an AVF to mature according to pre-operative vein diameter measurements? A best evidence topic. *Int J Surg*. 2015;15:95–9.
27. Chang CJ, Ko PJ, Hsu LA, Ko YS, Ko YL, Chen CF, et al. Highly increased cell proliferation activity in the restenotic hemodialysis vascular access after percutaneous transluminal angioplasty: implication in prevention of restenosis. *Am J Kidney Dis*. 2004;43:74–84.
28. Quencer KB, Oklu R. Hemodialysis access thrombosis. *Cardiovasc Diagn Ther*. 2017;7 Suppl. 3:S299–308.