

Cobalamin disorder CblC presenting with hemolytic uremic syndrome and pulmonary hypertension

Aciduria metilmalónica con homocistinuria tipo CblC como causa de síndrome hemolítico urémico e hipertensión pulmonar

Dear Editor:

Combined homocystinuria and methylmalonic aciduria cbl-C type is an inborn error of metabolism of vitamin B12 that leads to increased levels of homocysteine and methylmalonic acid. The spectrum of clinical manifestations and disease severity is broad. Atypical hemolytic uremic syndrome (aHUS) and pulmonary hypertension can be the first manifestations of the disease.

We present a rare case of cbl-C, with aHUS, recurrent pulmonary edema and severe pulmonary hypertension (PAH): A 2-year-old boy was admitted to the Pediatric Intensive Care Unit (PICU) with severe hypertension and pulmonary edema, both attributed to renal failure due to aHUS. He had a history of chronic hemolytic anemia of unknown origin since the age of 15 months and aHUS of unknown etiology had been diagnosed a month earlier. Treatment with eculizumab (anti-C5 monoclonal antibody) had been administered,

Table 1 – Blood tests and laboratory findings during hospitalization.

	Admission	Day 7 (Start of hemodialysis)	Day 8	Day 14	Day 28	Day 41 (Death)
Hematocrit (%)	21.2	30.5	32.8	23.4	20.8	28.1
Hemoglobin (g/dL)	6.9	10.3	11.5	7.8	7.3	9.8
Platelets (UI × 10E9/L)	192,100	212,000	95,100	132,400	190,800	152,000
Leukocyte count (UI × 10E9/L)	7400	11,800	12,000	10,700	22,000	22,400
CRP (<0.5 mg/dL) (C Reactive protein)	<0.1	0.13	3	1	15.73	5.29
LDH (<615 UI/L) (Lactate deshydrogenase)	1083	1204			1011	1074
Blood urea (10–40 mg/dL)	69	163	57	25	18	52
Blood creatinine (0.26–0.77 mg/dL) (22.9–68 mol/L)	1.01	2.42	0.3	0.6	0.34	0.25
Urine methylmalonic acid (0.31–2.52 mmol/mol crea)			24.6			
Plasmatic Homocystein (4.45–12.42 μmol/L)				66.66	9.81	
Folic acid (4–19 ng/mL)			7	7		
Autoimmunity tests: pAnca, cANCA, Ab anti MB, Ab antinuclear, Ab antiDNA, Ab anticardiolipin				Negative		
Genetic tests for complement pathway defects: C3, C4 and CH50				Normal		

as primary aHUS had been suspected. Parents were a healthy couple from north Africa with a low level of consanguinity and had two other healthy children. During PICU admission, our patient presented with arterial hypertension requiring multiple drugs, recurrent episodes of pulmonary edema and progressive renal failure ensued requiring continuous venovenous hemofiltration on day 7. Serial echocardiographic studies demonstrated progressive pulmonary hypertension causing acute cor pulmonale. Pulmonary thromboembolism was ruled out by a thoracic CT scan. The diagnostic workup (Table 1) included a kidney biopsy that showed a thrombotic microangiopathy (TMA) (Fig. 1). A panel for autoimmune diseases was negative. The diagnostic workup for metabolic inborn errors of metabolism was compatible with homocystinuria and methylmalonic aciduria type cbl-C. Treatment with hydroxycobalamin, betaine and carnitine was started upon diagnosis (second week after admission). A genetic test confirmed the diagnosis, with homozygous mutation in the gene *MMACHC* of chromosome 1 (276G>A+276 G>A). The clinical course of pulmonary hypertension was unfavorable, unresponsive to multiple pulmonary vasodilators (nitric oxide, bosentan, sildenafil and iloprost) and continuous infusion of heparin. In the catheterization laboratory pulmonary pressure was suprasystemic. An atrial septostomy was performed as the patient had two episodes of cardiac arrest due to pulmonary hypertensive crisis. He died due to pulmonary hemorrhage a month after PICU admission in spite of receiving specific metabolic treatment.

This case is an atypical presentation of combined homocystinuria and methylmalonic aciduria type cbl-C, with

aHUS, severe pulmonary hypertension and recurrent pulmonary hemorrhage at 2 years of age, outcome was poor despite specific treatment provided. Combined homocystinuria and methylmalonic aciduria type cbl-C is the most common form of inborn errors of the metabolism of vitamin B12. There is a deficient transformation of cobalamine to adenosylcobalamin (AdoCbl) and methylcobalamine (MeCbl). Results in an accumulation of methylmalonic acid and homocysteine.¹

There is great variability in the clinical presentation of Cbl-C: growth retardation, microcephaly or dilated cardiomyopathy can be the first manifestations in the prenatal period. During the first years of life lethargy, hypotonia, neurological symptoms, ophthalmological disorders and aHUS can appear. During adulthood encephalopathy, neurological degeneration and thromboembolic events can also be found.^{2,3}

Homocysteine may cause endothelial injury in rats and pulmonary thromboembolism in mice.⁴ In humans, hyperhomocysteinemia is an established independent risk factor for myocardial infarction and stroke in adults,⁵ due to thromboembolic events.

In this case, a thrombotic microangiopathy was found in renal biopsy, which may have been caused by the endothelial damage induced by hyperhomocysteinemia. Throughout PICU admission, the patient presented overt pulmonary hypertension unresponsive to pulmonary vasodilators. Different degrees of PAH have been described in cblG and cblC with aHUS.^{4,6,7} In two cases a good outcome is described after receiving specific treatment (cblG and cblC), but in another case (cblC), the patient died and renal biopsy showed thrombi in arteriolar vessels. There is a published case series

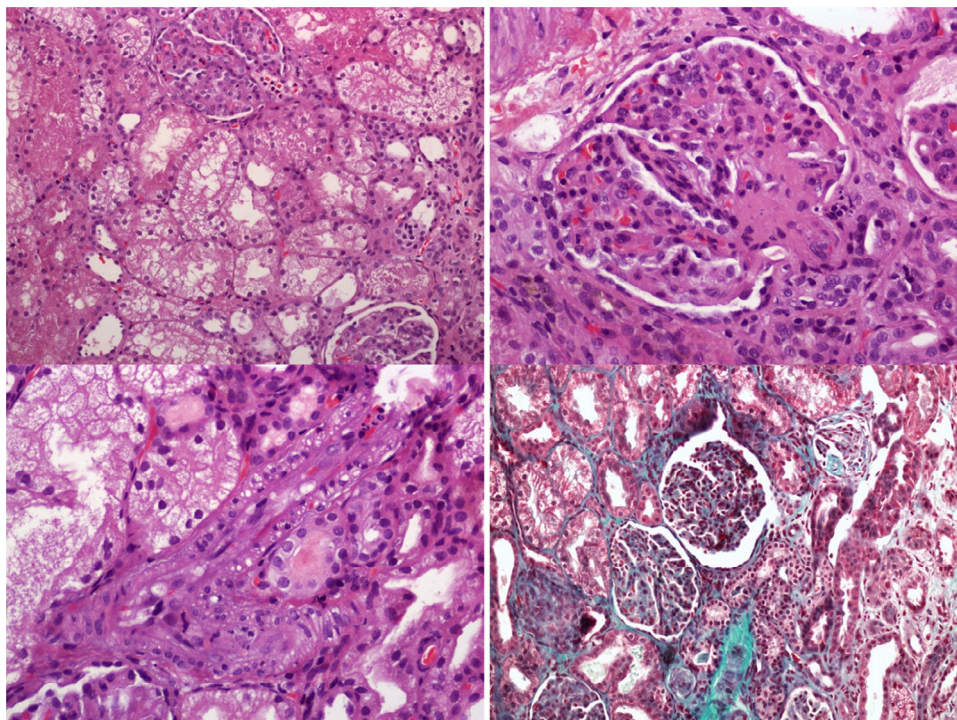


Fig. 1 – Renal biopsy: this specimen shows thrombotic microangiopathy, with membranoproliferative glomerular disease. The tubular epithelium shows generalized hydropic changes. Bleeding inside tubules is present.

of five patients⁸ with cblC and combined PAH/r-TMA: two are diagnosed postmortem and another two, despite aggressive treatment with PAH-targeted drugs and hydroxycobalamin, died of right ventricular failure and progressive pulmonary vasculopathy. Another case report⁹ presented reversible pulmonary arterial hypertension with treatment. There is a case report¹⁰ with cblC and isolated PAH with complete normalization of metabolic abnormalities with treatment. Despite this he died of fatal pulmonary hypertensive crisis.

We hypothesize that in our patient, suprasystemic pulmonary hypertension may have been caused by pulmonary microangiopathic events secondary to hyperhomocysteinemia and it remains speculative if the microvascular damage may have taken place at the postcapillary level justifying the recurrent pulmonary edema and pulmonary hemorrhage that our patient suffered. The outcome is poor when cblC is associated with HUS, with a high rate of mortality,³ especially if any type of dialysis is needed.

Our case is an unusual presentation of cblC with secondary aHUS, PHT, pulmonary edema and pulmonary hemorrhage. In this case rapid clinical worsening was observed in spite of the specific treatment, probably due to the advanced state of the disease and the severity of the pulmonary hypertension.

Homocysteine and methylmalonic acid measurement should be included in the workup of renal TMA and PAH in children. An early diagnosis and treatment may be useful to reverse PAH despite is not still demonstrated.

Funding source

No funding was secured for this study.

Financial disclosure

No financial relationships relevant to this article to disclose.

Conflicts of interest

The authors declare that they have no conflicts of interest.

Contributors' statements

Zuriñe Martínez de Compañón, Miriam Poblet-Puig and Griselda Vallès: We drafted the initial manuscript, changed some aspects after the review by the other authors and approved the final manuscript as submitted.

Mireia Del Toro, Ramón Vilalta and Antonio Moreno: They reviewed the manuscript each one the aspects of his speciality and approved the final manuscript as submitted.

Joan Balcells: He did the last review and approved the final manuscript as submitted.

All authors approved the final manuscript as submitted and agree to be accountable for all aspects of the work.

BIBLIOGRAFÍA

1. Shinawi M. Hyperhomocysteinemia and cobalamin disorders. *Mol Genet Metab*. 2007;90:113-21.
2. Carrillo-Carrasco N, Chandler RJ, Venditti CP. Combined methylmalonic academia and homocystinuria, cblC type I. Clinical presentations, diagnosis and management. *J Inher Metab Dis*. 2012;35:91-102.
3. Sharma AP, Greenberg CR, Prasad AN, Prasad C. Hemolytic uremic syndrome (HUS) secondary to cobalamin C (cblC) disorder. *Pediatr Nephrol*. 2007;22:2097-103.
4. Labrune P, Zittoun J, Duvaltier I, Trioche P, Marquet J, Niaudet P. Haemolytic uraemic syndrome and pulmonary hypertension in a patient with methionine synthase deficiency. *Eur J Pediatr*. 1999;158:734-9.
5. Bostom AG, Rosenberg IH, Silbershatz H, Jacques PF, Selhub J, D'Agostino RB. Nonfasting plasma total homocysteine levels and stroke incidence in elderly persons: the Framingham Study. *Ann Intern Med*. 1999;131:352-5.
6. Profitlich L, Kirmse B, Wasserstein MP, Diaz G, Srivastava S. Resolution of cor pulmonale after medical management in a patient with cblC-type methylmalonic aciduria and homocystinuria: a case report. *Cases J*. 2009;2:8603.
7. Brandstetter Y, Weinhouse E, Splaingard ML, Tang TT. Cor pulmonale as a complication of methylmalonic academia and homocystinuria (Cbl-C type). *Am J Med Genet*. 1990;36:167-71.
8. Kömhoff M, Roofthoof MT, Westra D, Teertstra TK, Losito A, Van de Kar NCAJ, et al. Combined pulmonary hypertension and renal thrombotic microangiopathy in cobalamin C deficiency. *Pediatrics*. 2013;132:540-4.
9. Gündüz M, Ekici F, Özaydin E, Ceylaner S, Perez B. Reversible pulmonary arterial hypertension in cobalamin-dependent cobalamin C disease due to a novel mutation in the MMACHC gene. *Eur J Pediatr*. 2014;173:1707-10.
10. Iodice FG, Chiara LD, Boenzi S, Aiello C, Monti L, Cogo P, et al. defect presenting with isolated pulmonary hypertension. *Pediatrics*. 2013;132:248-51.

Zuriñe Martínez de Compañón^{a,*}, Miriam Poblet-Puig^a, Griselda Vallès^a, Mireia Del Toro^b, Ramón Vilalta^c, Antonio Moreno^d, Joan Balcells^a

^a Department of Pediatric Critical Care, Hospital Universitari Vall d'Hebron, Universitat Autònoma de Barcelona, Spain

^b Department of Pediatric Neurology, Hospital Universitari Vall d'Hebron Barcelona, Spain

^c Department of Pediatric Nephrology, Hospital Universitari Vall d'Hebron Barcelona, Spain

^d Department of Pediatric Pneumology Hospital Universitari Vall d'Hebrón, Barcelona, Spain

*Corresponding author.

E-mail address: zmartine@vhebron.net

(Z. Martínez de Compañón).

0211-6995/© 2017 Sociedad Española de Nefrología. Published by Elsevier España, S.L.U. This is an open access article under the CC BY-NC-ND license (<http://creativecommons.org/licenses/by-nc-nd/4.0/>).

<https://doi.org/10.1016/j.nefro.2017.03.019>