

Rosa M. Ruiz-Calero*, Lilia M. Azevedo, Miguel A. Bayo, Boris Gonzales y Juan J. Cubero

Servicio de Nefrología, Hospital Infanta Cristina, Badajoz, España

* Autor para correspondencia.

Correos electrónicos: rosruizca@yahoo.com, rosruizca@gmail.com (R.M. Ruiz-Calero).

0211-6995/© 2016 Sociedad Española de Nefrología. Publicado por Elsevier España, S.L.U. Este es un artículo Open Access bajo la licencia CC BY-NC-ND (<http://creativecommons.org/licenses/by-nc-nd/4.0/>). <http://dx.doi.org/10.1016/j.nefro.2016.03.005>

Amyloid angiopathy in the context of hemodialysis: An unknown field

Angiopatía amiloide en el contexto de hemodiálisis: un terreno desconocido

Dear Editor:

It is known that cerebral amyloid angiopathy (CAA) is due to amyloid beta peptide ($A\beta$) accumulation in the middle and outer coats of small cerebral arteries and arterioles. CAA irrupts as a intracranial hemorrhage, which can be a cerebral hematoma or multifocal microhemorrhages. It is difficult to estimate its real incidence because diagnosis confirmation requires an anatomopathological study, but it is rated that almost 57% of non-traumatic intracranial hemorrhages in patients between 71 and 80 years old might be caused by CAA.¹ The spectrum of disease due to $A\beta$ includes several disorders. In 1985, $\beta 2$ microglobulin was identified as the responsible of hemodialysis-associated amyloidosis.² In the 1980 decade, CAA was considered an Alzheimer's disease subtype,^{3,4} and they have been proposed as different conditions since the 1990 early decade.⁵ Therefore, CAA is a disease with its own entity, but it lacks diagnosis, prevention and treatment protocols.

There is evidence that uremic environment and glomerular filtration rate decline in patients with chronic kidney disease, aggravate cognitive functions and are related to microhemorrhages occurrence.⁶ Both, it is necessary to clarify to what extent anticoagulant or antiplatelet treatments worsen CAA evolution. In this regard, it is interesting the case of an 82 years old patient with chronic kidney disease and hemodialysis for four years, who was evaluated due to a 48 hours disorientation state. His antecedents included memory impairment for nine years and an episode of multiple microangiopathic infarcts eight years ago. Non-contrast head CT showed a right frontal hematoma with perilesional edema, and hypodense lesions located in periventricular and subcortical white matter and left cerebellar hemisphere. That supported former infarcts or hemorrhages. According to the Boston criteria,⁷ the patient diagnosis was probable CAA.

The deficiency of standardized strategies to detect CAA and the bleeding risk that the disease entails, complicate the management of concomitant pathologies with antith-

rombotic therapy requirement. This is particularly important in patients under hemodialysis, who need anticoagulation treatment during sessions. In regard to antiplatelet treatment, retrospective researches show different outcomes respecting bleeding risk,⁸ although acetylsalicylic acid is generally avoided and replaced by clopidogrel. Anticoagulation with heparin is also controversial. On the one hand, a case report of CAA-related inflammation treated with enoxaparin 4000 IU/12 h due to venous thrombosis, described a subsequent big cerebral hematoma which caused death.⁹ On the other hand, low-molecular-weight heparin (LMWH) is recommended despite cerebral hemorrhage if immobilization extends beyond 3-4 days.¹⁰ In the exposed case of the patient, LMWH treatment was kept during hemodialysis sessions, and he continued his previous therapy with clopidogrel. Six days later, a control non-contrast head TC showed the resolution of acute hemorr-

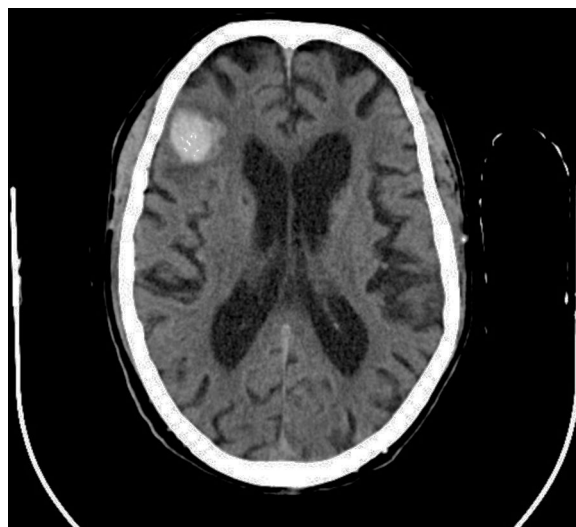


Fig. 1 Non-contrast head CT along hospitalization (September 2015).

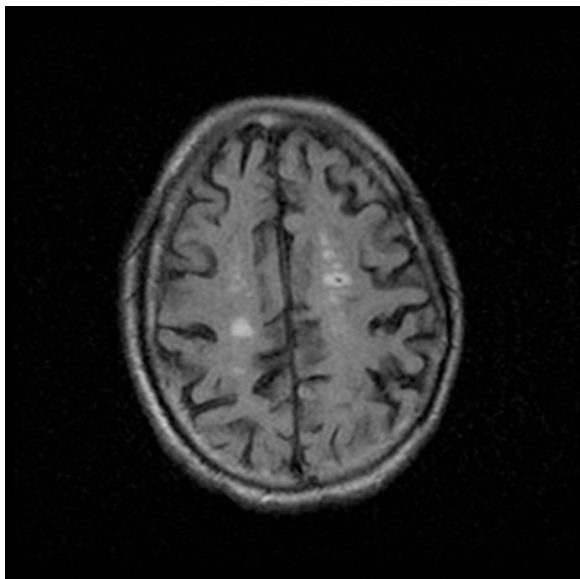


Fig. 2 FLAIR MRI (December 2011) which showed hyperintense lesions compatible with microhemorrhages.

hage, and due to the remarkable clinical improvement, the patient was discharged from the hospital showing a normal orientation state (Figs. 1 and 2).

Because of its significance for hemodialysis patients, CAA is an important disease in Nephrology sphere. It is already known the importance of controlling parameters like arterial pressure, anemia, or hydroelectrolytic equilibrium in those patients in order to prevent microhemorrhages onset. However, prospective researches should focus on the bleeding risk stratification in CAA patients undergoing hemodialysis, the impact of different antithrombotic treatments in those patients, and emphasize diagnostic methods for CAA, like gradient echo sequences MRI.

BIBLIOGRAFÍA

- Mehndiratta P, Manjila S, Ostergard T, Eisele S, Cohen ML, Sila C, et al. Cerebral amyloid angiopathy-associated intracerebral hemorrhage: pathology and management [Internet]. *Neurosurg Focus*. 2012;32(4):E7. <http://dx.doi.org/10.3171/2012.1.FOCUS11370> [cited 2015 Sept 29]. Available from: <http://www.ncbi.nlm.nih.gov/pubmed/?term=Cerebral+amyloid+angiopathy-associated+intracerebral+hemorrhage%3A+pathology+and+management>
- Gejyo F, Yamada T, Odani S, Nakagawa Y, Arakawa M, Kunitomo T, et al. A new form of amyloid protein associated with chronic hemodialysis was identified as beta 2-microglobulin [Internet]. *Biochem Biophys Res Commun*. 1985;129(3):701-6 [cited 2015 Sept 29]. Available from: <http://www.ncbi.nlm.nih.gov/pubmed/?term=A+new+form+of+amyloid+protein+associated+with+chronic+hemodialysis+was+identified+as+beta+2-microglobulin>
- Glenner GG, Henry JH, Fujihara S. Congophilic angiopathy in the pathogenesis of Alzheimer's degeneration [Internet]. *Ann*

- Pathol. 1981;1(2):120-9 [cited 2015 Sept 29]. Available from: <http://www.ncbi.nlm.nih.gov/pubmed/6169353>
- Chui HC. The significance of clinically defined subgroups of Alzheimer's disease [Internet]. *J Neural Transm Suppl*. 1987;24:57-68 [cited 2015 Sept 29]. Available from: <http://www.ncbi.nlm.nih.gov/pubmed/?term=The+significance+of+clinically+defined+subgroups+of+Alzheimer%2%B4s+disease>
- Vinters HV. Cerebral amyloid angiopathy and Alzheimer's disease: two entities or one? [Internet]. *J Neurol Sci*. 1992;112(1):1-3 [cited 2015 Sept 29]. Available from: <http://www.ncbi.nlm.nih.gov/pubmed/1469419>
- Li L, Fisher M, Lau W, Moradi H, Cheung A, Thai G, et al. Cerebral microbleeds and cognitive decline in a hemodialysis patient: case report and review of literature [Internet]. *Hemodial Int*. 2015;19(3):E1-7 [cited 2015 Sept 29]. Available from: <http://www.ncbi.nlm.nih.gov/pubmed/?term=Cerebral+microbleeds+and+cognitive+decline+in+a+hemodialysis+patient%3A+case+report+and+review+of+literature>
- Knudsen KA, Rosand J, Karluk D, Greenberg SM. Clinical diagnosis of cerebral amyloid angiopathy: validation of the Boston criteria [Internet]. *Neurology*. 2001;56(4):537-9 [cited 2015 Sept 29]. Available from: <http://www.ncbi.nlm.nih.gov/pubmed/11222803>
- Selim MH, Molina CA. Elderly and forgetful: is aspirin safe for you? [Internet]. *Stroke*. 2014;45(10):3153-4 [cited 2015 Sept 29]. Available from: <http://www.ncbi.nlm.nih.gov/pubmed/?term=Elderly+and+forgetful%3A+is+aspirin+safe+for+you%3F>
- Crosta F, Orlandi B, De Santis F, Passalacqua G, DiFrancesco JC, Piazza F, et al. Cerebral amyloid angiopathy-related inflammation: report of a case with very difficult therapeutic management [Internet]. *Case Rep Neurol Med*. 2015. <http://dx.doi.org/10.1155/2015/483020> [cited 2015 Sept 29]. Available from: <http://www.ncbi.nlm.nih.gov/pubmed/?term=Cerebral+amyloid+angiopathy-related+inflammation%3A+report+of+a+case+with+very+difficult+therapeutic+management>
- Escudero Augusto D, Marqués Álvarez L, Taboada Costa F. Actualización en hemorragia cerebral espontánea [Internet]. *Med Intensiva*. 2008;32(6):282-95 [cited 2015 Sept 29]. Available from: <http://www.ncbi.nlm.nih.gov/pubmed/18601836>

Carlos Jesús Cabezas-Reina^{a,*}, Elvira Esquivias-de-Motta^b, José Carlos Estévez-María^c, Marina Sánchez-Agesta-Martínez^d

^a Grado Medicina, Facultad de Medicina y Enfermería, UCO, Spain

^b Área de Nefrología, Hospital Universitario Reina Sofía, Córdoba, Spain

^c Área de Neurología, Hospital Universitario Reina Sofía, Córdoba, Spain

^d Residencia de Nefrología, Hospital Universitario Reina Sofía, Córdoba, Spain

* Corresponding author.

E-mail address: carlos.cabezas.14@outlook.com (C.J. Cabezas-Reina).

0211-6995/© 2016 Sociedad Española de Nefrología. Published by Elsevier España, S.L.U. This is an open access article under the CC BY-NC-ND license (<http://creativecommons.org/licenses/by-nc-nd/4.0/>). <http://dx.doi.org/10.1016/j.nefro.2016.03.007>