

The pros and cons of plasmapheresis therapy carried out on time

Nefrologia 2013;33(5):741-2

doi:10.3265/Nefrologia.pre2013.Jun.12061

To the Editor:

Apheresis is, in many cases, a first-line a therapeutic option that must be considered in the treatment of certain diseases.

The guidelines of the American Society for Apheresis establish the indications for therapeutic apheresis (TAP) and divide the different pathologies into categories in accordance with the efficacy demonstrated.^{1,2}

Although it is an extracorporeal blood purification technique used daily by nephrologists in dialysis, apheresis therapy is still an undervalued technique that is underutilised by our specialty, perhaps due to a lack of knowledge about its indications or its efficacy.

We present two clinical cases, occurring over the same period, of focal segmental glomerulosclerosis (FSGS) recurrence in renal grafts that demonstrate the pros and cons of plasmapheresis (PP) carried out on time in this type of pathology. In the first case, the patient started PP at the same time in which proteinuria reached nephrotic range, while in the second patient, TAP was performed more than six months later.

Our first patient is a 32-year-old woman with end-stage chronic renal failure (ESRF) secondary to FSGS on dialysis. She received a renal transplantation

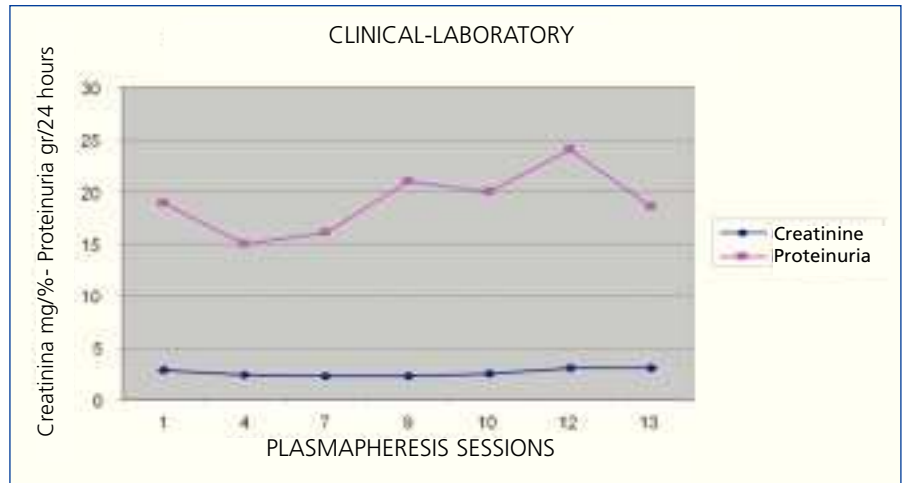


Figure 1. Case 2: progression over time of creatinine-proteinuria

with good progress, with creatinine of 1.2mg/dl and proteinuria of 0.3-0.4g/24 hours after three months. From this time, we observed a progressive increase in urine protein, despite intensifying treatment with angiotensin converting enzyme inhibitors/angiotensin receptor blockers, and she started PP after 5 months with proteinuria of 5g/24 hours and stable renal function. She underwent 1 session/48-72 hours, and we observed a progressive decrease in proteinuria. After 14 sessions, she displayed creatinine of 1.5mg/dl and proteinuria of 0.7g/24 hours. PP was therefore discontinued in order to assess stability. A month later, we again observed an increase in proteinuria to 2.9g/24 hours. We recommenced PP at that time and after three sessions proteinuria decreased to 0.8g/24 hours, with creatinine of 1.6mg/dl. We again had confirmation of a good response when we had to discontinue the session due to cytomegalovirus infection, with proteinuria increasing to 2.1g/24 hours and returning back to its stable state after we recommenced PP. Today, almost four years after transplantation, she is

asymptomatic with proteinuria of around 0.4-0.5g/24 hours and creatinine of 1.4mg/dl, with one PP session being conducted per month (Table 1).

Our second patient is a 55-year-old male, also affected by ESRF due to FSGS on dialysis. After transplantation, he showed good initial progress with creatinine of 1.4mg/dl. In the first weeks after transplantation, proteinuria remained around 0.5-0.6g/24 hours, and it was interpreted as having originated in the native kidneys because at the time of transplantation, the patient maintained some residual diuresis. Proteinuria gradually increased and after a month it reached nephrotic range at 5.1g/24 hours. As such, we decided to intensify treatment with dual blockade. Four months after transplantation proteinuria was 12g/24 hours and the patient experienced renal failure (creatinine 2.9mg/dl). Two months later, we decided to begin PP. A total of 13 sessions were carried out, 1 session/48-72 hours. Due to a lack of response, we decided to discontinue treatment (Figure 1).

Table 1. Case 1: progression over time of creatinine-proteinuria

PP session	1	4	10	14	15*	18	19**	25	32	38	42
Creatinine (mg/dl)	1.5	1.4	1.6	1.5	1.4	1.6	1.4	1.9	1.6	1.6	1.5
Proteinuria (g/24 hours)	5.1	2.8	1.7	0.7	2.9	0.8	2.1	0.4	0.5	0.6	0.5

PF: plasmaféresis.

It has been postulated that primary or idiopathic FSGS is due to a circulating factor present in plasma (glycoprotein), which increases glomerular permeability and induces protein loss.^{3,4} The justification for TAP is mainly based on the fact that PP has been shown to remove this glycoprotein with an improvement in proteinuria being observed.⁵

The purpose of this letter is to present to the largest group of medical professionals, mainly our fellow nephrologists, the efficacy of this technique in the treatment of various disorders, in this case the recurrence of FSGS in renal transplants. If we know its indications and advantages, we will be able to treat certain diseases on time, as in one of the cases that we presented.

Conflicts of interest

The authors declare that they have no conflicts of interest related to the contents of this article.

1. Szczepiorkowski ZM, Winters JL, Bandarenko N, Kim HC, Linenberger ML, Marques MB, et al.; Apheresis Applications Committee of the American Society for Apheresis. Guidelines on the use of therapeutic apheresis in clinical practice—evidence-based approach from the Apheresis Applications Committee of the American Society for Apheresis. *J Clin Apher* 2010;25(3):83-177.
2. Klein HG, Balow JE, Dau PC, Hamburger MI, Leitman SF, Pineda AA, et al. Clinical applications of therapeutic apheresis. Report of the Clinical Applications Committee, American Society for Apheresis. *J Clin Apher* 1986;3(1):i-vi,1-92.
3. Savin VJ, Sharma R, Sharma M, McCarthy ET, Swan SK, Ellis E, et al. Circulating factor associated with increase glomerular permeability to albumin in recurrent focal segmental glomerulosclerosis. *N Engl J Med* 1996;334:878-83.
4. Sharma M, Sharma R, McCarthy ET, Savin VJ. The FSGS factor: enrichment and in vivo effect of activity from focal segmental glomerulosclerosis plasma. *J Am Soc Nephrol* 1999;10:552-61.
5. Anaya F, Sánchez M, Pereda C, Rengel M, Ridao A, Valderrano F. Tratamiento con Aféresis Terapéutica en la recurrencia de la glomeruloesclerosis focal y segmentaria

en el trasplante renal. *Nefrología* 1999;XIX Suppl 2:94.

M. Jesús Izquierdo-Ortiz,
Verónica Mercado-Valdivia,
Vanesa Camarero-Temiño,
Badawi Hijazi-Prieto, Isabel Saiz-Calero,
M. Carmen Angola-Muquel,
Mercedes Muñoz-Merino,
Blanca Rodríguez-Velasco,
Pedro Abaigar-Luquin

Servicio de Nefrología.

Hospital Universitario de Burgos. (Spain)

Correspondence: M. Jesús Izquierdo-Ortiz
Servicio de Nefrología.

Hospital Universitario de Burgos. (Spain)

mjizquierdo3@hotmail.com

Infection due to *Pneumocystis jiroveci* in haemodialysis

Nefrología 2013;33(5):742-3

doi:10.3265/Nefrología.pre2013.Apr.12027

To the Editor:

Pneumocystis jiroveci pneumonia is a serious opportunistic infection that affects immunocompromised patients. It has been extensively described in the context of acquired immunodeficiency syndrome (AIDS), long-term steroid treatment and solid organ transplant recipients, mainly in the period covering the first six months after transplantation.

We report the case of a patient who, having recommenced haemodialysis after eight years with a functioning renal graft, developed progressive respiratory symptoms with bilateral pulmonary infiltrates, showing *Pneumocystis jiroveci* pneumonitis after recent hospitalisation due to graft pyelonephritis. The occurrence of this fungal infection is exceptional outside the first months following transplantation, but it may occur at any time during progression, and as such we must bear it in mind for its early diagnosis and treatment.

Our patient is a 66-year-old male, a former smoker, with long-term high blood pressure, systemic arteriosclerosis and intermittent claudication and he had a transient ischaemic episode in 1994. He has chronic kidney disease secondary to nephroangiosclerosis and has been on haemodialysis since August 2002 through an arteriovenous fistula in his left forearm.

He received a deceased donor renal transplant in November 2004, and achieved baseline creatinine of between 1.2 and 1.4 mg/dl. In August 2005, following a progressive decline in renal function, a renal biopsy was performed that showed an acute rejection grade IB with a good response to steroid therapy. He subsequently developed type 2 diabetes mellitus, requiring oral anti-diabetic medication (September 2008). In January 2012, he was diagnosed with a moderately differentiated adenocarcinoma of the lung in the upper right lobe; he underwent 3 chemotherapy and 33 radiotherapy sessions with a good response to treatment.

In September of the same year, he started to experience a deterioration in renal function and uraemia, accompanied by fever and pain in the area of the graft (left iliac fossa). He was admitted to the Nephrology department, where he was diagnosed with pyelonephritis due to *E. coli* sensitive to ciprofloxacin, for which he was treated for seven days. After recommencing haemodialysis, he was discharged on the third day to complete treatment at his home as an outpatient.

One week later, the patient came to the Emergency Department due to recurrence of symptoms. He was eupnoeic at rest, with normal colour and was well perfused and had a fever up to 38°C. Blood pressure was 150/80mmHg and was rhythmic at 108bpm. Cardiac auscultation revealed the presence of a systolic murmur. Pulmonary examination was unremarkable, without unusual sounds. Abdominal examination showed a soft and palpable abdomen, and there was pain in the left iliac fossa