

Two cases of glomerulonephritis in one patient infected with the hepatitis C virus

María Molina¹, Julián Sánchez², Ángel M. Sevillano¹, Ignacio Bengoa¹, Eduardo Gutiérrez¹, Miguel A. Martínez², Eduardo Hernández¹, Manuel Praga¹

¹ Servicio de Nefrología. Hospital 12 de Octubre. Madrid (Spain)

² Servicio de Anatomía Patológica. Hospital 12 de Octubre. Madrid (Spain)

Nefrología 2013;33(4):593-600

doi:10.3265/Nefrologia.pre2013.May.12067

ABSTRACT

Membranoproliferative glomerulonephritis (GN) may be pathogenically associated with infection due to the hepatitis C virus (HCV) as many clinical cases have shown. The potential relationship between the HCV and IgA GN, by contrast, has been suggested only in few cases. IgA nephropathy recurs in up to 50% of cases after renal transplantation, but it is uncommon for it to appear as a de novo GN. We report the case of a patient with chronic infection due to the HCV and liver disease, who developed two different glomerular diseases during its progression: membranoproliferative GN in his native kidneys, a process that caused terminal renal failure and de novo IgA GN in the transplanted kidney. The potential pathogenic relationship of both glomerular processes with infection due to the HCV is discussed.

Keywords: IgA glomerulonephritis. Kidney transplantation. Membranoproliferative glomerulonephritis. Recurrence. Transplantation. Hepatitis C virus.

Dos glomerulonefritis en un mismo paciente con infección por virus de la hepatitis C

RESUMEN

La glomerulonefritis (GN) membranoproliferativa puede asociarse patogénicamente con la infección por el virus de la hepatitis C (VHC), como numerosos casos clínicos han mostrado. La posible relación entre VHC y GN IgA, por el contrario, ha sido sugerida solamente en casos aislados. La nefropatía IgA recurre hasta en un 50 % de los casos tras el trasplante renal, pero es poco frecuente que aparezca como una GN de novo. Presentamos el caso de un paciente con infección crónica por VHC y hepatopatía, que desarrolla dos patologías glomerulares diferentes a lo largo de su evolución: GN membranoproliferativa en sus riñones nativos, proceso que causó una insuficiencia renal terminal, y GN IgA de novo en el riñón trasplantado. Se discute la posible relación patogénica de ambos procesos glomerulares con la infección por VHC.

Palabras clave: Glomerulonefritis IgA. Trasplante renal. Glomerulonefritis membranoproliferativa. Recurrencia. Trasplante. Virus de la hepatitis C.

INTRODUCTION

De novo glomerulonephritis (GN) is defined as a glomerular disease that appears after a renal transplantation has been performed and which is different from the primary renal disease. The most common *de novo* GN are membranous nephropathy, focal segmental glomerulosclerosis, membranoprolifera-

tive GN (MPGN) and thrombotic microangiopathy secondary to drug intake. Other forms, such as *de novo* IgA GN are uncommon.^{1,2}

In recent decades, cases of GN associated with the presence of the hepatitis C virus (HCV), mainly MPGN and membranous GN, have been described.²⁻⁶ The relationship between IgA GN and the aforementioned virus has recently been described.⁷⁻¹²

Below, we present the case of a patient who was HCV positive and who developed two different glomerular processes,

Correspondence: Eduardo Hernández

Servicio de Nefrología.

Hospital 12 de Octubre. Avda. de Andalucía, s/n. 28041 Madrid. (Spain).

mngmolina@hotmail.com

ehm3871@yahoo.es

clinical cases

María Molina et al. Two cases of glomerulonephritis in a patient with the HCV

one in his native kidneys and one in his renal transplant, both related to the aforementioned virus.^{2,7-13}

DISCUSSION OF THE CLINICAL CASE

A 56 year-old male with a personal history of alcoholic hepatitis, who in 1995 was admitted for a nephrotic syndrome, microhaematuria and renal failure (creatinine 1.5mg/dl) study. The physical examination revealed the presence of edemas, hepatomegaly and purpuric lesions on his lower limbs. The study (Table 1) showed a positive serology for the HCV, with the remaining serologies being negative. It also revealed positive cryoglobulin. A renal biopsy was performed, revealing a renal parenchyma with seven glomeruli with diffuse involvement, increased cellularity and a mesangial matrix with a lobular appearance, basement membranes with images of double contour, irregular thickening of the capillary walls and interstitial fibrosis. Direct immunofluorescence revealed C3 granular parietal glomerular deposits and the electron microscopy showed subendothelial deposits, swollen endothelial cells and mesangial expansion (Figure 1). The patient was diagnosed with MPGN associated with HCV with positive cryoglobulins.

The patient was referred to the Digestive Department to assess HCV treatment on a whole. A liver biopsy was performed, which revealed cirrhosis of the liver (P-3, L-2, F-3). Given these results, we started treatment with interferon alpha, initially without achieving a sustained viral response, and subsequently with its pegylated form for 48 weeks achieving a negative viral load. Four months after completion of treatment, he had an episode of acute pericarditis with presence of HCV in the pericardial fluid coinciding with a further increase in viral load. The patient had had poor clinical tolerance to both previous treatments and it was decided not to initiate further treatment. Another complication that he presented was inflammatory arthritis of his major joints.

From a renal perspective, antiproteinuric therapy was introduced with renin-angiotensin-aldosterone system blockade, despite which the patient developed progressive renal failure and finally began haemodialysis in 2007. In November 2009, he received his first kidney transplant from a donor who had died from spontaneous cerebral haemorrhage. The donor had HLA typing: DR1, DRX, B14, B35, A11, A30, and a positive history of alcoholism, with creatinine in the moment of removal of 1mg/dl and negative proteinuria. Immunosuppression was performed with corticosteroids, mycophenolic acid

Table 1. Biochemistry progression and complementary test

	April 1995 1st biopsy	November 2009 Renal transplant	February 2011 2nd biopsy	January 2013 Current situation
Creatinine (mg/dl)	1.5	1	0.8	1.2
Proteinuria (g/24 hours)	4.5-6.1		1.5	0.5
Urine sediment	Uncountable red blood cells		Red blood cell casts	
Albumin (g/dl)	2.8	3.3	4.2	3.9
Cholesterol (mg/dl)	182	122	175	160
Immunoglobulins (mg/dl)				
G	877	733	968	
A	394	511	676	
M	80	44	60	
C3				
(83-171mg/dl)	97	83	88	
C4				
(14-84mg/dl)	19	17	19	
RF (IU/ml)	161		84	
Autoimmunity	Normal		Normal	
Viral load quantified by HCV CRP (copies)		9,649	385,296	
Cryocrit (%)	2		1	

PCR: polymerase enzyme chain reaction; RF: Rheumatoid factor; VHC: hepatitis C virus.

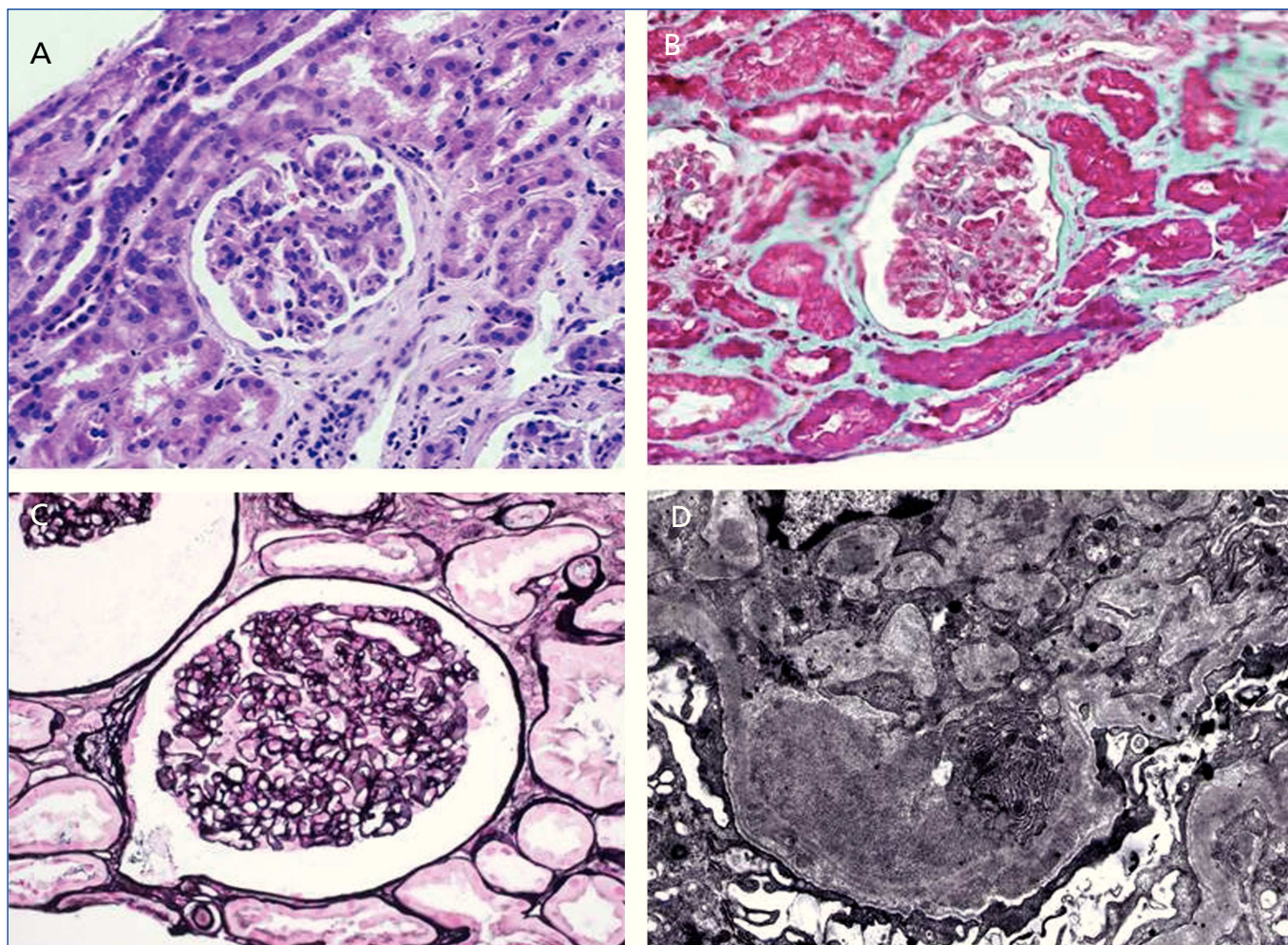


Figure 1. Native kidney biopsy.

A) Haematoxylin-eosin stain: glomerulus with increased cellularity and mesangial matrix with lobular appearance. B) Masson trichrome stain: interstitial fibrosis. C) Methenamine silver stain: glomerulus with double contour images. D) Electron microscopy: subendothelial deposits, swollen endothelial cells and mesangial expansion.

and tacrolimus. Renal progression was excellent and there was immediate renal function. Thirteen months after transplantation, the patient developed non-nephrotic proteinuria and microhaematuria with red blood cell casts, while maintaining normal renal function. An autoimmunity study was performed (Table 1); donor-specific antibodies, cytomegalovirus antigenaemia and serum PCR (polymerase enzyme chain reaction) levels for the BK virus were negative, and the renal Doppler ultrasound was normal. Given the suspected recurrence of the underlying disease, we opted for a renal biopsy. The optical microscopy showed a renal parenchyma with ten glomeruli with marked mesangial expansion, mild fibrosis and tubular atrophy. Immunofluorescence revealed granular mesangial IgA and C3 deposits, and electron microscopy showed mesangial expansion of cells and matrix with abundant homogeneous electron deposits. The C4d immunohistochemistry techniques were negative (Figure 2). The patient was diagnosed with *de novo* IgA

mesangial GN in the graft, and the dose of corticosteroids and mycophenolic acid were increased without clinical biochemical improvement. After the start of antiproteinuric treatment with blockade of the renin-angiotensin-aldosterone system by angiotensin receptor antagonist (ARA II) and the subsequent association of spironolactone, a negative proteinuria result was achieved, although with a small deterioration renal function that is currently stabilised (Figure 3).

DISCUSSION

De novo GN in the renal graft are defined as a glomerular disease that appears after a renal transplantation, which is different from the primary nephropathy and they are the third most common cause for loss of graft at 10 years after transplantation. Their prevalence in the publications is highly variable due to: the different criteria and protocol for carrying out

clinical cases

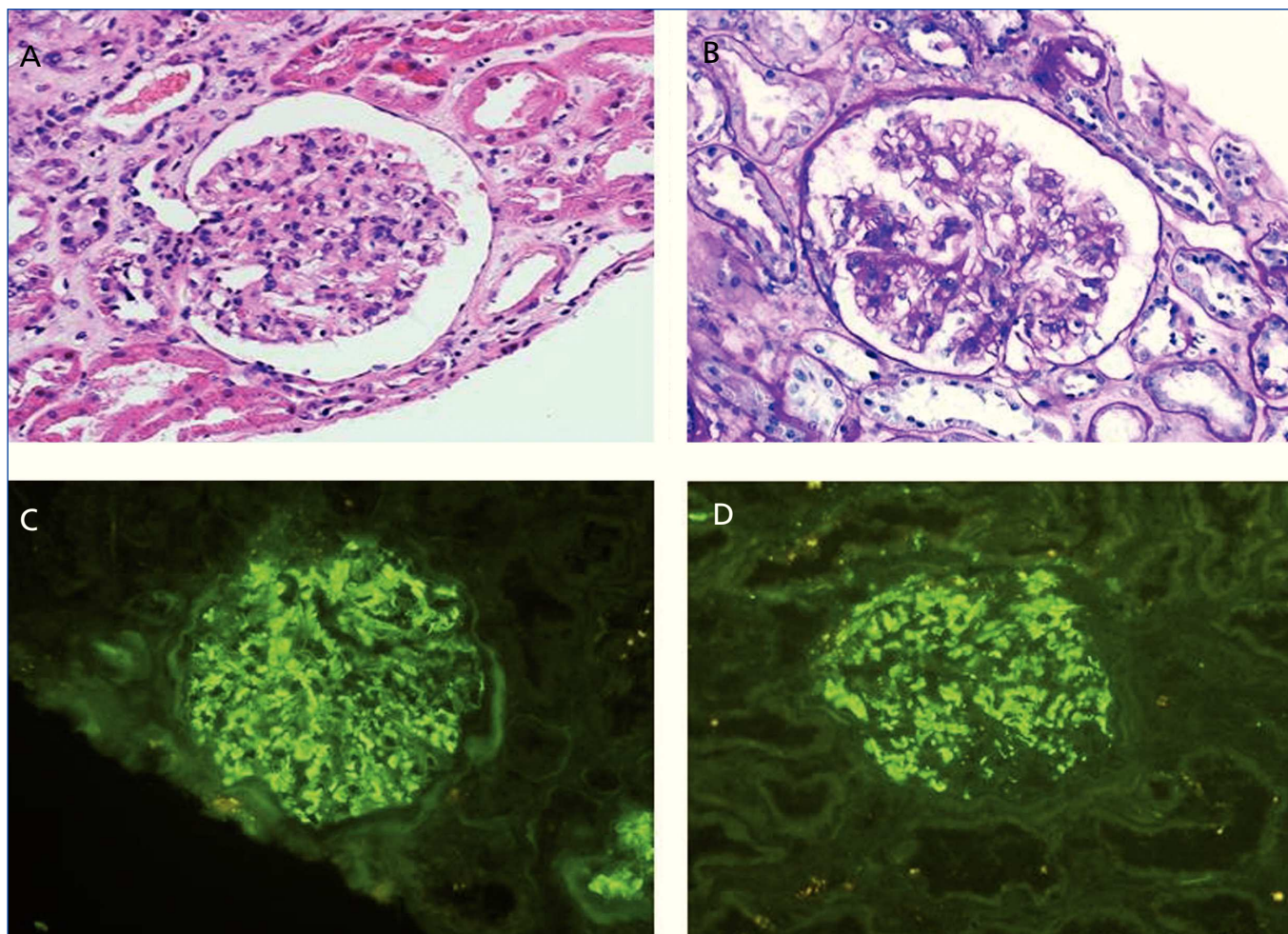


Figure 2. Biopsy of the renal transplant.

A) Haematoxylin-eosin stain: glomerulus with mesangial, cellular and matrix expansion and tubular atrophy. B) PAS (periodic acid Schiff) stain: glomerulus with increased mesangial matrix and cellularity. C) IgA immunofluorescence: positive granular deposits. D) C3 immunofluorescence: positive granular deposits.

renal biopsies, the fact that in some cases there is only optic microscopy without immunofluorescence or electron microscope, not being able to carry out the differential diagnosis safely with other forms of the disease, the total count of *de novo* GN and recurrences of the original disease and the presence of a renal disease of unknown origin. The most common forms are membranous nephropathy, focal segmental glomerulosclerosis, MPGN, thrombotic microangiopathy secondary to drug intake and nephritis due to basement membrane antibodies, associated with Alport's syndrome.^{1,2} The presence of *de novo* IgA GN is uncommon.¹⁴⁻¹⁹ With regard to the clinical course, *de novo* GN appear late, normally from one year after the transplantation, in contrast to recurrences, which usually appear in the first weeks after transplantation.¹ Graft survival, both in recurrences and in *de novo* GN is clearly lower than in patients who do not develop any glomerular process.²⁰

We report the case of a patient with nephrotic syndrome, in whose study we noted a positive serology for the HCV and positive cryoglobulins. The renal biopsy showed an MPGN associated with a chronic infection due to the HCV. This entity may appear in a primary form (idiopathic) or as secondary form to the deposit or in situ formation of immune complexes in the glomerulus, caused by diseases with chronic activation of the immune system (such as infections due to the hepatitis B and C viruses), autoimmune diseases, and the inability to remove immune complexes and some tumours.²¹

After receiving his first renal transplant, the patient displayed proteinuria and microhaematuria with red blood cell casts, and a recurrence of his baseline disease was initially suspected, which occurs in 20-30% of cases,^{1,2} but the histopathological study revealed the presence of a *de novo* IgA GN. The etiology of the second GN is uncertain. Initially, it could be

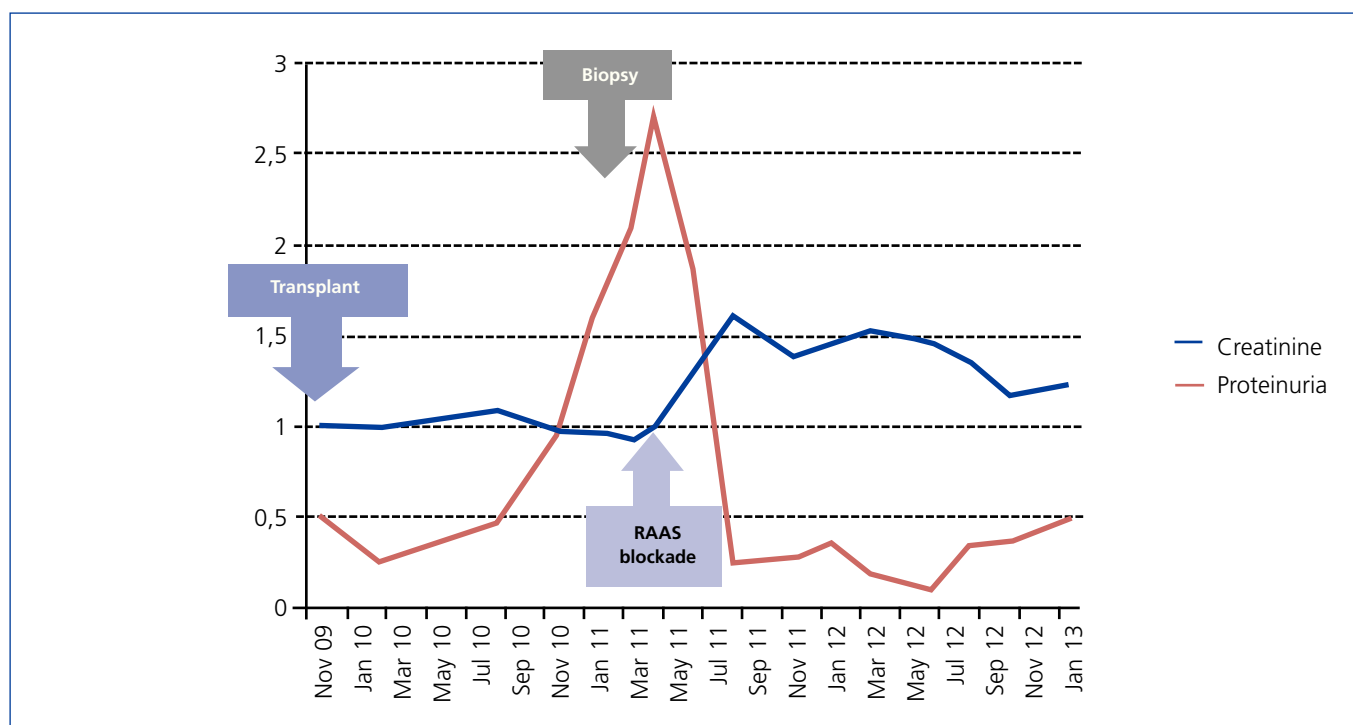


Figure 3. Progression of renal function and proteinuria. RAAS: renin-angiotensin-aldosterone system.

related to the presence of chronic liver disease in the recipient.¹³ The second possibility considered was the donor has a non-diagnosed IgA GN without proteinuria at the time of transplantation. The donor had a positive history of alcoholism and was a carrier of HLA-B35, which are factors associated with this glomerulopathy,^{13,22} although, we do not know if they had previously presented abnormalities in renal function or urinary sediment. No renal biopsy was carried out on the graft before the transplantation and the contralateral kidney was not transplanted because it carried a renal cyst. This possibility seems more remote to us, because reports in literature suggests that IgA deposits in the transplanted kidney disappear soon after transplantation.²³

The HCV is a small RNA virus (30-38nm) with a lipid envelope and it belongs to the *Flaviviridae* family. This virus may result in the appearance of some renal diseases. Furthermore, renal disease patients have a higher risk of becoming infected by the HCV because they have greater direct or indirect contact with blood from other patients (transfusions, haemodialysis, transplantations). In haemodialysis centres in the United States, a prevalence of 8-10% of patients infected by HCV and an incidence of 1-3% new cases per year has been described. It has been related to different renal diseases, however, the most common are type I MPGN, which is associated with type II mixed cryoglobulinaemia and to a lesser extent, non-cryoglobulinaemic MPGN and membranous GN. Small series and isolated cases have also been described that

associate infection due to HCV with other processes, both glomerular (focal and segmental glomerulosclerosis, immunotactoid and fibrillary glomerulopathy, acute post-infectious GN and IgA GN⁷⁻¹²) and non-glomerular (tubulointerstitial nephritis and thrombotic microangiopathy).^{3,11}

This history may suggest that both glomerular processes in our patient are associated with infection due to HCV. In the first GN, MPGN, the association with the virus is well documented and supported by many epidemiological studies, clinical cases, trials and experimental work.^{3,24} The relationship between the HCV and the second glomerular process, *de novo* IgA GN, is less common. At the start of the 1990s, the link between the HCV and this GN was not known, although the link between chronic liver disease and alcoholic liver disease was known.^{25,26} However, over the years, isolated cases⁷⁻¹⁰ and series of cases¹¹ of IgA GN in native kidneys have been described. There are also cases of patients with IgA GN and liver disease in whom, after completing the antiviral treatment with interferon and ribavirin and achieving a sustained viral response, the liver profile and the urinary sediment normalised.^{7,27} The prevalence of IgA GN in HCV patients varies between 0% and 6% according to the series, although in other geographical regions such as Saudi Arabia or Japan, there are greater frequencies.^{10,11,28} Sansonno et al. have confirmed the presence of viral RNA in the glomeruli and viral core particles both in glomeruli and tubules of IgA patients, although in a lower percentage than in other glomerulopathies such as

clinical cases

María Molina et al. Two cases of glomerulonephritis in a patient with the HCV

MPGN and membranous GN. These data suggest that the HCV has a role in the pathogenesis of IgA GN in these patients.²⁹

Various renal diseases have been described in patients who have the HCV after receiving a renal transplant (MPGN, membranous GN, minimal change disease, thrombotic microangiopathy, acute rejection, chronic rejection). With regard to *de novo* GN, the HCV was associated with membranous GN and MPGN.³⁻⁵ Its potential etiological role in *de novo* IgA GN is unknown. We displayed the cases described in literature of IgA GN, along with their progression in Table 2. There is a notable case described by Francisco et al. of a black patient with non-biopsied chronic kidney disease attributed to nephroangiosclerosis with high blood pressure

but without haematuria. The patient acquired the infection due to the HCV after receiving various transfusions when he was on renal replacement therapy, in the form of haemodialysis, developing chronic liver disease. He received a renal graft from a deceased donor. A renal biopsy was carried out two weeks after the transplant, and it displayed an acute rejection without lesions or deposits suggestive of IgA GN. After three years, he developed non-nephrotic range proteinuria, and a renal biopsy was done with diagnosis of IgA GN.¹⁵ In the other cases of *de novo* IgA GN described, we do not have recipients' HCV serology data. In our case, the diagnosis of *de novo* IgA coincides with an increase in the HCV viral load, which indicates active RNA replication. This, along with the effect of immunosuppression and the virus itself could modulate the response of lymphocytes and

Table 2. Review of the cases of *de novo* IgA glomerulonephritis in patients with renal transplants

Publication	Patient	Time until diagnosis Clinical presentation	Treatment	Progression
Francisco et al. ¹⁵	Male 59	3 years		Progressive deterioration of renal function (Cr 1.6 → 2.7) with persistent proteinuria
	Black	NN prot		
	HBP			
	HCV +			
	CRF: NAS			
Tang et al. ¹⁹	Male 32	6 years	i.v. CS	Return to HD
	CRF: type I MPGN ^a	NN prot, RFD and HM	AZA → MPA	in 6 months
	Woman 69	7 years	i.v. CS	Graft working
	CRF: Vasculitis ^a	NN prot, RFD and HM	CyA → FK	after 3 years Cr 2.5
	Woman 45	4,5 years	CC i.v.	Return to HD in
	HBP	Nephritic syndrome	CyA → FK	8 months
	CRF: RPD ^a			
Kowalewska et al. ¹⁸	Male 59	3 years	i.v. CS	Return to HD
	CRF: PIGN	RFD and HBP		in 2 months
	Male 37	5 years	o.r. CS	Graft working
	CRF: VUR	NN prot, RFD and HM		after 6 years Cr 1.7
Robles et al. ¹⁴	Male 18	0.5 years	i.v. CS	Return to HD
	CRF: MPGN ^a	NN prot, RFD and HM	PP CPP	in 4 months

^a Diagnosis carried out through renal biopsy.

AZA: azathioprine; CS: corticosteroids; CPP: cyclophosphamide; Cr: creatinine; CyA: cyclosporine; RFD: renal function deterioration; FK: tacrolimus; MPGN: membranoproliferative glomerulonephritis; PIGN: post-infectious glomerulonephritis; HD: haemodialysis; HM: haematuria; HBP: high blood pressure; CRF: cause of chronic renal failure; i.v.: intravenous; MPA: mycophenolic acid; NAS: nephroangiosclerosis; PP: plasmapheresis; RPD: renal polycystic disease; NN prot: non-nephrotic proteinuria; VUR: vesicoureteral reflux; HCV: hepatitis C virus; o.r.: oral route.



the production of antibodies, thus generating an imbalance between antigens and antibodies which, along with the susceptibility of the renal graft, would influence the long-term genesis of *de novo* GN.⁵

Lastly, we wish to highlight the favourable progression of our patient, similar to that presented in other cases of *de novo* IgA GN without crescents in the renal biopsy, a marker of poor prognosis in renal graft relapses.¹⁴⁻¹⁹ Our patient did not display crescents but was HCV positive, which is described as a risk factor for the development of proteinuria, chronic rejection, glomerular lesions, infections and decrease of the survival, both of the graft and the receptor.^{5,6} *De novo* IgA GN appeared while the patient was being treated with the triple immunosuppression therapy (corticosteroids, mycophenolic acid and tacrolimus). However, the control of proteinuria was not achieved despite the increase in the dose of steroids and mycophenolic acid. Lastly, blockade of the renin-angiotensin-aldosterone system was done with ARA II and spironolactone, with a decrease in proteinuria but a slight deterioration in renal function, which is currently stable. The patient is being treated with mycophenolic acid as part of his immunosuppression therapy, although the use of mycophenolic acid in the treatment of IgA nephropathy is still controversial.³⁰

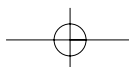
In summary, the HCV is related with pathogenesis in different renal diseases, amongst them MPGN and IgA GN. In our case, we believe that infection due to the HCV could have contributed to the pathogenesis of both glomerular processes, although, we cannot rule out that *de novo* IgA GN could be secondary to chronic liver disease.

Conflicts of interest

The authors declare that they have no conflicts of interest related to the contents of this article.

REFERENCES

- Ivanyi B. A primer on recurrent and *de novo* glomerulonephritis in renal allografts. *Nat Clin Pract Nephrol* 2008;4(8):446-57.
- Denton MD, Singh AK. Recurrent and *de novo* glomerulonephritis in the renal allograft. *Semin Nephrol* 2000;20(2):164-75.
- Meyers CM, Seeff LB, Stehman-Breen CO, Hoofnagle JH. Hepatitis C and renal disease: an update. *Am J Kidney Dis* 2003;42(4):631-57.
- Morales JM, Pascual-Capdevila J, Campistol JM, Fernandez-Zatarain G, Muñoz MA, Andres A, et al. Membranous glomerulonephritis associated with hepatitis C virus infection in renal transplant patients. *Transplantation* 1997;63(11):1634-9.
- Cruzado JM, Carrera M, Torras J, Grinyo JM. Hepatitis C virus infection and *de novo* glomerular lesions in renal allografts. *Am J Transplant* 2001;1(2):171-8.
- Dominguez-Gil B, Morales JM. Transplantation in the patient with hepatitis C. *Transpl Int* 2009;22(12):1117-31.
- Ji F, Li Z, Ge H, Deng H. Successful interferon-alpha treatment in a patient with IgA nephropathy associated with hepatitis C virus infection. *Intern Med* 2010;49(22):2531-2.
- Gonzalo A, Fernandez M, Navarro J, Ortuno J. Searching for hepatitis C virus antibodies in chronic primary glomerular diseases. *Nephron* 1995;69(1):96.
- Gonzalo A, Navarro J, Barcena R, Quereda C, Ortuno J. IgA nephropathy associated with hepatitis C virus infection. *Nephron* 1995;69(3):354.
- Cabezuelo JB, Enríquez R, Andrada E, Amorós F, Sirvent AE, Reyes A. [Extracapillary IgA nephropathy associated with infection with hepatitis C virus and hepatic cirrhosis]. *Nefrologia* 2000;20(4):379-82.
- Sumida K, Ubara Y, Hoshino J, Suwabe T, Nakanishi S, Hiramatsu R, et al. Hepatitis C virus-related kidney disease: various histological patterns. *Clin Nephrol* 2010;74(6):446-56.
- Coccoli P, Esposito P, Cianciaruso B, Pota A, Visciano B, Anecchini R, et al. Hepatitis C and kidney disease. *Dig Liver Dis* 2007;39 Suppl 1:S83-5.
- Pouria S, Barratt J. Secondary IgA nephropathy. *Semin Nephrol* 2008;28(1):27-37.
- Robles NR, Gomez Campdera FJ, Anaya F, Niembro De Rasche E, Galan A, Rengel MA, et al. IgA nephropathy with rapidly progressive course after kidney transplantation. *Nephron* 1991;58(4):487-8.
- Francisco S, Wall BM, Cooke CR. Immunoglobulin A nephropathy in a renal allograft of a black transplant recipient. *Am J Nephrol* 1992;12(1-2):121-5.
- Jeong HJ, Kim YS, Kwon KH, Kim SI, Kim MS, Choi KH, et al. Glomerular crescents are responsible for chronic graft dysfunction in post-transplant IgA nephropathy. *Pathol Int* 2004;54(11):837-42.
- Gough J, Yilmaz A, Yilmaz S, Benediktsson H. Recurrent and *de novo* glomerular immune-complex deposits in renal transplant biopsies. *Arch Pathol Lab Med* 2005;129(2):231-3.
- Kowalewska J, Yuan S, Sustento-Reodica N, Nicosia RF, Smith KD, Davis CL, et al. IgA nephropathy with crescents in kidney transplant recipients. *Am J Kidney Dis* 2005;45(1):167-75.
- Tang Z, Ji SM, Chen DR, Wen JQ, Chen JS, Liu ZH, et al. Recurrent or *de novo* IgA nephropathy with crescent formation after renal transplantation. *Ren Fail* 2008;30(6):611-6.
- Campistol JM, Oppenheimer F, Darnell A, Andreu J, Torras A, Revert L. [Incidence and characteristics of glomerular diseases after kidney transplant]. *Med Clin (Barc)* 1990;94(20):761-5.
- Sethi S, Fervenza FC. Membranoproliferative glomerulonephritis—a new look at an old entity. *N Engl J Med* 2012;366(12):1119-31.
- Berthoux FC, Alamartine E, Pommier G, Lepetit JC. HLA and IgA nephritis revisited 10 years later: HLA-B35 antigen as a prognostic factor. *N Engl J Med* 1988;319(24):1609-10.
- Ji S, Liu M, Chen J, Yin L, Sha G, Chen H, et al. The fate of glomerular mesangial IgA deposition in the donated kidney after allograft transplantation. *Clin Transplant* 2004;18(5):536-40.
- Fabrizi F, Plaisier E, Saadoun D, Martin P, Messa P, Cacoub P. Hepatitis C virus infection, mixed cryoglobulinemia, and kidney disease. *Am J Kidney Dis* 2013;61(4):623-37.
- Strom EH, Durmuller U, Gudat F, Mihatsch MJ. Hepatitis C virus





clinical cases

María Molina et al. Two cases of glomerulonephritis in a patient with the HCV

- plays no role in the pathogenesis of immunoglobulin A nephropathy in liver cirrhosis. *Nephron* 1994;67(3):370.
26. Pouteil-Noble C, Maiza H, Dijoud F, MacGregor B. Glomerular disease associated with hepatitis C virus infection in native kidneys. *Nephrol Dial Transplant* 2000;15 Suppl 8:28-33.
 27. Gordon A, Menahem S, Mitchell J, Jenkins P, Dowling J, Roberts SK. Combination pegylated interferon and ribavirin therapy precipitating acute renal failure and exacerbating IgA nephropathy. *Nephrol Dial Transplant* 2004;19(8):2155.
 28. Fabrizi F, Pozzi C, Farina M, Dattolo P, Lunghi G, Badalamenti S, et al. Hepatitis C virus infection and acute or chronic glomerulonephritis: an epidemiological and clinical appraisal. *Nephrol Dial Transplant* 1998;13(8):1991-7.
 29. Sansonno D, Lauletta G, Montrone M, Grandaliano G, Schena FP, Dammacco F. Hepatitis C virus RNA and core protein in kidney glomerular and tubular structures isolated with laser capture microdissection. *Clin Exp Immunol* 2005;140(3):498-506.
 30. Boyd JK, Cheung CK, Molyneux K, Feehally J, Barratt J. An update on the pathogenesis and treatment of IgA nephropathy. *Kidney Int* 2012;81(9):833-43.

