

- 2008;51(3):435-44.
4. Gagnadoux MF, Habib R, Gubler MC, Bacri JL, Broyer M. Long-term (15-25 years) outcome of childhood hemolytic-uremic syndrome. *Clin Nephrol* 1996;46(1):39-41.
  5. Kelles A, Van Dyck M, Proesmans W. Childhood haemolytic uraemic syndrome: long-term outcome and prognostic features. *Eur J Pediatr* 1994;153(1):38-42.
  6. Garg AX, Suri RS, Barrowman N, Rehman F, Matsell D, Rosas-Arellano MP, et al. Long-term renal prognosis of diarrhea-associated hemolytic uremic syndrome. A systematic review, meta-analysis, and meta-regression. *JAMA* 2003;290:1360-70.
  7. Moghal NE, Ferreira MAS, Howie AJ, Milford DV, Raafat F, Taylor CM. The late histologic findings in diarrhea-associated hemolytic uremic syndrome. *J Pediatr* 1998;133(2):220-3.
  8. Caletti MG, Gallo G, Gianantonio CA. Development of focal segmental sclerosis and hyalinosis in haemolytic uremic syndrome. *Pediatr Nephrol* 1996;10:687-92.
  9. Tönshoff B, Sammet A, Sanden I, Mehls O, Waldherr R, Schärer K. Outcome and prognostic determinants in the hemolytic uremic syndrome of children. *Nephron* 1994;68(1):63-70.
  10. Vikse BE, Irgens LM, Leivestad T, Skjaerven R, Iversen BM. Preeclampsia and the risk of End-Stage renal disease. *N Engl J Med* 2008;359:800-9.

Juan A. Martín-Navarro<sup>1</sup>,  
Vladimir Petkov-Stoyanov<sup>1</sup>,  
M. José Gutiérrez-Sánchez<sup>1</sup>,  
Pablo Justo-Ávila<sup>1</sup>, Delissa Díaz-Díaz<sup>2</sup>

<sup>1</sup> Unidad de Nefrología. Hospital del Tajo. Aranjuez, Madrid. (Spain).

<sup>2</sup> Servicio de Anatomía Patológica. Hospital Universitario 12 de Octubre. Madrid. (Spain).

**Correspondence:** Juan A. Martín Navarro

Unidad de Nefrología.  
Hospital del Tajo.  
Avda. Amazonas, s/n.  
28300 Aranjuez, Madrid. (Spain).  
juanmartinnav@hotmail.com

## An uncommon cause of high blood pressure in young people: retroperitoneal paraganglioma with vascular invasion

*Nefrologia* 2013;33(3):435-7

doi:10.3265/Nefrologia.pre2012.Oct.11744

### To the Editor:

Paragangliomas are rare extra-adrenal tumours that emerge from the autonomic nervous system. They are classified as functioning or non-functioning tumours, depending on the production of catecholamines. It presents clinically as high blood pressure associated with vegetative symptoms.

### CLINICAL CASE

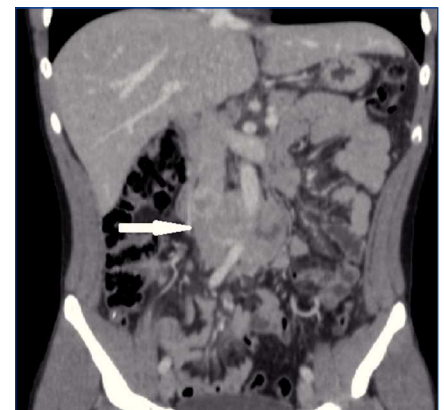
We report the case of a 20-year-old male who presented with hypertensive emergency that had begun a year before, accompanied by profuse sweating, generalised flushing, headaches and occasionally, lower back pain. Blood pressure reached 230/110mmHg, often triggered by physical effort. A physical examination revealed malar rash and palmar erythema that disappeared with acupressure. Laboratory tests showed an increase in catecholamines and metanephrines in urine at 24 hours: noradrenaline excretion of 7515.77nmol/24h (<504), dopamine of 4298.84nmol/24h (<3237) and normetanephrine of 39676nmol/24h (<2424).

An abdominal ultrasound revealed a retroperitoneal mass of about 8cm of heterogeneous echogenicity and marked vascularisation. Given these findings, a computerised tomography (CT) scan of the abdomen and pelvis was performed that confirmed the existence of a retroperitoneal mass of 8 x 4cm above the aortic bifurcation that infiltrated the inferior vena cava and bordered 180° of the aorta, covering the inferior mesenteric artery (Figure

1). Given the findings of the CT scan, a cavography was performed to evaluate resectability, revealing an infrarenal intracaval filling defect 2cm in diameter (Figure 2).

Suspecting paraganglioma of the organ of Zuckerkandl, beta-adrenergic blockade was produced and we subsequently performed a surgical en bloc resection of the tumour; we partially sectioned the anterior vena cava to remove the intracaval tumour. The postoperative course was uneventful, the symptoms disappeared and plasma and urine catecholamine and metanephrine levels normalised.

The anatomopathological diagnosis confirmed the suspicion of well-delimited and encapsulated paraganglioma, with a low proliferative index (Ki 67: 5-7%). The patient was referred to the Medical Oncology department, where a 123I-MIBG scintigraphy was requested that showed no signs of residual or distant disease. In the absence of data that justified adjuvant chemotherapy, it was decided to follow up the patient periodically.



**Figure 1.** Computerised tomography of the abdomen and pelvis (sagittal section). Heterogeneous lobulated retroperitoneal tumour, bordering the aorta and infiltrating the inferior vena cava.

## DISCUSSION

Paragangliomas are very rare tumours, with an overall incidence estimated at between 0.2 and 0.5 cases per 100 000 inhabitants/year.<sup>1</sup> They are extra-adrenal pheochromocytomas that emerge from the chromaffin cells of the sympathetic ganglia located in the retroperitoneum, more commonly near the beginning of the inferior mesenteric artery (organ of Zuckerkandl<sup>2</sup>) and chest, or the parasympathetic ganglia adjacent to the aortic arch, neck and basal ganglia. They are generally single tumours that are predominant in males between 30 and 45 years of age.

Between 30% and 60% secrete catecholamines and have paroxysmal or sustained hypertension, associated with the classic triad: palpitations, headaches and profuse sweating. Those who do not secrete may have

pain or abdominal mass, but they are often found incidentally.<sup>3</sup>

The diagnosis of functioning paragangliomas is biochemical when they show an increase in plasma and urine catecholamines or metabolites at 24 hours that is two or three times above their normal limit. For the location diagnosis, CT or MRI is usually performed with sensitivity of around 98%-100%. The 123I-MIBG scintigraphy is very useful in locating extra-adrenal tumours and detecting multiple tumours.<sup>4</sup>

Proposed criteria for poor prognosis are distant metastasis, vascular or capsular invasion, a high mitotic index, a tumour size greater than 10cm or post-surgical recurrence.<sup>5</sup> Retroperitoneal paragangliomas are malignant in 30% to 50% of cases, metastasising in 20% to 42% to areas such as lymph nodes, bone, lung and liver.<sup>6</sup> The 5-year survival rate for patients with metastatic paraganglioma is approximately 50%.

Aggressive surgical resection is the treatment of choice, since there is a positive correlation between the possibility of complete exeresis and prognosis. Previously, alpha and beta inhibition was performed (10-14 days) to avoid hypertensive emergency. Surgical resection is also indicated for tumour recurrences. If the tumour is unresectable, the tumour mass can be reduced by chemotherapy or radiotherapy, although these would only be palliative treatments.<sup>7</sup>

Despite the rarity of paragangliomas, it is important to bear them in mind in the differential diagnosis of high blood pressure, especially in young patients, due to their malignant potential and the effects of catecholamine secretion on the cardiovascular system. Early diagnosis and aggressive treatment are critical in addressing these neoplasms.

### Conflicts of interest

The authors declare that they have no conflicts of interest related to the contents of this article.

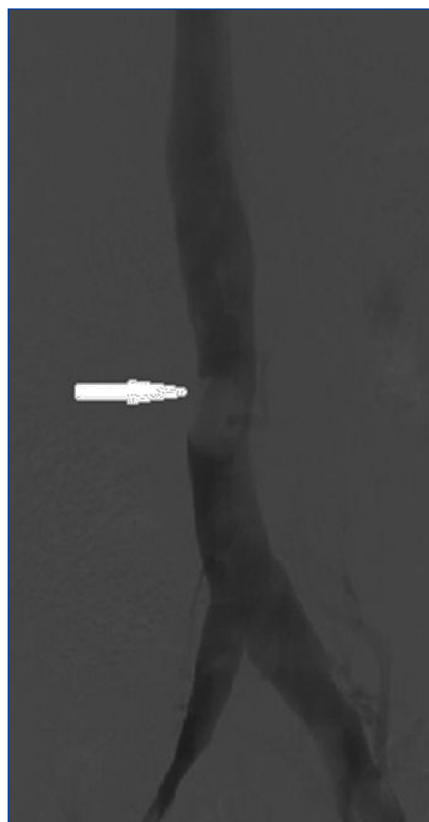
1. Montresor E, Lacono C, Nifosi F, Zanza A, Modena S, Zamboni G, et al. Retroperitoneal paragangliomas: role of immunohistochemistry in the diagnosis of malignancy and in assessment of prognosis. *Eur J Surg* 1994;160:547-52.
2. Cervera M, Olea JM, Díez-Caballero A, Martínez-Regueira F, Gil A, Valentí V, et al. Paraganglioma extraadrenal localizado por PET y extirpado por vía laparoscópica. *Cir Esp* 2003;73(2):138-40.
3. Joynt KE, Moslehi JJ, Baughman KL. Paragangliomas: etiology, presentation and management. *Cardiol Rev* 2009;17:159-64.
4. Whalen RK, Althausen AF, Daniels GH. Extra-adrenal pheochromocytoma. *J Urol* 1992;21:1703-9.
5. Dunder P, Dudorkinová D, Povýsil C, Pešl M, Babjuk M, Dvůráček J, et al. Pigmented composite paraganglioma-ganglioneuroma of the urinary bladder. *Pathol Res Pract* 2003;199:765-9.
6. Yang JH, Bae SJ, Park S, Park HK, Jung HS, Chung JH, et al. Bilateral pheochromocytoma associated with paraganglioma and papillary thyroid carcinoma: report of an unusual case. *Endocrine Journal* 2007;54(2):227-23.
7. Somasundar P, Krouse R, Hostetter R, Vaughan R, Covey T. Paragangliomas, a decade of clinical experience. *J Surg Oncol* 2000;74(4):286-90.

**M. Dolores Ayllón-Terán<sup>1</sup>,  
Manuela Torres-Lorite<sup>1</sup>,  
J. Manuel Benítez-Cantero<sup>2</sup>,  
J. Manuel Sánchez-Hidalgo<sup>1</sup>,  
Carlos Díaz-Iglesias<sup>1</sup>,  
Sebastián Rufián-Peña<sup>1</sup>**

<sup>1</sup> Unidad de Gestión Clínica-Cirugía General. Hospital Universitario Reina Sofía. Córdoba. (Spain).

<sup>2</sup> Unidad de Gestión Clínica-Aparato Digestivo. Hospital Universitario Reina Sofía. Córdoba. (Spain).

**Correspondence:** M. Dolores Ayllón Terán  
Unidad de Gestión Clínica-Cirugía General.  
Hospital Universitario Reina Sofía.  
Avda. Menéndez Pidal, s/n.  
14004 Córdoba. (Spain).  
lolesat83@hotmail.com



**Figure 2.** Cavography. Filling defect of around 2.5cm in the inferior vena cava.