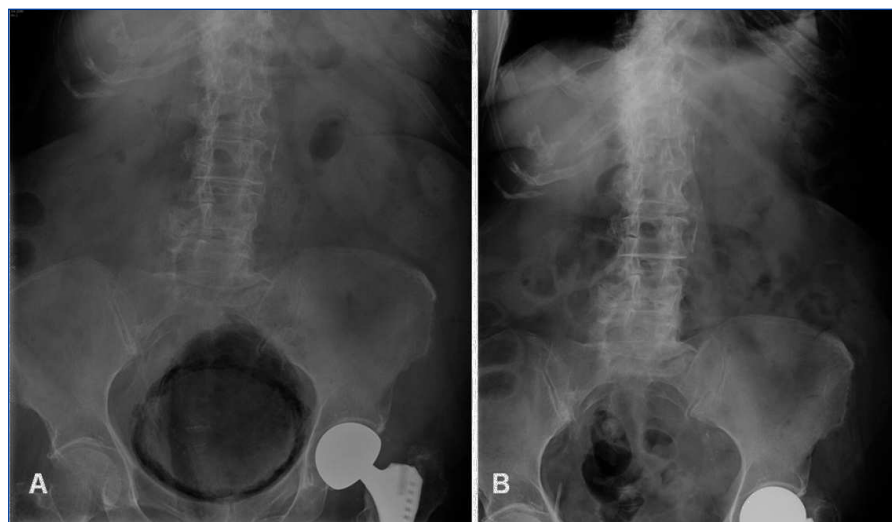

**Figure 1.** Emphysematous cystitis.

## Conflicts of interest

The authors declare that they have no conflicts of interest related to the contents of this article.

1. Thomas AA, Lane BR, Thomas AZ, Remer EM, Campbell SC, Shoskes DA. Emphysematous cystitis: a review of 135 cases. *BJU Int* 2007;100:17-20.
2. Sereno M, Gómez-Raposo C, Gutiérrez-Gutiérrez G, López-Gómez M, Casado E. Severe emphysematous cystitis: Outcome after seven days of antibiotics. *Mcgill J Med* 2011;13(1):13.
3. Joshi N, Caputo G, Weitekamp MR, Karchmer AW. Infections in patients with diabetes mellitus. *N Engl J Med* 1999;341(25):1906-12.
4. Bjurlin MA, Hurley S, Kim DY, Cohn MR, Jordan MD, Kim R, et al. Clinical outcomes on nonoperative management in emphysematous urinary tract infections. *Urology* 2012;79(6):1281-5.
5. Mokabberi R, Ravakhab K. Emphysematous urinary tract infections. *Am J Med Sci* 2007;333(2):111-6.

**Cristina Vega-Cabrera,**  
**Olga Costero-Fernández,**  
**Begoña Rivas-Becerra,**  
**David Menéndez-González,**  
**Rafael Selgas-Gutiérrez**

Unidad de Nefrología.  
Hospital Universitario La Paz, IdiPAZ. Madrid.  
(Spain).

**Correspondence:** Cristina Vega Cabrera

Unidad de Nefrología.  
Hospital Universitario La Paz, IdiPAZ.  
P.º de la Castellana, 261.  
28046 Madrid. (Spain).  
mcvega.hulp@salud.madrid.org  
dracristina90@hotmail.com

## Recurrent cutaneous necrosis of a multifactorial origin in a patient on haemodialysis

*Nefrologia* 2013;33(1):150-2

doi:10.3265/Nefrologia.pre2012.Nov.11677

### To the Editor:

We present the case of a 40-year-old female, who was an ex-smoker until 2010, when she retook the habit. The patient suffered from lupus with joint, haematological, and pericardial manifestations; the patient also suffered from anti-phospholipid syndrome with arterial manifestations (cerebrovascular accident, renal artery stenosis, and stenosis of the arteriovenous fistula [AVF]), poorly controlled arterial hypertension, advanced chronic kidney disease (CKD) secondary to focal and segmental hyalinosis (insufficient evi-

dence to rule out the coexistence of type V lupus nephritis), and on haemodialysis treatment since 1990. The patient received a kidney transplant in 1991, but restarted dialysis in 1998 after a recurrence of the underlying disease, which coincided with pregnancy. Severe tertiary hyperparathyroidism with regular/poorly controlled phosphorous levels for several years (variable compliance with treatment) and osteoporosis of trabecular bone (t-score: -2.5; z-score: -2.3). The patient also exhibited hyperhomocysteinemia, hyperuricemia, and a hidden hepatitis C infection with haemosiderosis. The right humerobasilic AVF was functional. Normal treatment included cinacalcet, pepsamar, calcium acetate, risedronate, folic acid, polyvitamin B1/6/12, omeprazole, allopurinol, carvedilol, hydroxychloroquine, and acenocoumarol.

### CURRENT DISEASE

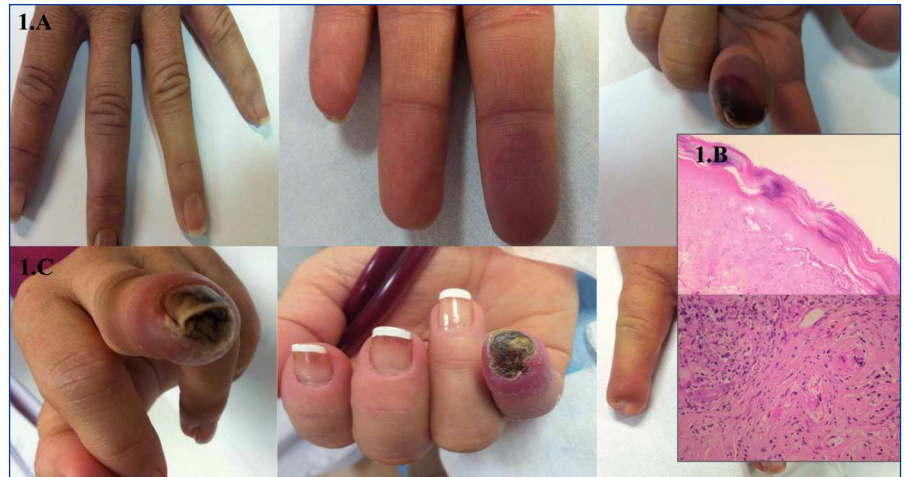In September 2009, acenocoumarol was replaced with tinzaparin (anti-activated factor X: 0.8-1.2IU/ml) due to upper gastrointestinal bleeding, and the patient remained on this treatment regimen for one year. In November 2010, she developed purple lesions on the pad of the third finger of the left hand, contralateral to the AVF (Figure 1 A), which were cold and painful to the touch. Radial pulse was normal. An ipsilateral Doppler ultrasound revealed **mild calcified atheromatosis of the axillary and brachial arteries, with no haemodynamically significant stenosis**. During the first 24 hours, acenocoumarol was reinitiated, and topical nitroglycerin was added to the treatment regimen. An INR of 4 was reached in 72 hours, which allowed for the suspension of tinzaparin. Five days after the start of symptoms, the patient complained of intense pain in the finger and a slow progression towards cutaneous necrosis and a new lesion with similar ischaemic characteristics to the second ipsilateral finger. Treatment was started with antibiotic therapy and alprostadil (500ug i.v. over 10 doses). Dicoumarin was suspended, and tinzaparin was recommenced. We took a

cutaneous biopsy, which revealed **ischaemic haemorrhagic necrosis, microcirculation thrombosis, and leukocytoclast phenomena, indistinguishable from necrosis induced by coumarin or anti-phospholipid syndrome**, and isolation of *Enterobacter cloacae* in the tissue culture (Figure 1 B).

The lesion on the 2<sup>nd</sup> finger quickly returned to normal, but the third finger progressed to necrosis and scarring with nail loss and partial amputation leaving a blind stump (Figure 1 C). A trans-oesophageal echocardiogram ruled out vegetations. Protein C levels decreased over two measurements: 57% activity (n>70%). The family history analysis was negative. Protein S levels were normal. We did not measure anti-thrombin III levels due to the treatment with heparin, and did not measure anti-thrombin III antibodies due to the unavailability of this test at our centre.

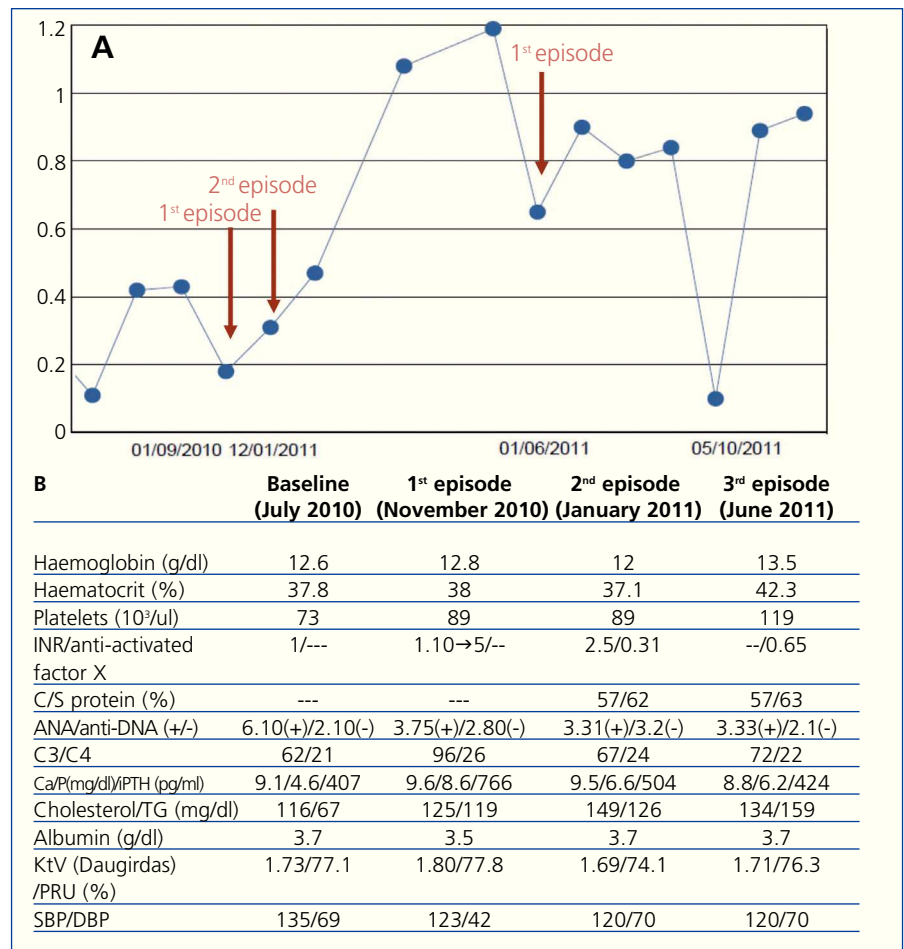
In January 2011, acenocoumarol was recommenced on a very slow and progressive regimen. Thirteen days after starting medication, the patient developed an identical set of symptoms on the fifth finger of the opposite (right) hand. Dicoumarin treatment was definitively suspended and tinzaparin was restarted (Figure 2 A), and the ischaemic lesion subsided after a few days. After one week, and coinciding with a trip to a cold region, increased tobacco use, and a respiratory infection, the same symptoms appeared at the same location (fifth finger of right hand), again requiring intravenous prostaglandins and morphine. The finger finally progressed to necrosis, causing fingernail loss and amputation leaving a blind stump (Figure 1 C).

In June 2011, the patient developed similar but milder symptoms in the third finger of the right hand, this time coinciding with a haemoglobin value of 15g/dl. The patient was bled and started on alprostadil, which effectively treated the ischaemia. A Doppler ultrasound revealed **marked spectral wave damping in the cubital, radial, and**



**Figure 1.** Macro and microscopic images of lesions.

A) Raynaud's of the 4-5<sup>th</sup> finger and ischaemia with progression to haemorrhagic necrosis of the 3<sup>rd</sup> finger of the left hand. B) Cutaneous biopsy (3mm punch). (10x): dermal-epidermal ischaemic haemorrhagic necrosis. (40x): interstitial leukocytoclast; small vessel arterial thrombi. C) Final evolution to necrosis of the 3<sup>rd</sup> finger of the left hand and 5<sup>th</sup> finger of the right hand.



**Figure 2.** Laboratory parameters.

A) Temporal progression of anti-activated factor X (IU/ml). B) Auto-immunity and relatives. ANA: anti-nuclear antibodies; INR (international normalised ratio): ratio between the prothrombin time of the patient on treatment and the theoretical normal value (in healthy patients without oral anticoagulant treatment); DBP: diastolic blood pressure; SBP: systolic blood pressure; iPTH: intact parathyroid hormone; PRU: percent reduction of urea; TG: triglycerides.

**medial arteries just past the AVF, which indicated a phenomenon of arterial steal syndrome from the vascular access. We did not observe stenosis in the anastomosis. The brachial, radial, cubital, and medial left arteries had adequate arterial flow.**

We decided against closing the vascular access given clinical improvements and no other non-catheter treatment options. During each acute episode, arterial flow decreased to 300ml/min (normal: 450ml/min). The dialysis dose was not changed significantly, with a Daugirdas Kt/V that remained constantly above 1.5, and a PRU>65%.

Parameters for lupus activity (anti-DNA and C3, C4) were negative during the first episode, and C3 decreased slightly in the second and third episodes. We did not measure anti-phospholipid antibodies due to the scarce relationship these levels have with the patient's symptoms, and due to the administration of anticoagulation therapy (Figure 2 B).

### DISCUSSION

CKD is considered to be a pro-atherosclerotic condition per se. Poor control of calcium-phosphorous metabolism in haemodialysis patients exponentially increases vascular risk, on a similar scale to tobacco use or diabetes.<sup>1</sup> In a similar manner, SLE and APS and their treatments (steroids, anti-calceinurics) contribute to endothelial dysfunction in these patients,<sup>2</sup> in addition to the recent association between these diseases and activated protein C deficiency or resistance.<sup>3,4</sup> Patients with deficiencies for this protein appear to be more susceptible to cutaneous necrosis when treated with dicoumarin.<sup>5</sup>

These factors, alone or in combination, can compromise distal perfusion. The coexistence of all of these factors and tobacco use, exposure to cold, haemoconcentration, hyperhomocysteinemia, and functional arterial steal syndrome due to the vascular access can constitute an "explosive mix" that

can cause progression and recurrence of the digital cutaneous necrosis described here.

### Conflicts of interest

The authors declare that they have no conflicts of interest related to the contents of this article.

1. Go AS, Chertow GM, Fan D, McCulloch CE, Hsu CY. Chronic kidney disease and the risks of death, cardiovascular events, and hospitalization. *N Engl J Med* 2004;351(13):1296-30.
2. Petri MA, Kiani AN, Post W, Christopher-Stine L, Magder LS. Lupus Atherosclerosis Prevention Study (LAPS). *Ann Rheum Dis* 2011;70(5):760-5.
3. Muñoz-Rodríguez FJ, Reverter JC, Font J, Tàssies D, Espinosa G, Cervera R, et al. Clinical significance of acquired activated protein C resistance in patients with systemic lupus erythematosus. *Lupus* 2002;11:730-5.
4. Nojima J, Kuratsune H, Suehisa E, Kawasaki T, Machii T, Kitani T, et al. Acquired activated protein C resistance is associated with the co-existence of antiprothrombin antibodies and lupus anticoagulant activity in patients with systemic lupus erythematosus. *Br J Haematol* 2002;118:577-83.
5. Vhan YC, Valenti D, Mansfield AO, Stansby G. Warfarin induced skin necrosis. *Br J Surg* 2000;87:266-72.

**Adoración Martín-Gómez<sup>1</sup>,  
M. Eugenia Palacios<sup>1</sup>, José Roig-Álvarez<sup>2</sup>,  
José L. Martínez-Amo Gámez<sup>2</sup>,  
Sergio A. García-Marcos<sup>3</sup>**

<sup>1</sup> Unidad de Hemodiálisis.  
Hospital de Poniente. El Ejido, Almería.  
(Spain).

<sup>2</sup> Servicio de Anatomía Patológica.  
Hospital de Poniente. El Ejido, Almería.  
(Spain).

<sup>3</sup> Unidad de Dermatología.  
Hospital de Poniente. El Ejido, Almería.  
(Spain).

**Correspondence:** Adoración Martín Gómez  
Unidad de Hemodiálisis.  
Hospital de Poniente. Ctra. Málaga núm. 119.  
04700 El Ejido. Almería. (Spain).  
doritamg@gmail.com  
doritamg@mixmail.com

## De novo tacrolimus – associated hemolytic uremic syndrome after renal transplantation

*Nefrologia* 2013;33(1):152-4

doi:10.3265/Nefrologia.pre2012.Oct.11793

### To the Editor:

De novo Hemolytic Uremic Syndrome (HUS) occurs in 1-5% of renal transplant recipients, most frequently within the first 3 months after transplantation.<sup>1,2</sup>

Thrombotic Microangiopathy (TMA) usually sets in the first weeks post-transplant when patients are treated with high dose of immunosuppressant.

De novo TMA has been documented in approximately 1% of patients receiving tacrolimus.<sup>2</sup> Calcineurin inhibitor – induced nephrotoxicity primarily results from dose dependent renal arteriolar vasoconstriction,<sup>3</sup> owing of the enhanced production of vasoconstrictive factors, particularly endothelin-1 and angiotensin II.<sup>4,5</sup> Moreover, calcineurin inhibitors might promote a procoagulant state enhancing platelet aggregation and activating plasminogen activator.<sup>6</sup> De novo post-transplant HUS has been reported both with the use of an mTOR inhibitor alone and in combination therapy.<sup>7</sup> The viral infections, to which patients on immunosuppression are susceptible, have been implicated in pathogenesis of de novo HUS in organ transplant recipients. A CMV infection<sup>8</sup> has been associated with both the novo and recurrent<sup>9</sup> forms of post-transplant HUS. Parvovirus B19 and polioma BK virus infection have also been associated with de novo HUS in renal transplant recipients.<sup>10-12</sup>

The authors describe the clinical case of a Caucasian male, 33 years old with a history of chronic kidney disease of unknown etiology, in hemodialysis for nearly 7 years, with past medical history of severe hypertension, severe hypertriglyceridemia and chronic pancreatitis. Family history was irrelevant.