

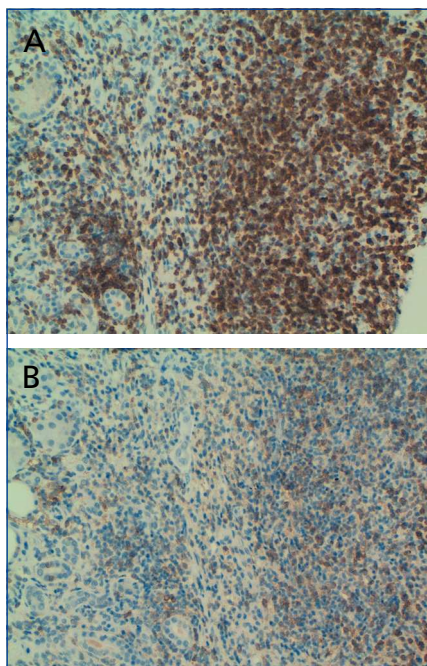Figure 2. (A) Immunohistochemical staining (x20) with CD3. (B) Immunohistochemical staining (x20) with CD4.

ted with sclerosing cholangitis, leading to speculation about a new syndrome.

We have described a new case of interstitial nephritis in a female patient with PSC. In our case, we evaluated whether this could be in the context of IgG4-related sclerosing disease, but could not show such an association: firstly, because plasma IgG levels were 1mg/dl (although the patient did have an overall decrease in all immunoglobulins), and secondly, because the renal histological analysis did not report positivity for IgG4. However, the levels of IgG4 alone are insufficient to include or exclude the diagnosis of IgG4-related systemic disease.⁹ In fact, we observed dense interstitial infiltration of predominantly CD4-positive T-lymphocytes, which practically destroyed all renal structures.

There is no standardised treatment protocol for this new entity, although the majority of studies have prescribed 30–60mg/day of prednisolone in a progressively decreasing prescription, with good responses.⁵⁻⁷ In our case, the severe level of interstitial damage led us to indicate treatment with oral steroids: although we did not reach a complete recovery of renal function (possibly because the deterioration was already several

months progressed before the biopsy, with severe histological damage), we did manage to stabilise renal function.

In conclusion, we have described the case of severe interstitial nephritis in a woman with primary sclerosing cholangitis: in these patients, we should examine whether this association could be referred to as an emerging pathology: “IgG4-related systemic disease.”

Conflicts of interest

The authors affirm that they have no conflicts of interest related to the content of this article.

1. Mendes F, Lindor KD. Primary sclerosing cholangitis: overview and update. *Nat Rev Gastroenterol Hepatol* 2010;7(11):611-9.
2. Tischendorf JJ, Hecker H, Krüger M, Manns MP, Meier PN. Characterization, outcome, and prognosis in 273 patients with primary sclerosing cholangitis: A single center study. *Am J Gastroenterol* 2007;102:107-14.
3. Montini G, Carasi C, Zancan L, Dall'Amico R, Murer L, Zacchello G, et al. Chronic cholestatic liver disease with associated tubulointerstitial nephropathy in early childhood. *Pediatrics* 1997;100(3):E10.
4. Neuhaus TJ, Stallmach T, Leumann E, Altorfer J, Braegger CP. Familial progressive tubulo-interstitial nephropathy and cholestatic liver disease—a newly recognized entity? *Eur J Pediatr* 1997;156(9):723-6.
5. Kamisawa T, Okamoto A. IgG4-related sclerosing disease. *World J Gastroenterol* 2008;14(25):3948-55.
6. Patel SM, Szostek JH. IgG4-related systemic disease in a native American man. *Intern Med* 2011;50:931-4.
7. Ebbo M, Grados A, Daniel L, Vély F, Harlé JR, Pavic M, et al. IgG4-related systemic disease: emergence of a new systemic disease? Literature review. *Rev Med Interne* 2012;33(1):23-34.
8. Angulo P, Peter JB, Gershwin ME. Serum autoantibodies in patients with primary sclerosing cholangitis. *J Hepatol* 2000;32:182.
9. Morselli-Labate AM, Pezzilli R. Usefulness of serum IgG4 in the diagnosis and follow-up of autoimmune pancreatitis: A

systematic literature review and meta-analysis. *J Gastroenterol* 2009;24:15-36.

Manuel Heras¹, Ana Saiz², M. José Fernández-Reyes¹, Rosa Sánchez¹, Álvaro Molina¹, M. Astrid Rodríguez¹, Fernando Álvarez-Ude¹

¹Servicio de Nefrología. Hospital General de Segovia. (Spain).

²Servicio de Anatomía patológica. Hospital Universitario Ramón y Cajal. Madrid.(Spain).

Correspondence: Manuel Heras

Servicio de Nefrología.

Hospital General de Segovia. 40002 Segovia. (Spain).

mherasb@saludcastillayleon.es

Minimal-change nephropathy in systemic lupus erythematosus

Nefrologia 2012;32(3):412-3

doi:10.3265/Nefrologia.pre2012.Feb.11372

To the Editor,

In patients diagnosed with systemic lupus erythematosus (SLE) and nephrotic syndrome, the most common histological findings are diffuse proliferative glomerulonephritis and membranous nephropathy (class IV and class V according to the World Health Organisation [WHO], 1982).¹

Here we report the case of a patient with SLE who developed nephrotic syndrome secondary to minimal-change nephropathy (MCN).

Our patient was a 59 year-old woman diagnosed with SLE (photosensitivity, discoid lupus, arthritis, and positive test for antinuclear antibodies [ANA]) 18 years earlier, occasionally under treatment with non-steroidal anti-inflammatory drugs (NSAID) and hydroxychloroquine. The patient was referred to our department for oedema in the legs and arterial hypertension for the past two months. The physical examination revealed oedema in both legs up to the knee and a blood pressure of 140/90mm Hg. The laboratory analysis revealed nor-

mal haemoglobin, leukocyte, and platelet values; creatinine: 0.75mg/dl; urea: 31mg/dl; total cholesterol: 241mg/dl; albumin: 3.2g/dl; ANA+: 1/640 (several years earlier: +1/320); anti-Ro: 127.9U/ml; normal/negative results for lupus anti-coagulants, anti-cardiolipin antibodies, anti-DNA, ENA, anti-La, and C3-C4; proteinogram without a monoclonal peak; proteinuria: 6.2g/24 hours (high-resolution electrophoresis [HRE]: selective glomerular pattern); urinary sediment: 12-20 red blood cells/field; negative urine culture. Serology for hepatitis B and C, HIV, and Epstein-Barr was negative; cytomegalovirus: previous exposure, negative RPR. Chest x-ray, echocardiogram, renal ultrasound, mammography, thoracic/abdominal/pelvic tomography, and gastroscopy were without relevant abnormalities.

The percutaneous renal biopsy (13 glomeruli) showed 2/3 normal glomeruli and 1/3 with mesangial widening, with no thickening of the capillary walls or other lesions (Figure 1); the immunofluorescence analysis revealed IgM mesangial deposits in less than 1 third of the glomeruli, with no IgG or complement; the electron microscope analysis found diffuse effacement of pedicels and an absence of electron-dense deposits, all of which was compatible with MCN.

We administered prednisone 50mg/day for 8 weeks in a progressively decreasing pattern. Proteinuria decreased progressively, with partial/complete remission 14 months after the diagnosis (proteinuria: 480mg/24h).

MCN is uncommon in SLE, with a prevalence <2% in adults.^{2,3}

MCN can appear in SLE along with the initial diagnosis or during a flare, but can also occur several years after the onset of SLE and without any apparent lupus activity.² It is still under debate whether this is a causal relationship or some sort of histological sub-class of lupus nephritis. In principle, the appearance of two autoimmune diseases in the same patient suggests linked pathogenesis. On the other hand, some authors^{2,4} estimate that the prevalence of MCN in SLE is much higher than in the general population, and that

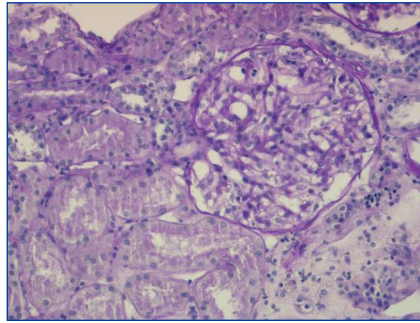


Figure 1. Percutaneous renal biopsy. Visually normal glomerulus. PAS staining x40.

SLE could be the causal factor. Thus, MCN could be a lupus podocytopathy associated with T-lymphocyte alterations in SLE.⁴ However, other authors suggest that idiopathic MCN can appear in patients with SLE that are in remission.⁵

In the current classification system for lupus nephritis (ISN/RPS, 2004), minimal mesangial lupus nephritis is established as class I, characterised by normal glomeruli in optical microscopy analysis and mesangial deposits in immunofluorescence tests and/or electron microscopy analysis.⁶ Cases of MCN in SLE have been described such as ours in which no significant deposits are observed in immunofluorescence or electron microscopy analyses,^{5,7} and that do not fit the current classification for lupus nephritis. However, according to the WHO classification system, they could be categorised as class Ia.

In this patient, we observed no temporal relationship with NSAID treatment.

To conclude, SLE appears to be a precipitating factor for MCN. However, in certain cases such as ours, in which MCN appears several years after SLE onset, with little or no lupus activity and no deposits observed in the renal biopsy samples, the pathogenic relationship is more debatable.

Acknowledgements

We would like to thank Professor Jerónimo Forteza, head of the histopathology department at the Hospital Clínico Universitario de Santiago de Compostela, for his invaluable

assistance with the electron microscopy analysis.

Conflicts of interest

The authors affirm that they have no conflicts of interest related to the content of this article.

1. Dube GK, Markowitz GS, Radhakrishnan J, Appel GB, D'Agati VD. Minimal change disease in systemic lupus erythematosus. *Clin Nephrol* 2002;57:120-6.
2. Hertig A, Droz D, Lesavre P, Grünfeld JP, Rieu P. SLE and idiopathic nephrotic syndrome: coincidence or not? *Am J Kidney Dis* 2002;40:1179-84.
3. Moyses-Neto M, Costa RS, Rodrigues FF, Vieira neto OM, Reis MA., Louzada P, et al. Minimal change disease: a variant of lupus nephritis. *NDT Plus* 2011;4(1):20.
4. Kraft SW, Schwartz MM, Korbet SM, Lewis EJ. Glomerular podocytopathy in patients with systemic lupus erythematosus. *J Am Soc Nephrol* 2005;16:175-9.
5. Perakis C, Arvanitis A, Sotsiou F, Emmanouel DS. Nephrotic syndrome caused by minimal-change disease in a patient with focal proliferative SLE nephritis (WHO III) in remission. *Nephrol Dial Transplant* 1998;13:467-70.
6. Weening JJ, D'Agati VD, Schwartz MM, Seshan SV, Alpers CE, Appel GB, et al. The classification of glomerulonephritis in systemic lupus erythematosus revisited. *J Am Soc Nephrol* 2004;15:241-50.
7. Mok CC, Cheung TT, Lo WH. Minimal mesangial lupus nephritis: a systematic review. *Scand J Rheumatol* 2010;39:181-9.

**M. Dolores Redondo-Pachón¹,
Ricardo Enríquez¹, Ana E. Sirvent¹,
Encarna Andrada², Isabel Millán¹,
Francisco Amorós¹**

¹ Servicio de Nefrología. Hospital General de Elche. Elche, Alicante. (Spain).

² Servicio de Anatomía Patológica. Hospital General de Elche. Elche, Alicante. (Spain).

Correspondence:

M. Dolores Redondo Pachón
Servicio de Nefrología. Hospital General de Elche. Camino de la Almazara, Elche, Alicante. (Spain).
dolypa@hotmail.com
nefro_elx@gva