

- treatment of calciphylaxis. *Am J Health-Syst Pharm* 2008;65:1419-29.
8. Schliep S, Schuler G, Kieseewetter F. Successful treatment of calciphylaxis with pamidronate. *Eur J Dermatol* 2008;18(5):554-6.
9. León LR. Tratamiento de calcifilaxis distal con terapia asociada de

sevelamer y bifosfonatos. *Nefrologia* 2009;29(1):92-3.

**O. Conde Rivera, M. Camba Caride, E. Novoa Fernández, M. Borrajo Prol, J. Santos Nores, E. Iglesias Lamas, W. López Alarcón**

Nephrology Department.  
Ourense Hospital Complex. Spain.  
**Correspondence: M. Camba Caride**  
Servicio de Nefrología.  
Complejo Hospitalario de Ourense.

## C) BRIEF CASE REPORTS

### Varicella zoster virus: complications in an ANCA-positive vasculitis

*Nefrologia* 2011;31(5):616-8

doi:10.3265/Nefrologia.pre2011.Jun.10826

#### To the Editor,

Varicella zoster virus (VZV) infection may present with two types of symptoms: the primary infection, known as varicella, with different stages of vesicular lesions mainly on the chest, head and limbs, and subsequent reactivation that causes herpes zoster (HZ). HZ complications are most common in immunocompromised patients with a high incidence in bone marrow transplantation. It may coexist with a visceral dissemination, which is difficult to diagnose if it is not associated with usual skin lesions. Therefore, delayed treatment is associated with high morbidity and mortality, mainly caused by respiratory distress syndrome, fulminant liver failure, pancreatitis or meningoencephalitis.<sup>4,5</sup>

We present the case of a 79-year-old male with antineutrophil cytoplasmic antibodies (p-ANCA). He was diagnosed in 2004 with alveolar haemorrhage and nephritic syndrome treated with corticoids and cyclophosphamide; chronic kidney failure (started haemodialysis in 2006); pulmonary bleeding secondary to a disease flare that was treated with corticoids and cyclophosphamide in 2008; and subsequent maintenance treatment with prednisone at 5mg/day combined with sodium mycophenolate mofetil (MMF)

at a dosage of 180mg/12 hours. This treatment is maintained to date. Vesical transurethral resection in 2009 due to vesical neoplasm and atrial fibrillation. His usual treatment was: acetylsalicylic acid 100mg, bisoprolol 2.5mg/24 hours, omeprazole 20mg/24 hours, calcium carbonate 2.5g/24 hours, dacortin 5mg/24 hours and MMF 180mg/24 hours. He was administered Eprex 2000 and weekly Venofer during haemodialysis.

He went to the emergency department with dyspnoea of several days of evolution, coughing and slight expectoration, together with abdominal pain that was variable in intensity. He had nervous fever, but no other symptoms of interest and was sent home. He came to the emergency department again four days later, being referred to our hospital. He had the same clinical symptoms and in the physical examination presented with vesicular lesions limited to the abdomen on dermatomes D9, D10 and D11, which appeared two days later. He had blood pressure of 80/40mm Hg, basal oxygen saturation of 84%, tachypnoea, pain upon deep palpation in the right hypochondrium and intercostal muscle strain. Wheezing could be noted on both sides until the middle fields during auscultation. When he was admitted, the biochemical and radiological data were:

1. Haemoglobin (Hb): 11.7g/dl; leukocytes: 4200 (N: 91.4%, L: 5.3%); platelets: 77 000.
2. Aspartate transaminase (GOT): 6926IU/l; alanine transaminase (GPT): 3587IU/l; amylase: 100IU/l; lactate dehydrogenase (LDH): 1995IU/l; creatine kinase

(CK): 152IU/l; myoglobin: 708IU/l; creatinine (Cr): 6.3mg/dl; urea: 88mg/dl; K: 6nmol/l; Na: 144mmol/l; total bilirubin: 2.17mg/dl.

3. pH: 7.21; CHO: 12mEq/l; pCO<sub>2</sub>: 32mm Hg; pO<sub>2</sub>: 59mm Hg.
4. International<sup>2</sup> normalised ratio (INR): 1.7; prothrombin activity: 37%; fibrinogen: 663mg.
5. Chest X-ray: Bilateral interstitial and alveolar pattern with peripheral disposition and cotton-wool like distribution that does not improve following ultrafiltration (Figure 1).

Given that the patient was immunocompromised, and data supported liver failure and acute respiratory failure with skin conditions, VZV was highly probable. We decided to request a serology test for atypical cells; it was VZV-positive, so empirical treatment with acyclovir was started at a dosage of 250mg/12 hours was started, combined with antibiotic treatment (levofloxacin 250mg/48 hours plus cefotaxime 1g/24 hours). HZ diagnosis complicated with visceral dissemination was confirmed

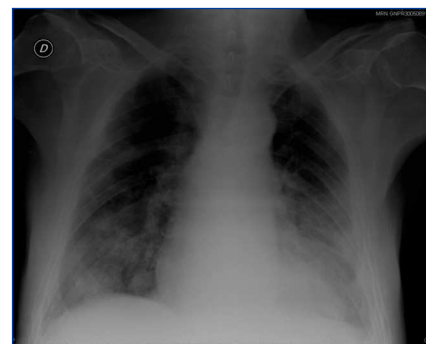


Figure 1. Chest x-ray upon admission

by polymerase chain reaction (PCR) for associated viral DNA, and the remaining study was negative. The patient progressed satisfactorily with acyclovir, including clinical symptoms –recovery from respiratory failure and skin lesions–, radiological symptoms, –the interstitial and alveolar infiltration disappeared– and biochemical parameters (Table 1).

Complications secondary to VZV reactivation are common in immunocompromised patients. Data collected from bone marrow transplant patients show that incidence varies from 17% to 52%, according to different studies.<sup>5,9</sup> For solid organ transplantation there is one retrospective study with a total of 869 patients worth mentioning, which reports an incidence of 8.6%, particularly in lung (15.1%) and kidney transplantation.<sup>3</sup>

Its clinical forms vary: local zoster with or without visceral dissemination, visceral involvement without skin lesion or generalised zoster with no visceral involvement.<sup>1,2</sup> Reactivation takes place from the spinal ganglia; its mechanism is still fairly unknown and presents as the main cause of all forms of HZV. However, there are contradictory data regarding cases secondary to reinfection in the literature.<sup>1</sup>

As in our case, it can coexist with visceral dissemination. Between 3% and 15% of HZ reoccur.<sup>1,3</sup> It presents a high

mortality rate, with studies that show up to 55%<sup>3</sup> in cases secondary to complications such as meningoencephalitis, pancreatitis or fulminant liver failure.<sup>5</sup> After skin, the lung is the most affected organ, followed by the liver.<sup>1,3</sup> Diagnosis is hindered if the skin involvement does not presents before visceral dissemination, as has been shown in a series of negative laparotomies in patients with significant abdominal pain. Three of the 123 cases presented with symptoms of HZV.<sup>7</sup> Therefore, it can present as variable clinical symptoms with a constitutional syndrome associated with symptoms of visceral involvement, abdominal pain due to stretching of the Glisson capsule or pancreatitis, respiratory failure, etc., which is often subsequently clearer, once neuritis and vesicular exanthema –common HZ symptoms– develop.

Diagnosis requires a high clinical suspicion in those patients with previous history of non-disseminated zoster and powerful immunosuppression. Previous clinical background factors that must be highlighted are: immunosuppression, treatment with steroids and/or MMF, and previously positive serology.<sup>3</sup> We did not know the previous serology results for our patient, but among his medical history we found significant immunosuppression due to the underlying condition, in the last stage of MMF and steroid treatment, which immunitary dysfunction caused by the very uraemic state added to.

Diagnosis in immunocompromised patients or atypical symptoms can be confirmed by different laboratory techniques, given that suspected clinical symptoms with positive serology may not be enough to confirm it. Amplification of viral DNA in the blood or vesicular fluid in cases of visceral dissemination is quick, has low contamination risk and is more sensitive than the conventional culture or direct immunofluorescence.<sup>1,6</sup>

In summary, treatment should prevent complications. Given the highly suspected clinical symptoms, specific and early treatment is recommended. Full dose acyclovir seems to be the most effective agent. Treatment duration is still not defined in the literature and it should be combined with wide-spectrum antibiotic treatment to avoid complications due to over infection.<sup>8</sup>

To conclude, visceral dissemination of HZ is a complication of a variable frequency, which has a high morbidity and mortality and requires rapid treatment management based on highly suspected clinical symptoms.

1. Stratman E. Visceral zoster as the presenting feature of disseminated herpes zoster. *J Am Acad Dermatol* 2002;46:771-4.
2. Fuks L, Shitrit D, Fox BD, Amital A, Raviv Y, Bakal I, et al. Herpes zoster after lung transplantation: incidence, timing, and outcome. *Ann Thorac Surg* 2009;87:423-6.
3. Gourishankar S, McDermid JC, Jhangri GS, Preiksaitis JK. Herpes zoster infection following solid organ transplantation: incidence, risk factors and outcomes in the current immunosuppressive era. *Am J Transplant* 2004;4:108-15.
4. Yagi T, Karasuno T, Hasegawa T, Yasumi M, Kawamoto S, Murakami M, et al. Acute abdomen without cutaneous signs of varicella zoster virus infection as a late complication of allogenic bone marrow transplantation: Importance of empiric therapy with acyclovir. *Bone Marrow Transplant* 2000;25:1003-5.
5. O'Loughlin CJ. Visceral varicella zoster after bone marrow transplantation. *An*

**Table 1.** Biochemical evolution

	Admission	Three days of treatment	A week of treatment	Discharge
Leukocytes	4200	5800	5400	6300
GOT/GGT(IU/l)	6926/3587	1451/1223	104/178	48/79
Total bilirubin (mg/dl)/ prothrombin activity	2.17/37%	1.87	1.15	1.07/82%
LDH (IU/l)	3320	578	483	320
Platelets (1000/ $\mu$ l)	84 000	97 000	115 000	142 000
pH/pO <sub>2</sub> /pCO <sub>2</sub>	7.21/59/32			7.53/77/40

GOT: Aspartate transaminase; GGT: Gamma-glutamyl transpeptidase; LDH: Lactate dehydrogenase.

- obscure cause of an "acute abdomen". *Dig Dis Sci* 1964;47(9):1962-4.
- Albrecht MA. Diagnosis of varicella-zoster virus infection. In: Hirsch MS (ed.). *Uptodate*, september 28, 2010.
  - Schiller GJ, Nimer SD, Gajewski SD, Golde DW. Abdominal presentation of varicella zoster virus infection in recipients of allogenic bone marrow transplantation. *Bone Marrow Transplant* 1991;7:481-91.
  - Yagi T, Karasuno T, Hasegawa T, Yasumi M, Kawamoto S, Murakami M, et al. Acute abdomen without cutaneous signs of varicella zoster virus infection as a late complication of allogenic bone marrow transplantation: Importance of empiric therapy with acyclovir. *Bone Marrow Transplant* 2000;25:1003-5.
  - Locksley R, Flournoy N, Sullivan K, Meyers J. Infection with varicella-zoster virus after marrow transplantation. *J Infect Dis* 1985;152:1172-81.

**M.A. Suárez Santisteban,  
M.V. García-Bernalt Funes, M. Mora Mora,  
R.A. Novillo Santano, G. Rangel Hidalgo,  
C. Cebrían**

Nephrology Department.  
San Pedro de Alcántara Hospital. Cáceres,  
Spain.

**Correspondence:** M.A. Suárez Santisteban  
Sección de Nefrología.  
Hospital San Pedro de Alcántara.  
La Higuera, 5, 3.º F. 10004 Cáceres.  
rosami28@hotmail.com  
vgbernal@hotmail.com

## Role of acute tubular necrosis with blood casts during endocapillary proliferative glomerulonephritis

*Nefrologia* 2011;31(5):618-9

doi:10.3265/Nefrologia.pre2011.Jun.10934

### To the Editor,

Post-infectious acute glomerulonephritis can be manifested as a nephritic syndrome. Macroscopic haematuria (MH)

is self-limited and appears in more than half of cases. Kidney failure is due to inflammatory glomerular lesions. On the other hand, some patients with MH as a symptom of IgA nephropathy can undergo certain worsening of renal function due to tubular mechanisms.<sup>1</sup> Recently, nephropathies other than IgA have been reported (vasculitis, Goodpasture syndrome and others) in which kidney failure is not only due to glomerular damage but also tubular lesions caused by intraluminal haematic casts.<sup>2</sup>

We describe the case of endocapillary proliferative glomerulonephritis with haematuria and renal failure and glomerular lesions and intratubular haematic casts.

A 38-year-old female, subjected to laryngeal polypectomy 20 days before, with odynophagia and fever. Three days before being admitted, she felt general discomfort, an itchy rash, haematuria, followed by anuria. Physical examination: blood pressure 98/51mm Hg; pointed exanthema was resolved; other aspects were normal. Biochemical tests showed: hypochromic anaemia, with no haemolysis data. Creatinine: 8.1mg/dl; urea: 166mg/dl; protein/creatinine ratio: 1.3g/g and sediment with uncountable red blood cells. Normal immunoglobulins. Negative antinuclear antibodies (ANA), anti-DNA, C3, C3, C4 and antistreptolysin O (ALSO) antibodies. Normal chest ultrasound.

Given that renal function rapidly deteriorated, he received steroid treatment

(in bolus and orally [p.o.] and haemodialysis). The renal biopsy found: 17 glomeruli, diffuse endocapillary hypercellularity and neutrophils in capillary lumens, epithelial crescents in two glomeruli. Interstitial space with frequent haematic casts and epithelial space with denudate haematic casts (Figure 1). Immunofluorescence, mesangial deposits and in capillary walls of C and IgM (endocapillary proliferative glomerulonephritis).

The patient progressed favourably, as shown in Figure 2, and renal function fully recovered.

Our patient therefore had an acute endocapillary glomerulonephritis, possibly post-infectious, discovered with macroscopic haematuria and acute kidney failure. For most renal biopsies, the key areas of study are the interstitial and tubular spaces, and they are analysed in detail. However, it is necessary to seek the presence of intratubular haematic casts as the cause of tubular necrosis, which can add to massive extracapillary proliferation or vasculitis. In our case, glomerular lesions justify acute renal failure, but tubular necrosis, given the advanced stage, has possibly played a more important role.

The physiopathology of the renal function disorder in MH patients is not fully understood, especially if we take into account the fact that not all haematuria episodes are associated with acute renal failure. Iron and haemoglobin poisoning, together with tubular obstruction are the main mechanisms,<sup>3,4</sup> favoured

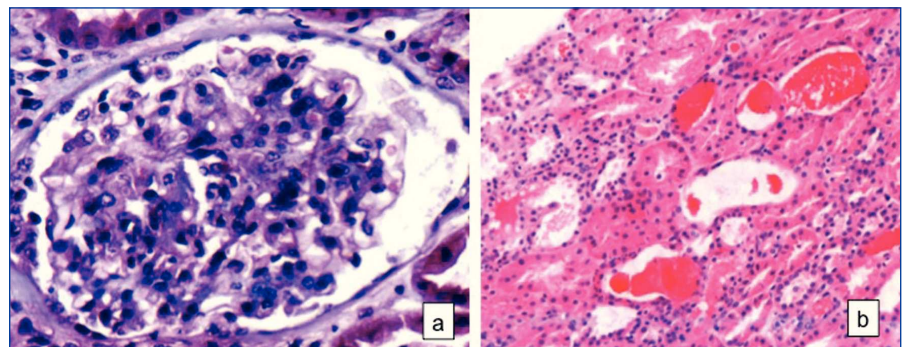


Figure 1.