

**T. Monzón Vázquez, A. Rodríguez Moreno, P. Delgado Conde, J. Delgado Domínguez, A. Gomis Couto, A. Barrientos Guzmán**

Nephrology Department,  
San Carlos Hospital Clinic, Madrid, Spain.

**Correspondence:** Tania Monzón Vázquez  
Servicio de Nefrología.  
Hospital Clínico San Carlos. Madrid. Spain.  
taniarmv@msn.com

### Supernumerary kidney

Nefrología 2010;30(1):142

#### Dear Editor,

We report the case of a 40 year-old patient with no urological history, who was admitted to our department because of pain in left kidney fossa, microhaematuria and pyuria. An examination showed tenderness in the left kidney fossa. The simple radiograph showed a radiopaque image in the left ureteral tract, compatible with calculi. With the clinical, laboratory and imaging data a left renoureteral crisis was diagnosed. In the antegrade pyelography, which confirmed the diagnosis, we observed a

smaller kidney with its own collection system in the cranial region of the left kidney, independent of the ipsilateral one (Figure 1).

The supernumerary kidney is the rarest of kidney malformations. It is always small and usually located caudal to the ipsilateral one, independent from it by its capsule and with its own irrigation and collecting system.<sup>1,2</sup> It does not usually cause any symptoms until adulthood when it can generate pain, hypertension,

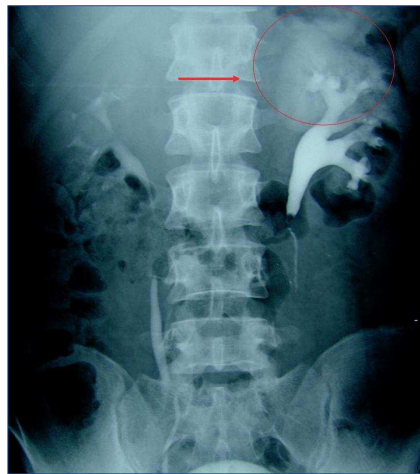


Figure 1. IV Urography

etc. It can occur in association with other diseases such as VATER syndrome<sup>3</sup> or cardiological anomalies.<sup>4</sup> The treatment will be the corresponding for the accompanying processes.

1. Sy WM, Seo IS, Sze PC, et al. A patient with three kidneys: a correlative imaging case report. Clin Nucl Med 1999;24:264.
2. Kawamura T. Supernumerary kidney. Ryoikibetsu Shokogun Shirizu 1997;16:354.
3. Moses KA, Kirsch AJ, Heiss EA, et al. Supernumerary kidney in a term infant with VATER association. Am Surg 2008;74:874.
4. Unal M, Erem C, Serçe K, et al. The presence of both horseshoe and a supernumerary kidney associated with coarctation of aorta. Acta Cardiol 1995;50:155.

**M.A. Arrabal Polo, A. Jiménez Pacheco, M. Arrabal Martín**

Urology Department. San Cecilio University Hospital, Granada, Spain.

**Correspondence:**

Miguel Ángel Arrabal Polo  
Camino de Ronda, 143, 4.º F. 18003  
Granada. Spain.  
arrabal@ono.com

#### ERRATA

In the special edition, volume 29 number 5 "**Actualizaciones en Nefrología 2009**", the authors included are incorrect. The correct authors are the following:

- In the Table of Contents, under the heading: **Manejo del paciente hipertenso anciano y muy anciano a la luz de las evidencias actuales**, the authors mentioned are: G. Fernández Fresnedo, M. Gago Fraile, They should be named: G. Fernández Fresnedo, J.M. Galcerán, M. Gorostidi, M. Gago Fraile.
- In chapter: "**Manejo del paciente hipertenso anciano y muy anciano a la luz de las evidencias actuales**" the authors mentioned are: G. Fernández Fresnedo, M. Gago Fraile, They should be named: G. Fernández Fresnedo, J.M. Galcerán, M. Gorostidi, M. Gago Fraile.
- In the Table of Contents, under the heading: **¿Hasta dónde con el bloqueo del sistema renina-angiotensina-aldosterona? ¿Qué aportan los nuevos fármacos y las nuevas combinaciones entre ellos en el tratamiento de la hipertensión arterial?**, the authors mentioned are: J.M. Galcerán, They should be named: J.M. Galcerán, M. Gorostidi, G. Fernández Fresnedo.
- In chapter: "**¿Hasta dónde con el bloqueo del sistema renina-angiotensina-aldosterona? ¿Qué aportan los nuevos fármacos y las nuevas combinaciones entre ellos en el tratamiento de la hipertensión arterial?**", the authors mentioned are: J.M. Galcerán, They should be named: J.M. Galcerán, M. Gorostidi, G. Fernández Fresnedo.

We apologize to the journal's authors and readers affected.