

B) BRIEF PAPER ON RESEARCH AND CLINICAL EXPERIMENTS

The importance of early diagnosis to the prognosis of immune-complex tubulointerstitial nephritis

Nefrología 2009;29(3):274.

Dear Editor:

Immune-complex tubulointerstitial nephritis (immune-complex TIN) is a frequent disease, causing 20-40% of all cases of chronic kidney disease (CKD) and from 10 to 25% of acute renal failure (ARF).¹

In most cases, immune-complex TIN is caused by drugs, with antibiotics being the most frequent agents.¹ Allopurinol causes this type of nephritis in 1.2% of all cases.² Treatment consists of discontinuing the medication causing the condition³ and prescribing steroids; this last step is widely debated.⁴ We present the case of a woman aged 79 years with chronic arterial hypertension being treated with ARBs who received treatment with allopurinol. Two weeks after beginning this treatment, she was brought to the emergency room due to fever, general malaise and oligoanuria that had been evolving over a week, together with a diffused rash that had appeared in the previous 24 hours. Upon admission, her blood pressure was 100/50mmHg and she had foveal oedema up to the proximal ends of extremities. The analysis that was carried out showed normocytic and normochromic anaemia,

eosinophilia of 767×10^3 eosinophils/ml, plasma creatinine of 8.13mg/dl, plasma urea of 203mg/dl, normal ionogram, no proteinuria and the presence of microhaematuria and eosinophilia in urine elements and sediment. Viral serology and immunology tests were negative. The abdominal Doppler ultrasound did not show pathological findings. Given a clinical profile of acute renal failure with a rash, fever and eosinophilia, together with the history of treatment with allopurinol two weeks before, the clinical diagnosis of immune-complex TIN was established; allopurinol was discontinued and steroid treatment begun (1mg/kg/day). The patient required a haemodialysis session. Subsequently, renal function underwent progressive improvement, for which reason a biopsy was not taken. The patient was discharged 10 days later with normal renal function.

Immune-complex TIN is frequent in clinical practice, accounting for 20-40% of cases of CKD and 10-25% of cases of acute renal failure.¹ In most cases, immune-complex TIN is caused by medications.¹ Its classic triad of a rash, fever and eosinophilia is only present in 10% of all cases.⁵ Its sure diagnosis is histological,^{1,5} but it was not performed in our case due to the patient's rapid improvement. The prognosis is good if the medication is discontinued early.² Debate exists regarding treatment with steroids,⁴ although numerous studies attest to the role they play in this pathology.³

In conclusion, we stress the importance of carrying out an exhaustive clinical history so as to be able to make the clinical diagnosis of immune-complex TIN, discontinue the medication in question at an early stage and begin steroid treatment as soon as possible, which seems to improve the patients' renal prognosis.

1. Eknoyan G. Tubulointerstitial nephropathies. In: Massry and Glasscock's (eds.). Textbook of Nephrology. 4th edition. Philadelphia: Lippincott Williams and Wilkins; 2001.
2. McInnes GT, Lawson, DH, Jick H. Acute adverse reactions attributed to allopurinol in hospitalized patients. *Ann Rheum Dis* 1981;40:245.
3. González E. Early steroid treatment improves the recovery of renal function in patients with drug-induced acute interstitial nephritis. *Kidney Int* 2008;73(8):940-6.
4. Praga M. Response to "Steroid in acute interstitial nephritis". *Kidney Int* 2008;74:972-3.
5. Baker RJ, Pusey CD. The changing profile of acute tubulointerstitial nephritis. *Nephrol Dial Transplant* 2004;19:8.

T.R. Monzón Vázquez,
R. Valero San Cecilio, I. Úbeda Aranda,
A. Barrientos Guzmán
Nephrology Department.

San Carlos Clinical Hospital. Madrid, Spain.

Correspondence: Rosalía Valero San Cecilio
Servicio de Nefrología.

Hospital Clínico San Carlos. Madrid.
rosaliavalero@yahoo.es

C) BRIEF CASE REPORTS

Atheroembolism in transplanted kidney

Nefrología 2009;29(3):274-275.

Dear Editor:

We would like to present the clinical case of a male patient 64 years of age with a transplanted kidney. He was admitted for study of asymptomatic deterioration of the transplanted organ's function.

Patient history: arterial hypertension, type-2 diabetes mellitus, dyslipidaemia, severe peripheral vasculopathy, ischaemic cardiopathy.

Advanced chronic kidney disease secondary to cholesterol atheroembolism following a carotid endarterectomy in a periodical haemodialysis programme (PHD). First transplant failed due to intraoperative renal venous thrombosis.

Recipient of second kidney transplant (baseline creatinine 1.8mg/dl). Donor: female 59 years of age with no associated Cardiovascular Risk Factors (CRFs).

Recent history: 15 months after the transplant, a decrease in renal function was detected in a routine check-up. There were no changes to the diuresis rhythm, nor was there any consumption of nephrotoxins or any recent invasive diagnostic procedures.

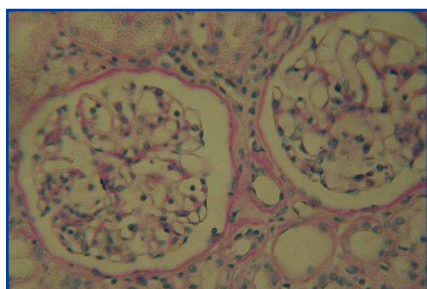


Figure 1. Renal biopsy of transplanted organ showing two glomeruli with intact structure and a significant level of tubular atrophy (haematoxyline-eosin stain).

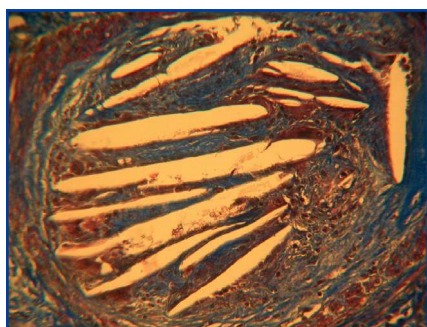


Figure 2. Renal biopsy of transplanted organ with a transversal slice of arcuate artery where we observe the impact of multiple cholesterol crystals (Masson's trichrome stain).

Complementary tests:

Analytical tests: plasma creatinine 5.5mg/dl, urea 131mg/dl, leukocytosis, normochromic normocytic anaemia, metabolic acidosis and elevated systemic inflammation parameters.

Doppler ultrasound: 12cm kidney, thin cortex, normal resistance indexes.

Renal biopsy: five glomeruli with structure intact, without cellular alterations. Permeable capillaries. Tubular atrophy. In arcuate artery 100 micra in diameter, multiple cholesterol crystals occluding the vessel lumen. In the surrounding area, giant multinuclear cells and histiocytes.

Given with the irreversibility of the lesions and the persistence of creatinine clearance under 10ml/min, the patient resumed PHD.

Discussion

The cause was a spontaneous cholesterol atheroembolism in a patient with multiple CRFs and a previous episode of atheroembolism after an emergency treatment procedure. The literature states that in both transplanted and native kidneys, when there is no clear trigger factor and no symptoms on other levels, cholesterol atheroembolism is an occasional finding of a renal biopsy.¹⁻⁵

Much data shows atheroembolism to be a cause of acute and sub-acute renal failure, and it is associated with a poor vital prognosis in affected patients.^{1,2,5} It is still an under-diagnosed condition, and in many cases can present as an asymptomatic decrease in kidney function. In some series, it is found in 12% of all autopsies of patients with severe atherosclerosis.² There is little published data on atheroembolism in transplanted kidneys.^{3,4}

The reviews by Ripple and Takats give a poorer prognosis to patients with early presentation of the atheroembolic event, just after the transplant or in the first year following it; most of these patients lose the transplanted organ.^{3,4} For many of these patients, the source of the embolism is considered to be the donor, most of whom are older and have associated CRFs, and often receive multiple organ donations. Late cases are associated with a better prognosis, and frequently part of the renal function is recovered. However, our patient suffered a severe initial damage and lost the transplanted organ.

Cholesterol atheroembolism should be considered in the differential diagnosis of asymptomatic decrease in the function of a transplanted kidney.

1. Meyrier A. Cholesterol crystal embolism: diagnosis and treatment. *Kidney Int* 2006;69:1308-12.
2. Cross SS. How common is cholesterol embolism? *J Clin Pathol* 1991;44:859-61.

3. Thadhani R, Camargo C, Xavier R, et al. Atheroembolic renal failure after invasive procedures. Natural history based on 52 biopsy-proven cases. *Medicine* 1995;74:350-8.
4. Belefant X, Meyrier A, Jacquot C. Supportive treatment improves survival in multivisceral cholesterol crystal embolism. *Am J Kidney Dis* 1999;33:840-50.
5. Jucgla A, Moreso F, Muniesa C, Moreno A, Vidaller A. Cholesterol embolism: still an unrecognized entity with a high mortality rate. *J Am Acad Dermatol* 2006;55:786-93.

I. Aragoncillo, M.L. Rodríguez, E. Niembro, M. Rengel, U. Verdalles, F. Anaya

Nephrology Department. HGU Gregorio Marañón. Madrid, Spain.

Correspondence:

Inés Aragoncillo Saucó
 Servicio de Nefrología. HGU Gregorio Marañón. Madrid.
 inesiglia@hotmail.com

Sudden death in patient with cholesterol atheroembolism

Nefrología 2009;29(3):275-276.

Dear Editor:

Cholesterol Embolism (CE) is a serious complication of invasive intravascular processes and anti-coagulation treatments in patients with arteriosclerosis and ulcerated aortic plaques. In addition to affecting the kidney, cholesterol crystals may also affect small-diameter arteries in other areas, such as the central nervous system, the coronary arteries, the mesentery, and the pancreas, damage to which is one of the principal causes of mortality in these patients.¹

A male patient aged 78 years had a personal history of chronic kidney disease that was probably secondary to arterial hypertension and diabetes mellitus (baseline serum creatinine 1.5mg/dl), was a former smoker and had hypercholesterolaemia. In February 2007 he was diagnosed with ischaemic cardiopathy with a severely diseased vessel, and an angioplasty was performed