

diabetic nephropathy. The early course after renal transplantation was without complications. The graft achieved good renal function 7 days after the procedure and serum creatinine was 1.4 mg/mL.

In the follow-up the patient referred non-specific abdominal pain, mainly hypogastric two months after the transplantation. A computerized tomography (CT) scan was performed that revealed air collection in the inner wall of the bladder,¹ with no alterations in of the graft (fig. 1). The patient referred no other symptoms, except urinary tract infection that was treated with ertapenem for two weeks. Twenty days later a new CT scan was performed that showed a normal bladder with no evidence of air collection. The patient had an indwelling urinary catheter for two weeks, which was removed once the radiological image was normal.

DISCUSSION

Emphysematous cystitis is a rare complication of urinary tract infection, characterized by the spontaneous appearance of gas within the bladder wall or in the bladder. Fifty percent of the patients have diabetes and 62.2% are women. Other risk factors are neurogenic bladder and recurrent urinary tract infections.³ The mechanism for the gas formation is unknown, but several hy-

pothesis have been postulated, one of them being glucose fermentation in the urine. Symptoms present only in 53.3% of the cases. The most frequent ones are abdominal pain (65%) and hematuria (82%). Other less frequent complaints are fever, chills, nausea and vomiting. In patients with renal transplantation emphysematous cystitis is not very usual although there is a great percentage of patients with diabetes who undergo this procedure. *E. Coli* and *Klebsiella pneumoniae*, both capable of producing gas, are the commonest etiological agents. The prognosis is usually good with antibiotics and glycemic control,² except in those patients who present systemic organic dysfunction. Treatment duration depends on the clinical response, but antibiotics are necessary during a mean of 10 days.⁴

A high index of suspicion should be maintained, especially in patients with diabetes that present urinary tract infection, in order to treat the infection as soon as possible to avoid systemic involvement, for example bacteriemia, that develops in 54% of the patients. A plane abdomen X-ray film and/or an abdominal CT scan⁵ are enough to rule out this condition.

1. Tang SC, Chu FS, Au WM, Lai KN. Emphysematous cystitis. *Am J Kidney Dis* Aug; 48 (2): e 11-2, 2006.
2. Bobba RK, Arsuru EL, Sarna PS, Sawh AK. Emphysematous cystitis: an unusual disease

of the genito-urinary system suspected on imaging. *Ann Clin Microbiol Antimicrob* Oct 5; 3: 20, 2004.

3. Akalin E, Hyde C, Schmitt G, Kaufman J, Hamburger RJ. Emphysematous cystitis and pyelitis in a diabetic renal transplant recipient. *Transplantation* Oct 15; 62 (7): 1024-6, 1996.
4. Grupper M, Krautsov A, Potasman I. *Medicine* (Baltimore) Jan; 86 (1): 47-53, 2007.
5. Mokkaabberi R, Ravakhah K. Emphysematous urinary tract infections: diagnosis, treatment and survival. *Am J Med Sci* Feb; 333 (2): 111-6, 2007.

V. González-Martín, E. Rodrigo, M. Arias and P. Lastra
Nephrology and Radiology Departments. Marqués de Valdecilla University Hospital. Santander.

Correspondence: Victoria González Martín. vglezmartin@hotmail.com. Hospital Universitario Marqués de Valdecilla. Av. Vandecilla, s/n. 39008 Santander

Effect of macrobiotic diet on the progression of diabetic nephropathy: a propos of a case

Nefrología 2008; 28 (1) 111-112

To the Editor: There are some reports in the literature pointing out that the progression of the diabetic nephropathy (DN) is slower in patients who take low protein diets.^{1,2} Macrobiotic diet is an extreme form of vegetarianism that had showed to be useful in the prevention and in the treatment of some tumors. To date it has not been reported that this diet can slow down the progression of the DN.

We present a 58 year-old Caucasian male, with a history of high blood pressure since 1990 regularly controlled with antihypertensives drugs, and of type 2 diabetes mellitus since 1998, treated with insulin and with good metabolic control. He was referred to the Nephrology Department in 2000 because of stage 2 chronic renal failure (CRF) and microalbuminuria secondary to DN. He was being treated with irbesartan 300 mg/day, hydrochlorotiazide 12,5 mg/day, nifedipine 60 mg/day and salicylic acid 100 mg/day. During the follow up the renal function worsened lightly and he had normo-albuminuria. In December of 2005 the following measurements were made: blood

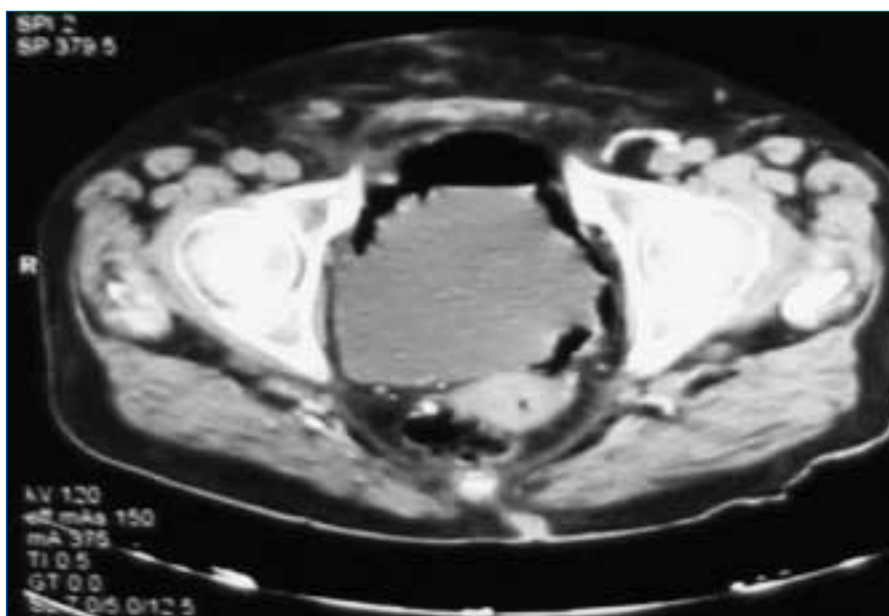


Figure 1.

pressure 139/87 mmHg, weight 81 kg, and height 180 cm. The laboratory parameters were urea 61 mg/dL, creatinine 1.7 mg/dL, creatinine clearance 44.37 mL/min, microalbuminuria 11.75 µg/min and hemoglobin A1c 5.5. Other parameters were normal. In January of 2006 the patient began a macrobiotic diet, consisting of wholemeal cereals, like barley and wheat, see algae, and vegetables. He avoided eating meat, milk or milk derivatives. In October of 2006 he had blood pressure 138/82 mmHg and weight 79 Kg. Laboratory findings were urea 46 mg/dL, creatinine 1 mg/dL, creatinine clearance 81.57 mL/min, microalbuminuria 29.31 µg/min, hemoglobin A1c 5.9, albumin 4.2 g/dL, total proteins 6.7 g/dL, total cholesterol 150 mg/dL, triglycerides 168 mg/dL, and the other parameters were normal. These findings were similar in further analyses three and six months later. He did not appear malnourished. No changes in the treatment were prescribed and no other cause could be found to explain the improvement in renal function.

Macrobiotic diet is an extreme form of vegetarianism combined with some thoughts derived from Buddhist Zen philosophy. Eating and quality of food are thought to affect the health.³ Macrobiotic diet emphasizes the use of organic products, like cereals, fruits, algae, vegetables, fermented soy, combined according to the principles of the balance between the yin and yang properties.⁴ Some reports demonstrate the anti-tumoral effect, particularly in breast tumors. Women who make a macrobiotic diet apparently excrete a greater amount of estrogens in stool and urine, have lower blood levels of estradiol and have lower risk of developing a breast carcinoma.^{5,6} Some studies about the macrobiotic diet as treatment of different neoplasms, like melanoma or pancreas cancer, have been published. An improvement of the clinical picture and of the quality of life of the patients was observed.^{6,7}

The effect of macrobiotic diet in diminishing cardiovascular risk has been reported.^{8,9} An improvement in total cholesterol, an increase in HDL-cholesterol and an improvement in blood pressure were demonstrated, but no effect on the progression of the DN could be showed.

The potential danger of the diet is

that if strictly followed can cause malnourishment, anemia due to vitamin B₁₂ deficiency and scurvy.¹⁰

The reported patient presented a -CRF secondary to DN of six years. After 10 months of macrobiotic diet an improvement in renal function was observed, without signs of malnourishment and no other cause could be found to explain this improvement.

1. Henrik P Hansen, Per K. Christensen, Ellis Tauber-Lassen, Annalise Klausen, Berit R Jensen, Hans-Henrik Parving. Low-protein diet and kidney function in insulin-dependent diabetic patients with diabetic nephropathy. *Kidney International* 55: 621-628, 1999.
2. Henrik P Hansen, Ellis Tauber-Lassen, Berit R Jensen, Hans-Henrik Parving. Effect of dietary protein restriction on prognosis in patients with diabetic nephropathy. *Kidney International* 62: 220-228, 2002.
3. Kushi M, Jack A. The book of Macrobiotics. The universal way of health, happiness and peace. Japan Publications, New York, 1986.
4. Kushi M, Jack A. One peaceful world: Michio Kushi's approach to creating a healthy and harmonious mind, home and world community. St martin's Press. New York, 1987.
5. Goldin BR, Adlercreutz H, Gorbach SL, Warram JH, Dwyer JT, Swenson L, Woods MN. Estrogen excretion patterns and plasma levels in vegetarian and omnivorous women. *N England J Med* 307: 1542-1547, 1982
6. Kushi LH, Cunningham JE, Hebert JR, Lerman RH, Bandera EV, Teas J. The macrobiotic diet and cancer. *The Journal of Nutrition* 131, 11S: S3056-S3063, 2001.
7. Faulkner, H. Physician, heal thyself, one peaceful world press. Becket, MA, 1993.
8. Sacks F, Castelli W, Donner P, Kass EH. Plasma lipids and lipoproteins in vegetarians and controls. *N England J Med* 292: 1148-1151, 1975.
9. Sacks F, Ornish D, Rosner B, Mc Lanan S, Castelli W, Kass EH. Plasma lipoprotein levels in vegetarians. The effect of ingestion of fats from dairy products. *J Am Med Assoc* 254: 1337-1341, 1985.
10. Roberts IF, West RJ, Ogilvie D and Dillon MJ. Malnutrition in infants receiving cults diets: a form of child abuse. *Br Med J* 1: 296-298, 1979.

O. Costero, F. De Álvaro, S. Romero and R. Selgas

Nephrology Department. La Paz University Hospital. Madrid.

Correspondence: Olga Costero Fernández olgacostero@hotmail.com. Hospital Universitario La Paz. Paseo de la Castellana, 261. 28046 Madrid.

Acute renal failure due to carnitine palmitoyl transferase deficiency

Nefrología 2008; 28 (1) 112-113

To the editor: We present a male, who developed severe rhabdomyolysis after an infectious episode leading to acute oliguric renal failure that required hemodialysis. He was 18 years old and had a history of febrile episodes in the childhood and tonsillectomy. He referred «dark-colored urine after strenuous efforts» and consumed no toxics.

He was evaluated at the Emergency Room because of generalized muscle pain and odynophagia. Physical examination was unremarkable except for hyperemic pharynx and intense pain on muscle palpation.

Laboratory parameters were: Biochemistry: Urea 49.6 mg/dL, Cr 2.05 mg/dL, Na 132 mEq/L, K 4.9 mEq/L, ionic calcium 4 mEq/L, uric acid 4.5 mg/dL, CK 285.390 U/L; CK-MB 4353 U/L. Arterial blood gas analysis: pH 7.40; pCO₂ 33 mmHg; HCO₃ 20 mmol/L; PO₂ 98 mmHg, Sat 97.4%. Blood cell counts: Hb: 17.5 g/dL; hematocrit: 47.6%; MCV: normal, leucocytes: 13.210 (neutrophils: 88%), other parameters were normal. Urine: density 1010; pH: 5.5, leucocytes 25/ul; erythrocytes > 300 and normal sediment. Ions in urine: Na 77; K 25; FENa < 1. Toxics in urine: negative.

Renal ultrasound was normal. The scintigraphy showed abnormal distribution of radiotracer with intense deposits in the muscles of the thorax, abdomen and extremities (fig. 1). A diagnosis of acute renal failure due to severe rhabdomyolysis of unknown origin was made and the patient was admitted to the hospital. Treatment was initiated with intravenous fluid therapy, urine alkalization and mannitol. Forty-eight hours later he developed progressive increase of creatinine values to 5.3 mg/dL, oliguria and cardiac failure and hemodialysis was performed. A total of 6 sessions were required. In the 9th day the patient recovered diuresis. He was discharged with polyuria and decreasing creatinine.

Posttraumatic, ischemic, toxic, infectious, endocrine and immunological etiologies were ruled out. A muscle biopsy