

preferred vascular access because it is associated to lower risks and complications (15% of mechanical, infectious or thrombotic complications). The most frequent mechanical complications are arterial puncture and secondary hematoma. By contrast, hemothorax and pneumothorax incidence is lower than 0,0.2% and it happens immediately after the puncture.²

We present a 72 year-old woman with a history of high blood pressure and CRF secondary to nephroangiosclerosis in on hemodialysis since 2000. The patient had a permanent catheter in within the right jugular vein, which was placed 5 years ago. The catheter was non-functioning, permeation was not possible with the use of urokinase and the catheter had to be removed. Due to the lack of an internal vascular accesses, a temporary catheter, which was shorter than usual (16 cm instead of 19 cm), was placed in the left jugular vein. An X-ray film confirmed that the catheter was appropriately placed. Nineteen days later it was removed because it did not work properly and was changed by means of a metal wire (16 cm). No radiological control was made. During the following hemodialysis sessions the catheter flow was always lower than 200 mL/min, and the catheter was repeatedly manipulated.

The patient came 29 days later to hemodialysis referring dyspnea and pain in on her right scapula. At the beginning of the session clear fluid was obtained through the arterial branch and hematic fluid through the venous branch. A chest X-ray film was made (fig. 1), which showed right pleural effusion. Dialysis was performed without heparin through a right femoral access. Fifteen minutes after the end of hemodialysis the patient referred sudden right chest pain and dyspnea and she suffered cardiopulmonary arrest. On physical exam right pulmonary hypoventilation was evident. A decrease of hemoglobin value was detected on blood analysis, and the right pulmonary field was opaque on chest X-ray. The diagnosis of massive hemothorax was suspected, a drain tube was placed and resuscitation maneuvers were initiated. The patient was referred to the ICU, where she spent 72 hours and after that

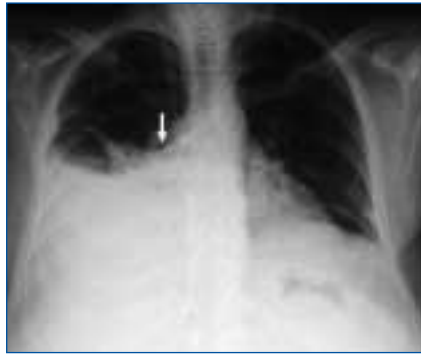

Figure 1. Chest X-ray showing right pleural effusion due to impaction of the left jugular catheter within the pleural space.

she was admitted to our Department with no consequences.

Internal jugular vein catheterization is not free from complications. Massive hemothorax is not frequent, occurs immediately after the puncture and commonly after catheterization of the subclavian vein. In the reported case, hemothorax happened 29 days after catheterization of the vascular access. That was due to the removal of the left jugular catheter, that was occluding a fistula created by the impact of the catheter.

Several facts were determinants for perforation into the interpleural space:³ canalization of the left jugular vein instead the right one (that was occupied by a permanent catheter, which had to be removed), the replacement by a short catheter (16 cm) and the various manipulations of the catheter because of the low flow. Massive hemothorax was the consequence of the catheter removal, and perhaps this procedure should have been done with some precautions (removal in the ICU).

The widespread use of catheters for hemodialysis in patients with difficult vascular accesses increases the morbimortality. It is mandatory the referral of the patient to the nephrology department, and the cooperation of vascular surgeons and radiologists to achieve appropriate vascular accesses.

A radiological control should be made after catheterization and replacement of the catheter to assess the correct position and the lack of complications, although some authors do not agree with this measure.⁴

In summary, when placing temporary catheters the appropriate length, the correct position after placement and replacement should be considered, and manipulations should be avoided.

1. Ruesch S, Walder B, Tramer MR. Complications of central venous catheters: internal jugular versus subclavian access - A systematic review. *Crit Care Med* 30 (2): 454-460, 2002.
2. McGee DC, Gould MK. Preventing complications of central venous catheterization. *N Engl J Med* 348 (12): 1123-33, 2003.
3. Merino JL, Galeano C, Chinchilla A, Sánchez J. Impactación de un catéter permanente tunelizado para hemodiálisis en la vena yugular, una complicación excepcional. *Nefrología* 26 (3): 395-6, 2006.
4. Lucey B, Varghese JC, Haslam P, Lee MJ. Routine Chest Radiographs after central line insertion: mandatory postprocedural evaluation or unnecessary waste of resources? *Cardiovasc Intervent Radiol* 22 (5): 381-4, 1999.

P. Fraile, P. G. Cosmes, V. García-Bernalt and J. M. Tabernero
Nephrology Department. University Hospital of Salamanca.

Correspondence: Pilar Fraile Gómez
pilarfg9@hotmail.com. Hospital Universitario de Salamanca. Paseo de San Vicente, 58. 37007 Salamanca.

Renal failure secondary to lymphoplasmocytic lymphoma-Waldenström's macroglobulinemia

Nefrología 2008; 28 (1) 116-117

To the editor: Waldenström's macroglobulinemia (WM) is a lymphoproliferative disease characterized by the secretion of an IgM type monoclonal immunoglobulin. It occurs in patients with lymphoplasmocytic lymphoma and also in patients with other small B cell lymphomas. Typically, there is a lymphoplasmocytic infiltration of the bone marrow, lymph nodes, spleen, and occasionally of other tissues and organs like the kidney. Whether lymphoplasmocytic lymphoma and WM are the same condition is subject to controversy.^{1,2}

Renal disease is basically due to IgM depositions in glomerular basal mem-

brane and renal infiltration with lymphocytes or plasmacytoid cells.³ Despite this, renal failure is infrequent.

We present a 74 year-old male who was admitted to the Nephrology Department with a diagnosis of exacerbated chronic renal failure that required emergency hemodialysis. He went to the Hospital because of malaise, asthenia, diarrhea and nausea in the last five months. He had been evaluated at the Gastroenterology Department for 3 months and the creatinine value was 2 mg/dL. On physical exam he was pale, had cardiac arrhythmia, basal pulmonary hypoventilation, jugular ingurgitation, hepatomegaly, and edemas in both legs. In blood analysis anemia, thrombocytopenia, nitrogen retention (Creatinine 13 mg/dL) and metabolic acidosis were detected. ESR, IgM gammaglobulin and Kappa chains values were also elevated. A «rouleaux» phenomenon was seen. In urine there was no excretion of light chains. Bone marrow aspirate and biopsy disclosed infiltration of lymphocytes with plasmacytoid differentiation. The immunological study by means of flow cytometry was compatible with lymphoplasmocytic lymphoma. Renal biopsy showed: 22 histologically normal glomeruli and 3 sclerosed glomeruli. There was infiltration of the interstitium with small size atypical lymphocytes, plasmacytoid lymphocytes and plasma cells, which markedly widened the renal interstitium (fig. 1). By immunohistochemistry malignant cells were found to be positive for anti-CD20 and anti-CD3 anti-sera.

The etiology of WM is unknown but somatic mutations and chromoso-

mal abnormalities of malignant B cell are present. Surface antigens expressed in atypical lymphocyte are mainly CD19, CD20, CD24 and light chain kappa.⁴ The clinical picture is similar to other malignant conditions with general syndrome, night sweating, fever, together with symptoms derived from organ involvement due to tumoral infiltration, IgM or amyloid protein deposition or hyperviscosity syndrome.^{1,3,5} The following renal manifestations have been described: glomerulonephritis, due to IgM or cryoglobulins depositions and nephrotic syndrome, commonly secondary to amyloidosis or to IgM thrombi within the glomerular capillaries.⁶⁻⁹

In the reported case, the patient presented with general and digestive symptoms, and renal failure without proteinuria, which prompted the decision to perform a renal biopsy. The pathological examination of the sample revealed interstitial renal infiltration with lymphoplasmocytic lymphoma with no IgM depositions.

We consider that this case is interesting because of the presence of renal failure, which is infrequent in this condition, and also because of the lack of proteinuria, probably due to lymphocytic infiltration of the interstitium that did not affect the glomeruli.

The patient initiated chemotherapy with chlorambucil and prednisone and he was maintained in on chronic hemodialysis until he died nine months after the diagnosis.

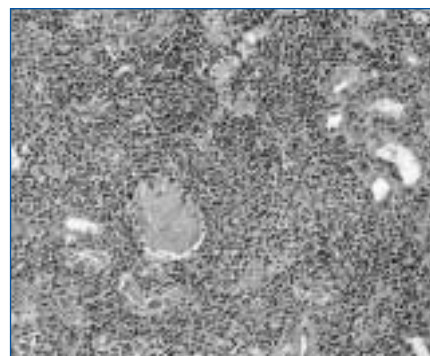


Figure 1.

1. Pangalis GA, Kyrtsonis MC, Kontopidou FN, Vassilakopoulos TP. Differential diagnosis of Waldenstrom's macroglobulinemia from other low-grade B-cell lymphoproliferative disorders. *Semin Oncol* 30 (2): 201-205, 2003.
2. Berger F, Traverse-Glehen A, Felman P, Callet-Bauchu E. Clinicopathologic features of Waldenstrom's macroglobulinemia and marginal zone lymphoma: are they distinct or the same entity? *Clin Lymphoma* 5 (4): 220-224, 2005.
3. Veltman GA, Van Veen S, Kluin-Nelemans JC, Bruijn JA. Renal disease in Waldenstrom's macroglobulinemia. *Nephrol Dial Transplant* 12: 1256-1259, 1997.
4. Jensen GS, Andrews EJ, Mant MJ, Vergidis R. Transitions in CD45 isoform expression indicate continuous differentiation of a monoclonal CD5+CD11b+B lineage in Waldenstrom's macroglobulinemia. *Am J Hematol* 37 (1): 20-30, 1991.

5. Dimopoulos MA, Panayiotidis P, Mouloupoulos LA, Sfikakis P. Waldenstrom's macroglobulinemia: clinical features, complications and management. *J Clin Oncol* 18 (1): 214-226, 2000.
6. Isaac J, Herrera GA. Cast nephropathy in a case of Waldenstrom's macroglobulinemia. *Nephron* 91 (3): 512-515, 2002.
7. Harada Y, Ido N, Okada T, Otani M. Nephrotic syndrome caused by protein thrombi in glomerulocapillary lumen in Waldenstrom's macroglobulinemia. *Br J Haematol* 110 (4): 880-883, 2000.
8. Haraguchi S, Tomiyoshi Y, Aoki S, Sakemi T. Nephrotic syndrome due to immunologically mediated hypocomplementic glomerulonephritis in a patient of Waldenstrom's macroglobulinemia. *Nephron* 92 (2): 452-455, 2002.
9. Muso E, Tamura I, Yashiro M, Asaka Y. Waldenstrom's macroglobulinemia associated with amyloidosis and membranous nephropathy. *Nippon Jinzo Gakkai Shi* 35 (11): 1265-1269, 1993.

E. Jiménez Víbora, A. I. Martínez Puerto, J. A. Milán Martín and J. R. Armas Padrón
Nephrology Department. Pathology Department. Virgen Macarena University Hospital of Seville.

Correspondence: Elena Jiménez Víbora ejvibora@hotmail.com. Centro de Diálisis Sierra Este. Avda. de la Innovación, 2. Edificio Sierra Este. 41020 Sevilla.

Intoxication with *Averrhoa carambola* in a patient on chronic dialysis

Nefrología 2008; 28 (1) 117-118

To the editor: Patients frequently believed that natural products are harmless and that they have many curative and regenerative functions. The star fruit (scientific name *Averrhoa carambola*; See figure) is a widespread fruit in several regions of Central America, South America and above all, in Asia, where it is thought that the star fruit comes from. For some years the fruit is also in the markets of Europe and the United States, where it is considered an exotic fruit. Renal insufficiency is an increasingly prevalent medical condition. In patients with renal insufficiency star fruit intake has been causally related with severe neurotoxicity, that was the cause of death in a few patients. We present a case seen at our center.