

- Asif A, Cheria G, Merrill D, Cipleu CD, Takwakol JB, Epstein DL, Lenz O. Venous mapping using venography and the risk of radiocontrast-induced nephropathy. *Semin Dial* 2005; 18: 239-242.
- Mehran R, Nikolky E. Contrast induced nephropathy: definition, epidemiology, and patients and risk. *Kidney Int Suppl* 2006; 100: S11-5.
- Toprak O, Cirit M, Yesil M, Bayata S, Tanrisev M, Varol U, Ersoy R, Esi E. Impact of diabetic and prediabetic state on development of contrast induced nephropathy in patients with chronic kidney disease. *Nephrol Dial Transplant* 2007; 22: 819-26.
- Asif A, Preston RA, Roth D. Radiocontrast induced nephropathy. *Am J Ther* 2003; 10: 137-147.
- Parfrey PS, Griffiths SM, Barret BJ, Paul MD, Genge M, Withers J, Farid N, McManamon PJ. Contrast material induced renal failure in patients with diabetes mellitus, renal insufficiency, or both. A prospective controlled study. *N Engl J Med* 1989; 320: 143-9.
- Toprak O, Cirit M, Esi E, Postaci N, Yesil M, Bayata S. Hiperuricemia as a risk factor for contrast induced nephropathy in patients with chronic kidney disease. *Catheter Cardiovasc Interv* 2006; 67: 227-235.
- Erley CM. Does hydration prevent radiocontrast induced renal failure? *Nephrol Dial Transplant* 1999; 14: 1064-6.
- Recio-Mayoral A, Chaparro M, Prado B, Cozar R, Méndez I, Banarjee D, Kaski Jc, Cubero J, Cruz JM. The reno-protective effect of hydration with sodium bicarbonate plus N-acetylcysteine in patients undergoing emergency percutaneous coronary intervention: the RENNO Study. *J Am Coll Cardiol* 2007; 49: 1283-8.
- Chong E, Zed PJ. N-acetylcysteine for radiocontrast induced nephropathy: Potential role in the emergency department? *CJEM* 2004; 6: 253-8.

J. J. Castellanos Monedero<sup>1</sup>, A. Carreño Parrilla<sup>2</sup>, M. Arambarri Segura<sup>2</sup> and G. Caparrós Tortosa<sup>2</sup>  
<sup>1</sup>Servicio de Medicina Interna. Hospital La Mancha Centro. Alcázar de San Juan. <sup>2</sup>Servicio de Nefrología. Hospital General de Ciudad Real.  
**Correspondence:** Jesus Javier Castellanos Monedero. castellanosvela@hotmail.com. Hospital General de Ciudad Real.

### Asepsis and automated peritoneal dialysis

*Nefrología* 2008; 28 (3) 358

**To the editor:** Asepsis is essential in automated peritoneal dialysis to prevent infectious complications.

Patients undergoing automated peritoneal dialysis (APD) usually have a lower risk of peritonitis as compared to

those subject to CAPD.<sup>1,4</sup> However, drainage fluid is stored in an open container at room temperature. This container is washed daily with diluted sodium hypochlorite (bleach).

#### OBJECTIVES

To determine the contamination status of the drainage fluid collected in the container.

To assess whether this fluid storage method involves an infection risk for patients.

To ascertain whether the usual method for disinfecting containers is effective.

#### MATERIALS AND METHODS

Samples were taken from patients on APD at our unit for Gram staining and microbiological cultures in standard and blood culture media. A manually drained sample was collected in all cases to be used as control.

In addition, serial samples were taken from a patient subgroup to see the type of flora and whether this was sensitive to routine disinfection.

The drainage container was disinfected with diluted bleach.

#### RESULTS

Nine cases of patients on APD, whose containers were cleaned daily, were studied.

The fluid in the container was contaminated by a germ in 5 cases (55.5%), by 2 germs in 2 cases (22.2%), and by more than 2 germs in another 2 cases (22.2%).

Ten different germs were identified out of the total 15 germs found. Of these, 60% were Gram-negative and 40% Gram-positive organisms.

The container fluid had Gram-negative germs in 5 cases, Gram-positive germs in 3 cases, and both types of germs in one case.

Most common germs included *Serratia marcescens*, *Pseudomonas putida*, *Streptococcus agalactiae*, *Enterobacter cloacae*, and *Staphylococcus epidermidis*, all of them identified twice, while all other organisms only occurred once.

Enterobacteriaceae accounted for more than 40% of germs, while the remaining

organisms were mainly environmental germs proliferating at room temperature.

Serial samples were taken in 4 cases. When samples were taken after 24 hours, recurrence of some germ was seen in 50% of cases.

The control culture was negative in all cases.

#### CONCLUSIONS

All fluids in the containers were contaminated.

Forty percent of contaminants were enterobacteriaceae.

It is questionable that bleach removes contaminating germs.

Neither the container nor contaminated drainage fluid caused infection in patients.

The container is a safe but not completely aseptic model.

- Oo TN, Roberts TL, Collins AJ. A comparison of peritonitis rates from the United States Renal Data System Database: CAPD versus continuous cycling peritoneal dialysis patients. *Am J Kidney Dis* 2005; 45 (2): 372-80.
- Huang JW, Hung KY, Yen CJ, Yen CJ, Wu KD, Tsai TJ. Comparison of infectious complications in peritoneal dialysis patients using either a twin-bag system or automated peritoneal dialysis. *Nephrol Dial Transplant* 2001; 16 (3): 604-7.
- Rodríguez-Carmona A, Pérez Fontán M, García Falcón T, Fernández Rivera C, Valdés F. A comparative analysis on the incidence of peritonitis and exit-site infection in CAPD and automated peritoneal dialysis. *Perit Dial Int* 1999; 19 (3): 253-8.
- Korbet SM, Vonesh EF, Firaneck CA. Peritonitis in an urban peritoneal dialysis program: An analysis of infecting pathogens. *Am J Kidney Dis* 1995; 26 (1): 47-53.

A. Sastre López, M.<sup>a</sup> R. Bernabéu Lafuente and J. M. Gascó Company  
Servicio de Nefrología. Hospital Son Llàtzer. Palma de Mallorca

**Correspondence:** Aránzazu Sastre López. aranchasastre@hotmail.com. Hospital Huca. Avda. Fernández Ladreda, 30. 24005 León.

### Beçet's disease in a patient on haemodialysis

*Nefrología* 2008; 28 (3) 358-359

**To the editor:** Behçet's disease is a rare inflammatory disorder of an

unknown origin defined by the presence of relapsing oral ulcers and at least two of the following: genital ulcers, eye or skin lesions, and a positive pathergy test.<sup>1</sup> Vascular involvement as venous or arterial thrombosis and aneurysms (vascular Behçet's disease) may be predominant and cause morbidity and mortality.<sup>2</sup> Renal involvement has been reported in one third of cases. In a series of 159 patients, it was secondary to amyloidosis in 69, to glomerulonephritis in 51, from a vascular cause in 35, and to interstitial nephritis in 4 patients.<sup>3</sup>

Glucocorticoids are the drugs most commonly used in patients with moderate to severe involvement,<sup>4,5</sup> but there is evidence of the value of cyclosporin,<sup>6,7</sup> azathioprine,<sup>8</sup> cyclophosphamide<sup>5</sup> and, in recent years, infliximab.<sup>9</sup>

We report the case of a 47-year old male patient who first attended the nephrology outpatient clinic in 2000. He had been diagnosed Behçet's disease based on clinical criteria, including the presence of oral and genital ulcers and recurrent uveitis. He had experienced an episode of deep vein thrombosis. The patient was a HCV carrier with no viral replication data and normal liver function tests. He had chronic renal failure with plasma

creatinine levels of 2.3 mg/dL and a creatinine clearance of 37 mL/min, normal urinary sediment and negative proteinuria. This was related to a nephritis-uveitis syndrome associated to Behçet's disease. Patient was treated with steroids first and then with cyclosporin, adjusting dose to maintain trough levels of 50-100 ng/mL. Kidney function gradually impaired, and in May 2007 haemodialysis had to be started. Because of the absence of signs secondary to Behçet's disease in the last years, cyclosporin was discontinued. In the following months, the patient experienced skin lesions consistent with seborrhoeic eczema in the scalp and face, and a decreased visual acuity probably related to a new episode of uveitis. An angio-CT scan of the lower limbs requested before inclusion in the waiting list for kidney transplant showed in the distal part of the superficial femoral artery an aneurysmal dilation up to the popliteal artery (fig. 1).

After haemodialysis start and discontinuation of immunosuppressive therapy, the patient developed eye, skin, and vascular manifestations that required surgery and led us to reconsider resumption of immunosuppressive treatment. Cyclosporin was used as immunosuppressant because neph-

rotoxicity was not a concern at this time and avoidance of steroids, that could promote HCV replication, was desirable. Behçet's disease is therefore a multisystemic condition requiring a multidisciplinary team for its management. Though treatment duration is not clearly defined because of the possibility of recurrence involving a high morbidity, an indefinite therapy consisting of an induction period with more aggressive drugs and a maintenance period switching to drugs with less side effects should be considered.

Pre-transplant evaluation is another aspect to be defined because vascular signs, as occurred in the case reported, may be a casual finding and affect virtually any vascular territory. A vascular systemic evaluation should be made even in asymptomatic patients.

1. International Study group for bechet's disease. Criteria for diagnosis of Bechet's disease. *Lancet* 1990; 335: 1078.
2. Alpagut U, Ugurlucan M, Davioglu E. Major arterial involment and review of Bechet's disease. *Ann Vasc Surg* 2007; 21 (2): 232-9.
3. Akpolat T, Akkoyunlu M, Akpolatl, Dilek M, Odabas AR, OzenS. Renal Bechet's disease: a cumulative analysis. *Semin Arthritis Rheum* 2002; 31 (5): 317-37.
4. Pipitone N, Olivieri I, Cantini F y cols. New approaches in the treatment of Adamantia-des-bechet's disease. *Curr Opin Rheumatol* 2006; 18: 3.
5. Barnes CG. Treatment of Bechet's syndrome. *Rheumatology (Oxford)* 2006; 45: 245.
6. Atmaca LS, Batioglu F. The efficacy of cyclosporin A in the treatment of Bechet's disease. *Ophthalmic Surg* 1994; 25: 321.
7. Sajjadi H, Soheilian M, Ahmadieh H y cols. Low dose of cyclosporin A therapy in Bechet's disease. *J Ocul Pharmacol* 1994; 10: 553.
8. YaziciH, Pazarli H, Barnes CG y cols. A controlled trial of azathioprine in bechet's syndrome. *N Engl J Med* 1990; 322: 281.
9. Sfikakis PP, Kaklamanis PH, Elezoglou A y cols. Infliximab for recurrent sight-threatening ocular inflammation in Adamantia-des-Bebet disease. *Ann Intern Med* 2004; 140: 404.

A. S. Laurés, L. Quiñones, A. Pobes and R. Forascepi  
 Sección de Nefrología. Hospital de Cabueñes. Gijón. Asturias.  
**Correspondence:** Ana María Suárez Lares. [anamaria.suarez@sessa.princast.es](mailto:anamaria.suarez@sessa.princast.es). Hospital Cabueñes, Cabueñes, s/n. 33394. Gijón. Asturias.

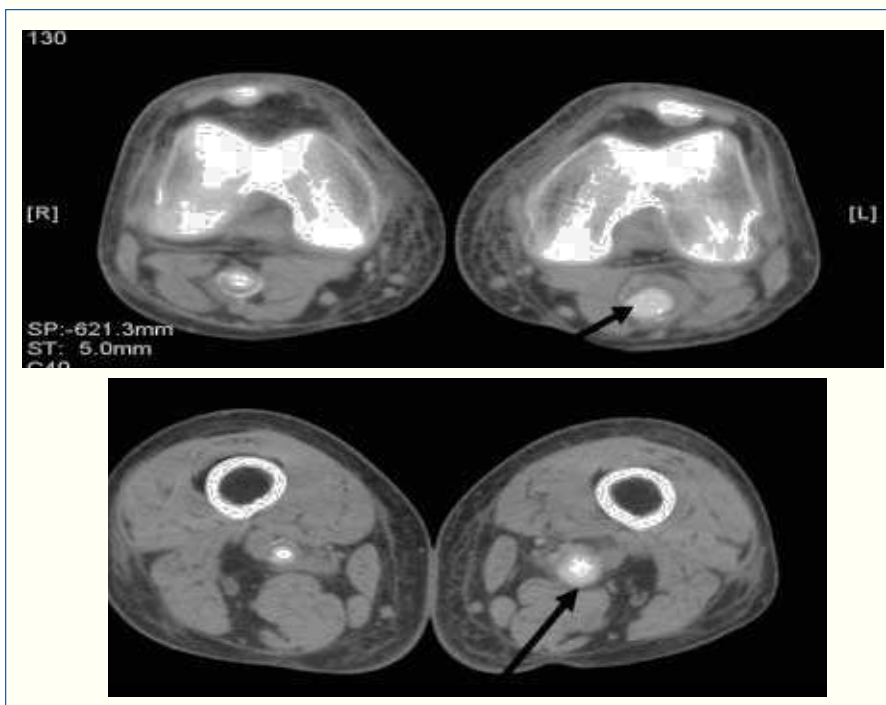


Figure 1.