

agnosticar SCA, aunque se ha descrito que al disminuir el percentil 99 de TnIc (valor de corte) se identificaría a más pacientes con SCA¹ en riesgo de infarto de miocardio (IM) recurrente o muerte, pero incrementaría el diagnóstico de IM en un 47 %².

Por otra parte, es importante saber que cualquier daño cardíaco puede causar liberación de troponina de los miocitos como complejos o como troponina libre a la circulación y existen múltiples causas de elevación de troponinas no relacionadas con el SCA, entre las que están: 1) causas cardíacas (insuficiencia cardíaca congestiva, taquicardia, hipertrofia ventricular izquierda, contusión cardíaca, miocarditis, pericarditis, amiloidosis cardíaca, cirugía cardíaca, cardioversión, intervención coronaria percutánea, vasoespasma coronario, ablación por radiofrecuencia, otras), 2) causas no cardíacas (insuficiencia renal crónica, sepsis, accidente cerebrovascular, tromboembolia pulmonar, hipertensión pulmonar primaria, pacientes en estado crítico, quimioterapia, agentes simpaticomiméticos, ejercicio de resistencia intenso, otros) y 3) causas metodológicas (fibrina, hemólisis, anticuerpos heterófilos, factor reumatoide, otros)^{3,4}.

En los pacientes con IRC, los mecanismos que pueden explicar las elevaciones inespecíficas de TnIc son principalmente el mayor daño cardíaco y la función renal disminuida⁵. En nuestro estudio, las principales causas de elevación de TnIc en el grupo Otras Patologías Cardíacas (OPC) fueron la insuficiencia cardíaca congestiva, fibrilación auricular y taquicardia, mientras que en el grupo Otras Patologías No Cardíacas (OPNC) fueron hipertensión arterial, accidente cerebrovascular y neumonía, pero consideramos que todas las causas descritas deben tenerse en consideración cuando se encuentran concentraciones elevadas de TnIc en pacientes con IRC y ausencia de SCA.

Conflictos de interés

Los autores declaran que no tienen conflictos de interés potenciales relacionados con los contenidos de este artículo.

1. Thygesen K, Alpert JS, White HD, Joint ESC/ACCF/AHA/WHF task force for the redefinition of myocardial infarction. Universal definition of myocardial infarction. *J Am Coll Cardiol* 2007;50:2173-95.
2. Mills NL, Lee KK, McAllister DA, Churchhouse A, MacLeod M, Stoddart M, et al. Implications of lowering

threshold of plasma troponin concentration in diagnosis of myocardial infarction: cohort study. *BMJ* 2012;344:e1533.

3. Agewell S, Giannitsis E, Jernberg T, Katus H. Troponin elevation in coronary vs non-coronary disease. *Eur Heart J* 2011;32:404-11
4. Jaffe AS, Ordonez-Llanos J. Troponinas ultrasensibles en el dolor torácico y los síndromes coronarios agudos. ¿Un paso hacia adelante? *Rev Esp Cardiol* 2010;63:763-9.
5. deFilippi C, Seliger SL, Kelley W, Duh SH, Hise M, Christenson RH, et al. Interpreting cardiac troponin results from high-sensitivity assays in chronic renal disease without acute coronary syndrome. *Clin Chem* 2012;58:1342-51.

Larry M. Flores-Solís¹, Juan L. Hernández-Domínguez¹, Alfonso Otero-González², José R. González-Juanatey³

¹ Laboratorio de Análisis Clínicos. Complejo Hospitalario de Ourense.

² Servicio de Nefrología. Complejo Hospitalario de Ourense.

³ Servicio de Cardiología. Complejo Hospitalario Universitario de Santiago de Compostela.

Correspondencia: Larry M. Flores-Solís
Laboratorio de Análisis Clínicos.
Complejo Hospitalario de Ourense.
lmlab7@yahoo.es

B) COMUNICACIONES BREVES DE INVESTIGACIÓN O EXPERIENCIAS CLÍNICAS

Immunoglobulin A nephropathy could be a clue for the recurrence of gastric adenocarcinoma

Nefrología 2013;33(6):853-5
doi:10.3265/Nefrología.pre2013.Sep.12266

Dear Editor,

The association of nephrotic syndrome that was presented with IgA nephropathy (IgA-N) and malignancy has been previously reported.

IgA -N was first described by Berger and Hinglais in 1968. It is now generally known to be the most common

cause of primary glomerulonephritis worldwide and is characterized by mesangial proliferation and deposition of IgA.¹ Malignancies that have been reported to be associated with IgA-N include Hodgkin's disease,² and non-Hodgkin lymphoma³ renal cell carcinoma,⁴ cancers of the lung,⁵ larynx and esophagus.⁶

We report a case of IgA-N presented with the recurrence of gastric adenocarcinoma in a 58 year-old patient.

CASE REPORT

A 58 year-old man admitted to our hospital in September 2010 with distension of the abdomen and involuntary loss of his %10 weight in the last three months. There were no abnormalities in urine examination on the first evaluation. Upper gastrointestinal endoscopy showed gastric mass and endoscopic biopsy revealed gastric adenocarcinoma. Since diagnosed with stage 3B gastric adenocarcinoma, the chemoradiotherapy (4 cycles of 5-fluorouracil and folinic acid with 50 Gy radiotherapy) was administered after the surgery. Complete remission was achieved and he has been considered for follow-up with three months interval without chemotherapy. He was admitted to our hospital with dyspnea and edema in January 2012. Hypoalbuminemia and 4 gram proteinuria was revealed in laboratory examination. PET-CT scan was showed pleural effusion, bone metastasis and recurrence in mediastinal and abdominal lymph nodes. Then he was considered recurrence of the disease and reevaluated as stage 4 gastric adenocarcinoma. According to his performance status, chemotherapy was not considered and he was referred to our nephrology department for nephrotic syndrome. His blood pressure, temperature and pulse rate were normal. Physical examination revealed decreased breath sound over the right and left lower lung areas and severe edema in both lower extremities. Routine laboratory tests showed the following: serum levels of sodium 137mmol/L, potassium: 5.8mmol/L, calcium: 7.6mg/dL and phosphate: 2.9mg/dL. Blood urea nitrogen (BUN) 22mg/dL, serum creatinine 1.5mg/dL, serum albumin 1.4g/dL and hemoglobin 11.8g/dL. Liver function parameters were within their normal limits. Urinalysis showed urine red blood cells (RBC) counts were >100/high power field, and urinary protein excretion was 3.5g/day. Antinuclear

antibody, anti-DNA, anti-streptolysin O, anti-neutrophil cytoplasmic antibody, anti-glomerular basement membrane antibody, anti-HBs, and anti-HCV were all negative. Complement factors C3 and C4 were within normal ranges. Serum and urine protein electrophoresis were negative for monoclonal gammopathy. The peripheral blood smear was normal with no schistocytes.

Renal biopsy was performed and in total 14 glomeruli were obtained and evaluated. Light microscopy showed that one of the glomeruli had global sclerosis and other glomeruli had mesangial proliferation. Immunohistochemically, focal segmental mesangial IgA deposition was seen in three glomeruli (Figure 1). Steroid therapy with 1mg/kg/day metilprednisolone and losartan 50mg/daily were started and steroid dose was reduced gradually. After six months later, edema was

completely regressed and serum albumin level was 3.0dL. Additionally, urinalysis showed only 1-2 RBC and proteinuria was 0.2g/day (Table 1).

DISCUSSION

Malignancy associated nephrotic syndrome has been described in the literature by Lee et al. reported that nephrotic syndrome occurring simultaneously with malignancy was 10 times higher than in the general population.⁷

Paraneoplastic syndrome may be suspected in the presence of the following criteria: (a) no evident etiology for the associated syndrome; (b) the diagnosis of the syndrome and cancer simultaneously; (c) clinical (and histological) remission after full remission achieved by chemotherapy or complete surgical removal of the tumor; (d) increases of associated symptoms with tumor recurrence.¹

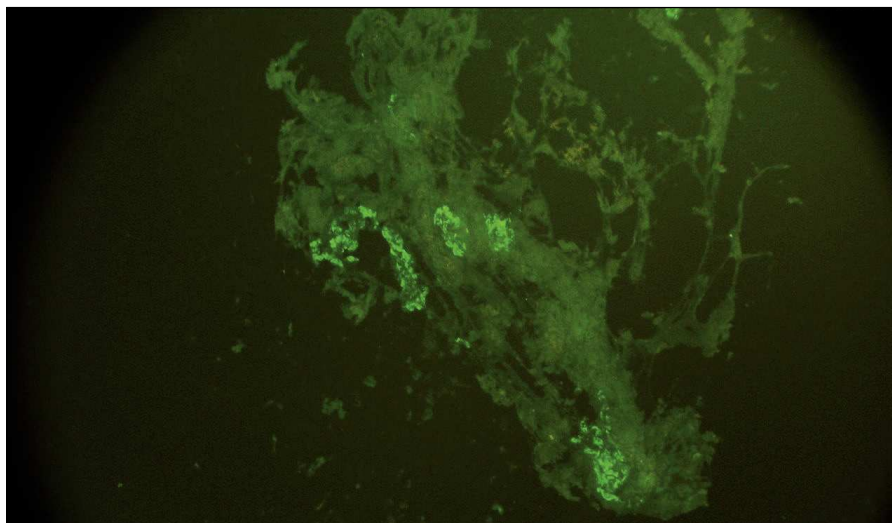


Figure 1. Focal segmental mesangial IgA depositiona in three glomeruli.

Table 1. Change in serum albumin, creatinine and proteinuria levels after treatment at different times

	1 st month	2 nd month	3 rd month	6 th month
Serum albumin (g/dl)	1.8	2.5	2.9	3.0
Proteinuria (g/day)	2.7	1.5	0.8	0.2
Creatinine (mg/dl)	1.3	1.1	1.1	1.0

Different types of glomerulopathies, generally membranous glomerulonephritis have been associated with solid tumors.⁸ However paraneoplastic IgA-N has been reported rarely.

Primarily, IgA-N associations with cancer of the buccal cavity, the nasopharynx and the respiratory tract have been described. Mesangial IgA deposits have been found at autopsy in patients who died of a gastro-intestinal neoplasia without prior clinical evidence of nephropathy.⁹ Despite intensive investigation, the mechanism underlying glomerular IgA deposition in IgA nephropathy has not been clarified.¹⁰ There are two isotype subclasses of IgA: IgA1 and IgA2. Gastrointestinal and respiratory tracts plasma cells produce both IgA1 and IgA2; however plasma cells in the spleen, lymph nodes and bone marrow produce predominantly IgA1. Invasion of the intestinal mucosa by malignancy increases the circulating IgA level and therefore leads to the formation of mesangial deposits.¹⁰

In conclusion, paraneoplastic IgA nephropathy with nephrotic syndrome could be a clinical problem in patients with malignancies, besides the treatment chart has not been well-documented yet. To the best of our knowledge, we report the first case of paraneoplastic IgA-N associated with recurrence of gastric adenocarcinoma. IgA-N should take into account in patients with malignancy and nephrotic syndrome even if primary disease was on remission and it could be a harbinger for the relapse of disease.

Conflicts of interest

The authors declare that they have no conflicts of interest related to the contents of this article.

1. Donadio JV, Grande JP. IgA nephropathy. *N Engl J Med* 2002;5:738-48.
2. Bergmann J, Buchheidt D, Waldherr R, Maywald O, van der Woude FJ, Hehlmann R, et al. IgA nephropathy and hodgkin's disease: a rare coincidence. Case report and literature review. *Am J Kidney Dis* 2005;45:e16-9.

3. Zahner J, Bach D, Malms J, Schneider W, Diercks K, Grabensee B. Glomerulonephritis and malignant lymphoma. Mostly men with low-grade lymphoma with various forms of glomerulonephritis. *Med Klin (Munich)* 1997;92:712-9.
4. Magyarlaki T, Kiss B, Buzogany I, Fazekas A, Sukosd F, Nagy J. Renal cell carcinoma and paraneoplastic IgA nephropathy. *Nephron* 1999;82:127-30.
5. Schutte W, Ohlmann K, Koall W, Rosch B, Osten B. Paraneoplastic IgA nephritis as the initial symptom of bronchial carcinoma. *Pneumologie* 1996;50:494-5.
6. Lam KY, Law SY, Chan KW, Yuen MC. Glomerulonephritis associated with basaloid squamous cell carcinoma of the oesophagus. A possible unusual paraneoplastic syndrome. *Scand J Urol Nephrol* 1998;32:61-3.
7. Lee JC, Yamauchi H, Hopper J Jr. The association of cancer and the nephrotic syndrome. *Ann Intern Med* 1966;64:41-51.
8. Helin H, Pasternack A, Hakala T, Penttinen K, Wager O. Glomerular electron-dense deposits and circulating immune complexes in patients with malignant tumours. *Clin Nephrol* 1980;14:23-30.
9. Beaufils H, Jouanneau C, Chomette G. Kidney and cancer: results of immunofluorescence microscopy. *Nephron* 1985;40(3):303-8.
10. Bacchetta J, Juillard L, Cochat P, Droz JP. Paraneoplastic glomerular diseases and malignancies. *Crit Rev Oncol Hematol* 2009;70(1):39-58.

Ismail Kocyyigit¹, Sumeyra Dortdudak², Eray Eroglu², Aydin Unal¹, Murat H. Sipahioglu¹, Veli Berk³, Bulent Tokgoz¹, Oktay Oymak¹, Ismail Kocyyigit¹

¹ Department of Nephrology. Erciyes University Medical School. Kayseri (Turkey).

² Department of Internal Medicine. Erciyes University Medical School. Kayseri (Turkey).

³ Department of Oncology. Erciyes University Medical School. Kayseri (Turkey).

Correspondence: Ismail Kocyyigit

Department of Nephrology, Erciyes University Medical School, Erciyes Üniversitesi Tıp Fakültesi, Organ Nakli ve Diyaliz Hastanesi Talas Yolu Üzeri, Kayseri, Türkiye, 38039, Kayseri, Turkey. iikocyyigit@gmail.com

The E23K polymorphism of the *KCNJ11* gene is associated with lower insulin release in patients with Autosomal Dominant Polycystic Kidney Disease

Nefrologia 2013;33(6):855-8

doi:10.3265/Nefrologia.pre2013.May.12111

Dear Editor,

Results of large-scale studies and meta-analyses¹⁻⁴ strongly indicate that K23 allele is associated with higher prevalence and incidence of type 2 diabetes in adult Caucasians. Some studies^{1,5} have shown that the K allele may have a diabetogenic effect by impairing glucose-induced insulin release.

The aim of our study was to investigate an association between E23K *KCNJ11* gene polymorphism with anthropometric, biochemical, beta-cell secretion and insulin sensitivity parameters among adult ADPKD patients with normal kidney function and no diagnosis of diabetes. The comparison of genotype-phenotype associations between ADPKD and non-ADPKD subjects could reveal a hypothetical mechanism of genetic determination of diabetes specific for ADPKD patients.

METHODS

The study group included 49 adult individuals with diagnosed ADPKD (19 males, 30 females) while the control group comprised 50 gender- and age-matched healthy individuals (22 males, 28 females).

The oral glucose tolerance test (OGTT) was performed according to WHO guidelines (with 75 g of glucose).⁶ Venous blood was collected to measure fasting glucose, insulin, total cholesterol, LDL, HDL and triglyceride levels. Glucose concentration was measured by an enzymatic-amperometric method (Super GL; Dr Müller Gerätebau GmbH, Freital, Germany). Insulin concentration