

Arterial calcification: cardiovascular function and clinical outcome

G.M. London

INSERM U970, Paris and Hopital F.H. Manhès. Fleury-Mérogis (France)

Nefrologia 2011;31(6):644-7

doi:10.3265/Nefrologia.pre2011.Oct.11175

ABSTRACT

Arterial calcification (AC) is a common complication of CKD and ESRD, and the extents of AC are predictive of subsequent cardiovascular mortality beyond established conventional risk factors. AC develop in two distinct sites: the intima and media layers of the large and medium-sized arterial wall. These two forms are frequently associated. AC is tightly associated with aging and arterial remodeling, including intima-media thickening, but also changes of the geometry and function of aortic valves. Evidence has accumulated pointing to the active and regulated nature of the calcification process. Elevated phosphate and calcium may stimulate sodium-dependent phosphate cotransport involving osteoblast-like changes in cellular gene expression. AC is responsible for stiffening of the arteries with increased left ventricular afterload and abnormal coronary perfusion as the principal clinical consequences.

Keywords: Arterial calcifications. Arterial stiffness. End-stage renal disease.

INTRODUCTION

The cardiovascular complications are leading cause of mortality and morbidity in chronic and end-stage renal diseases, in great part related to arterial diseases, i.e. atherosclerosis and arteriosclerosis^{1,2}. While atherosclerosis and plaque-associated occlusive lesions are the frequent causes of these complications, arteriosclerosis is characterized by outward remodeling and stiffening of large arteries³. These arterial structural and functional changes are,

Correspondence: Gérard London
INSERM U970, Paris and Hopital F.H. Manhès.
Fleury-Mérogis. France.
glondon@club-internet.fr

Calcificación arterial: la función cardiovascular y el resultado clínico

RESUMEN

La calcificación arterial (CA) es una complicación común en la enfermedad renal crónica y la enfermedad renal en etapa terminal, y cuyo alcance es diagnóstico de una posterior mortalidad cardiovascular más allá de los factores de riesgo convencionales establecidos. La CA se desarrolla en dos ubicaciones diferentes: en las capas íntima y media de las paredes arteriales de gran y medio tamaño. Estas dos formas se encuentran frecuentemente asociadas. La CA está estrechamente relacionada con el envejecimiento y el remodelado arterial, que incluye el engrosamiento de la íntima-media y los cambios en la geometría y la función de las válvulas aórticas. Se han recogido evidencias que señalan la naturaleza activa y regulada del proceso de calcificación. Elevados niveles de fosfatos y calcio pueden estimular el cotransporte de fosfato dependiente del sodio que implique cambios osteoblásticos en la expresión genética celular. La CA es responsable del endurecimiento de las arterias, con un aumento de la poscarga ventricular izquierda y perfusión coronaria anormal como principales causas clínicas.

Palabras clave: Calcificación arterial. Rigidez arterial. Etapa final de enfermedad renal.

in many aspects, similar to an accelerated age-related process³. One characteristic feature of arterial alterations observed in renal patients is the presence of extensive vascular calcifications⁴⁻⁶ whose extents are predictive of subsequent cardiovascular mortality beyond established conventional risk factors⁷⁻⁹. AC develop in two distinct sites: the intima and media layers of the large and medium-sized arterial wall¹⁰. *These two forms are frequently associated.* Intima calcification occurs within atherosclerotic plaque and is a progressive feature of common atherosclerosis, while media calcifications can occur independently from atherosclerotic plaques and is frequently observed in medium sized arteries in CKD/ESRD, diabetes. AC is tightly

associated with aging and arterial remodeling, including intima-media thickening, but also changes of the geometry and function of aortic valves, e.g., decreased aortic valve surface area and smaller valve opening¹¹.

MECHANISMS OF ARTERIAL CALCIFICATION

The presence of dystrophic calcification in the arterial walls is a response to tissue injury, represents a repair process, and is a form of scar tissue¹². Experimental and clinical studies have shown that AC is a process reflecting changes of the vascular smooth-muscle cells (VSMC) and pericytes from contractile to secretory phenotype). VSMC synthesize bone-associated proteins, including alkaline phosphatase, osteocalcin, osteopontin and a coat of collagen-rich extracellular matrix, and includes the formation of matrix vesicles, nodules and apoptotic bodies, which serve as initiation sites for apatite crystallization^{13,14}.

In vitro, VSMC differentiation towards osteoblast-like cells, with subsequent mineralization, is regulated by the balance between promoters and inhibitors of calcification, and results from disruption of this balance in favor of promoters. The secretory phenotype is initiated by the activation of Runx2 (Cbfa1) and osterix (Osx), transcription factors that promote the differentiation of mesenchymal cells into the osteoblastic lineage^{15,16}. The Runx2 and Osx are activated upstream by several factors including Msx2, Wnt and β -catenin signaling¹⁷. The stimuli initiating this “osteogenic cascade” include bone morphogenic proteins (BMP 2, 4) and chronic injurious stimuli and metabolic toxicities including generation of reactive oxygen species (ROS)¹⁷⁻¹⁹. The result could be either VSMC apoptosis or stimulation of NF κ -B and activation of inflammatory mediators TNF α , IL-1, IL-6, and activation of macrophages¹⁹⁻²³. Experimental studies using molecular imaging clearly showed that calcifications develops in parallel with inflammation in two phases: early activation of macrophages and inflammation and calcification at later stage²² (figure 1).

Pooled uremic serum with high phosphate concentration, induced expression of Runx2²⁴ and blocks the expression of genes responsible for expression of contractile molecules^{13,14}. *In vitro*, the phosphate-stimulated calcification process can be inhibited by adding pyrophosphates that antagonize the cellular sodium-phosphate cotransport system (PIT-1)²⁵. Recent study has shown tha phosphate induces the calcification process through a common pathway: increasing mitochondrial ROS and activation of NF κ -B pathway and transcription of osteogenic program with expression of Msx2-Wnt-Runx2²⁶.

In the presence of normal serum, VSMC do not calcified and can inhibit spontaneous calcium and phosphate precipitation in solution, indicating that systemic calcification inhibitors

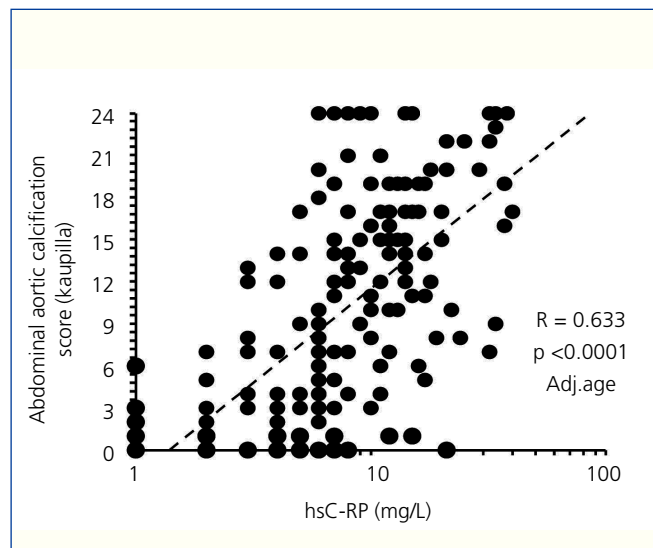


Figure 1. Correlations between the abdominal aortic calcification score and high-sensitive C-RP.

such as fetuin-A are present in the serum²⁷ and also in VSMCs who constitutively express potent local inhibitors of calcification, such as matrix GLA protein^{28,29}, which may limit AC by binding to bone morphogenic proteins (BMP-2)²⁹. Osteopontin and osteoprotegerin are potent inhibitors of AC *in vivo*, and inactivation of their gene enhances the calcification process^{30,31}.

CLINICAL IMPACT OF ARTERIAL CALCIFICATIONS

Intima calcification occurs in the context of common atherosclerosis, progresses in parallel with the plaque evolution. The arterial dysfunction result from narrowing of the arterial lumen with ischemia affecting the tissues and organs downstream. The acute coronary events and infarction are more related to biomechanical stability of atherosclerotic plaques and the rupture of the plaque’s fibrous cap. This results from mechanical discontinuity between the inclusion of rigid material (calcium crystals) into distensible material (lipid core) resulting in plaque vulnerability and rupture. Although a higher coronary AC score is associated with a poorer cardiovascular prognosis, the influence of calcification on plaque stability is controversial. The results of several studies indicated that AC does not increase plaque vulnerability, which seems more attributable to a large lipid pool, thin fibrous cap and intensity of local inflammation^{32,33}.

Media calcification (Mönckeberg’s sclerosis or media calcinosis) is characterized by diffuse mineral deposits within the arterial tunica media. While media calcification is frequently observed with aging in the general population, it is significantly more pronounced in patients with metabolic

disorders, such as metabolic syndrome, diabetes or CKD. Media calcification is concentric, not extending into arterial lumen in its typical pure form and is associated with abnormal cushioning function of blood vessels (arteriosclerosis-arterial hardening) by promoting arterial stiffness³⁴. The principal consequences of arterial stiffening are an abnormal arterial pressure wave (characterized by increased systolic and decreased diastolic pressures, resulting in high pulse pressure) and increased aortic characteristic impedance, a measure of the opposition of the aorta to oscillatory input (i.e., stroke volume)³⁵. Because the two forms of AC are frequently associated the conduit and cushioning abnormalities could be associated.

MANAGEMENT AND PREVENTION

AC rarely regress, therefore, the primary goals are prevention and stabilization of existing calcifications. Because intimal AC are related to atherosclerosis, the general approach is non-specific as advocated for patients with atherosclerosis: control of blood lipids (but no evidence of a benefit with statins), use of aspirin, treatment of obesity and hypertension, physical activity, smoking cessation, and control of diabetes. More specific preventive measures for patients with CKD or ESRD include controlling serum calcium and phosphate levels, thereby avoiding oversuppression of parathyroid activity and ABD³⁶. Disturbances in calcium and phosphate metabolism are associated with uremic bone disease, and the results of several studies indicated that calcium overload is associated with AC development and progression, suggesting that the overuse of high doses of calcium-based phosphate binders, pharmacological doses of vitamin D, and high calcium concentration in the dialysate should be avoided³⁶⁻³⁹. Those data suggest that the use of calcium-containing phosphate binders, high intradialytic calcium load, and overuse of active vitamin D should be avoided in elderly patients and in those who already have AC.

Conflicts of interest

The authors declare they have no potential conflicts of interest.

REFERENCES

1. Lindner A, Chara M, Sherrard D, Scribner BM. Accelerated atherosclerosis in prolonged maintenance hemodialysis. *N Engl J Med* 1974;290:697-702.
2. London GM, Drüeke TB. Atherosclerosis and arteriosclerosis in chronic renal failure. *Kidney Int* 1997;51:1678-95.
3. Pannier B, Guérin AP, Marchais SJ. Arterial structure and function in end-stage renal disease. *Artery Research* 2007;1:79-88.
4. Braun J, Oldendorf M, Moshage W. Electron beam computed tomography in the evaluation of cardiac calcifications in chronic dialysis patients. *Am J Kidney Dis* 1996;27:394-401.
5. Goodman WG, Goldin J, Kuizon BD. Coronary artery calcification in young adults with end-stage renal disease who are undergoing dialysis. *N Engl J Med* 2000;342:1478-83.
6. Guérin AP, London GM, Marchais SJ, Métivier F. Arterial stiffening and vascular calcifications in end-stage renal disease. *Nephrol Dial Transplant* 2000;15:1014-21.
7. Wilson PWF, Kauppila LI, O'Donnell CJ. Abdominal aortic calcific deposits are an important predictor of vascular morbidity and mortality. *Circulation* 2001;103:1529-34.
8. Keelan PC, Bielak LF, Ashai K. Long-term prognostic value of coronary calcification detected by electron-beam computed tomography in patients undergoing coronary angiography. *Circulation* 2001;104:412-7.
9. London GM, Guérin AP, Marchais SJ. Arterial media calcification in end-stage renal disease: impact on all-cause and cardiovascular mortality. *Nephrol Dial Transplant* 2003;18:1731-40.
10. Amann K. Media calcification and intima calcification are distinct entities in chronic kidney disease. *Clin J Am Soc Nephrol* 2008;3:1599-605.
11. Wang AY, Wang M, Woo J. Cardiac valve calcification as an important predictor for all-cause mortality and cardiovascular mortality in long-term peritoneal dialysis patients: a prospective study. *J Am Soc Nephrol* 2003;14:159-68.
12. Hayden MR, Tyagi SC, Kolb L. Vascular ossification-calcification in metabolic syndrome, type 2 diabetes mellitus, chronic kidney disease, and calciphylaxis-calcific uremic arteriopathy: the emerging role of sodium thiosulfate. *Cardiovasc Diabetol* 2005;4:4.
13. Schoppet M, Shroff RC, Hofbauer LC, Shanahan CM. Exploring the biology of vascular calcification in chronic kidney disease: what's circulating? *Kidney Int* 2008;73:384-90.
14. Demer LL, Tintut Y. Vascular calcification: pathobiology of multifaceted disease. *Circulation* 2008;117:2938-48.
15. Reynolds JL, Joannides AJ, Skepper JN. Human Vascular smooth muscle cells undergo vesicle-mediated calcification in response to changes in extracellular calcium and phosphate concentrations: a potential mechanism for accelerated vascular calcification in ESRD. *J Am Soc Nephrol* 2004;15:2857-67.
16. Steitz SA, Speer ME, Curinga G. Smooth muscle cell phenotypic transition associated with calcification. Upregulation of Cbfa1 and downregulation of smooth muscle lineage markers. *Circ Res* 2001;89:1147-54.
17. Shao J-S, Cheng SL, Sadhu J, Towler DA. Inflammation and the osteogenic regulation of vascular calcification. A review and perspective. *Hypertension* 2010;55:579-92.
18. Parhami F, Morrow AD, Balucan J. Lipid oxidation products have opposite effects on calcifying vascular cell and bone cell differentiation: a possible explanation for the paradox of arterial calcification in osteoporosis patients. *Arterioscler Thromb Vasc Biol* 1997;17:680-7.
19. Mody N, Parhami F, Sarafian TA, Demer LL. Oxidative stress modulates osteoblastic differentiation of vascular and bone cells. *Free Radic Biol Med* 2001;31:509-19.
20. Wang TJ, Larson MG, Levy D. C-Reactive protein is associated with

- subclinical epicardial coronary calcification in men and women the Framingham Heart Study. *Circulation* 2002;106:1189-91.
21. Koh JM, Khang YH, Jung CH. Higher circulating hsCRP levels are associated with lower bone mineral density in healthy pre- and postmenopausal women: evidence for a link between systemic inflammation and osteoporosis. *Osteoporos Int* 2005;16:1263-71.
 22. Aikawa E, Nahrendorf M, Figueiredo JL. Osteogenesis associates with inflammation in early-stage atherosclerosis evaluated by molecular imaging in vivo. *Circulation* 2007;116:2841-50.
 23. Tintut Y, Patel J, Territo M. Monocyte macrophage regulation of vascular calcification in vitro. *Circulation* 2002;105:650-5.
 24. Moe SM, Duan D, Doehle BP. Uremia induces the osteoblast differentiation factor Cbfa1 in human blood vessels. *Kidney Int* 2003;63:1003-11.
 25. Lomashvili K, Cobbs S, Hennigar RA. Phosphate-induced vascular calcification: role of pyrophosphate and osteopontin. *J Am Soc Nephrol* 2004;15:1392-401.
 26. Zhao MM, Xu MJ, Cai Y. Mitochondrial reactive oxygen species promote p85 nuclear translocation mediating high phosphate-induced vascular calcification in vitro and in vivo. *Kidney Int* 2011;79:1071-9.
 27. Schafer C, Heiss A, Schwarz A. The serum protein alpha 2-Heremans-Schmid glycoprotein/fetuin-A is a systemically acting inhibitor of ectopic calcification. *J Clin Invest* 2003;112:357-66.
 28. Luo G, Ducy P, McKee MD. Spontaneous calcification of arteries and cartilage in mice lacking matrix GLA protein. *Nature* 1997;386:78-81.
 29. Sweatt A, Sane DC, Hutson SM, Wallin R. Matrix Gla protein (MGP) and bone morphogenetic protein-2 in aortic calcified lesions of aging rats. *J Thromb Haemost* 2003;1:178-85.
 30. Wada T, McKee MD, Steitz S, Giachelli CM. Calcification of vascular smooth muscle cells: inhibition by osteopontin. *Circ Res* 1999;84:166-78.
 31. Price PA, June HH, Buckley JR, Williamson MK. Osteoprotegerin inhibits artery calcification induced by warfarin and by vitamin D. *Arterioscler Thromb Vasc Biol* 2001;21:1610-6.
 32. Lin TC, Tintut Y, Lyman A, Demer LL, Hsiai TK. Mechanical response of a calcified plaque model to fluid shear force. *Ann Biomed Engl* 2006;34:1535-41.
 33. Hoshino T, Chow LA, Hsu JJ. Mechanical stress analysis of rigid inclusion in distensible material: a model of atherosclerotic calcification and plaque vulnerability. *Am J Physiol Heart Circ Physiol* 2009;297:H802-H810.
 34. Guérin AP, London GM, Marchais SJ, Métivier F. Arterial stiffness and vascular calcifications in end-stage renal disease. *Nephrol Dial Transplant* 2000;15:1014-21.
 35. O'Rourke MF. Mechanical principles in arterial disease. *Hypertension* 1995;26:2-9.
 36. Brandenburg VM, Floege J. Adynamic bone disease-bone and beyond. *NDT Plus* 2008;3:135-47.
 37. Chertow GM, Burke SK, Raggi P. Sevelamer attenuates the progression of coronary and aortic calcification in hemodialysis patient. *Kidney Int* 2002;62:245-52.
 38. Suki WN, Zabaneh R, Cangiano JL. Effects of sevelamer and calcium-based phosphate binders on mortality in hemodialysis patients. *Kidney Int* 2007;72:1130-7.
 39. Bolland MJ, Barber PA, Doughty RN. Vascular events in healthy older women receiving calcium supplementation: randomised controlled trial. *BMJ* 2008;336:262-6.