

- autosómica dominante. Revisión 2020. *Nefrología*. 2021;42:367–89, <http://dx.doi.org/10.1016/j.nefro.2021.05.009>.
2. Mikolajczyk AE, Te HS, Chapman AB. Gastrointestinal manifestations of autosomal-dominant polycystic kidney disease. *Clin Gastroenterol Hepatol*. 2017;15:17–24.
 3. Breuning MH, Snijdwint FG, Brunner H, Verwest A, Ijdo JW, Saris JJ, et al. Map of 16 polymorphic loci on the short arm of chromosome 16 close to the polycystic kidney disease gene (PKD1). *J Med Genet*. 1990;27:603–13.
 4. Peters DJM, Spruit L, Saris JJ, Ravine D, Sandkujil LA, Fossdal R, et al. Chromosome 4 localization of a second gene for autosomal dominant polycystic kidney disease. *Nat Genet*. 1993;5:359–62.
 5. Porath B, Gainullin VG, Cornec-Le Gall E, Dillinger EK, Heyer CM, Hopp K, et al. Mutations in GANAB, encoding the glucosidase II α subunit, cause autosomal-dominant polycystic kidney and liver disease. *Am J Hum Genet*. 2016;98:1193–207.
 6. Cornec Le Gall E, Olson RJ, Beese W, Heyer HM, Gainullin VG, Smith JM, et al. Monoallelic mutations to DNAJB11 cause atypical autosomal-dominant polycystic kidney disease. *Am J Hum Genet*. 2018;102:832–44.
 7. Beese W, Chang AR, Luo JZ, Triffo WJ, Moore BS, Gulati A, et al. ALG9 mutation carriers develop kidney and liver cysts. *J Am Soc Nephrol*. 2019;30:2091–102.
 8. Capuano I, Buonanno P, Riccio E, Amicone M, Pisani A. Therapeutic advances in ADPKD: the future awaits. *J Nephrol*. 2022;35:397–415.
 9. Ministerio de Sanidad, Agencia Española de Medicamentos y Productos Sanitarios. Informe de Posicionamiento Terapéutico de tolvaptan (Jinarc[®]) en poliquistosis renal autosómica dominante. IPT, 42/2022. V1. Available from: <https://www.aemps.gob.es/medicamentosUsoHumano/informesPublicos/docs/2022/IPT.42-2022-jinarc.pdf>.
 10. Irazabal MV, Torres VE, Hogan MC, Glockner J, King BF, Ofstie TG, et al. Short-term effects of tolvaptan on renal function and volume in patients with autosomal dominant polycystic kidney disease. *Kidney Int*. 2011;80:295–301.

Iris Viejo Boyano^{a,*}, Paul José Hernández Velasco^b,
Eduardo Gutiérrez Martínez^b

^a Servicio de Nefrología, Hospital Universitari i Politècnic La Fe, Valencia, Spain

^b Servicio de Nefrología, Hospital Universitario 12 de Octubre, Madrid, Spain

*Corresponding author.

E-mail address: ivb_1993@hotmail.com (I. Viejo Boyano).

2013-2514/© 2024 Published by Elsevier España, S.L.U. on behalf of Sociedad Española de Nefrología. This is an open access article under the CC BY-NC-ND license (<http://creativecommons.org/licenses/by-nc-nd/4.0/>). <https://doi.org/10.1016/j.nefro.2024.03.002>

JC polyomavirus nephropathy in renal transplant patient: An uncommon guest

Nefropatía por poliomavirus JC en paciente trasplantado renal, un invitado infrecuente



Dear Editor,

BK virus (BKV) is the main cause of nephropathy associated with polyomavirus (NAPV) in renal transplantation and is an important cause of graft loss. In recent years, polyomavirus nephropathy has been associated with JC virus (JCV),¹ a less common entity with a later clinical presentation, which usually causes a delay in diagnosis. We present a case of nephropathy associated with JC polyomavirus (NAPV-JC) in a renal transplant patient, which is to our knowledge the first described in our country.

DOI of original article:
<https://doi.org/10.1016/j.nefro.2023.02.001>.

Our case is a 43-year-old male with a history of chronic kidney disease secondary to segmental and focal glomerulosclerosis on peritoneal dialysis since 2009, who received a deceased-donor kidney transplant in February 2011. He received basiliximab, steroids, tacrolimus and mycophenolate mofetil, and his maintenance therapy was: prednisone 5 mg/day, mycophenolate mofetil 2 g/day and tacrolimus (levels of 6–8 ng/dl).

During 2021 the patient presented a progressive deterioration of renal function with serum creatinine levels of 1.95 mg/dl as compared with baseline serum creatinine of 1.2–1.3 mg/dl (Table 1). Microbiological study of plasma and urine ruled out cytomegalovirus and KBV infection. Measurement of anti-HLA antibodies and an ultrasound of the abdomen did not show data of interest. Therefore, it was decided to perform a renal biopsy in April 2022.

Table 1 – Evolution of analytical and microbiological results.

	26/08/20	15/10/21	07/04/22	28/04/22	20/05/22	29/07/22	02/08/22	28/08/22	19/09/22	10/10/22	21/11/22
Serum creatinine (mg/dL)	1.33	1.7	1.95	Renal biopsy	1.95	2.14	Onset of nonspecific immunoglobulins	2.12	1.86	1.92	1.96
GFR CKD-EPI (ml/min/1.73 m) ²	65.9	49	41		41	37		37	43	39	41
Proteinuria (g/24 h)	0.08	0.08	0.06		0.18	0.24		0.38	0.42	0.15	0.09
Tacrolimus (ng/mL)	6.9	6.9	7.1		6.8	6		4.6	4.2	2.9	2.9
Everolimus (ng/mL)	-	-	-		-	3.6		6.7	8.3	4.83	4.58
Viruria JC (log)	-	-	-		Positive	Positive (6.6 log)		Positive (7.3 log)	Positive (6.3 log)	Positive (6 log)	Positive (5.6 log)
Viremia JC (log)	-	-	-		-	Positive (3.4 log)		Positive (3.4 log)	Positive (1.8 log)	Positive <20 copies	<20 copies

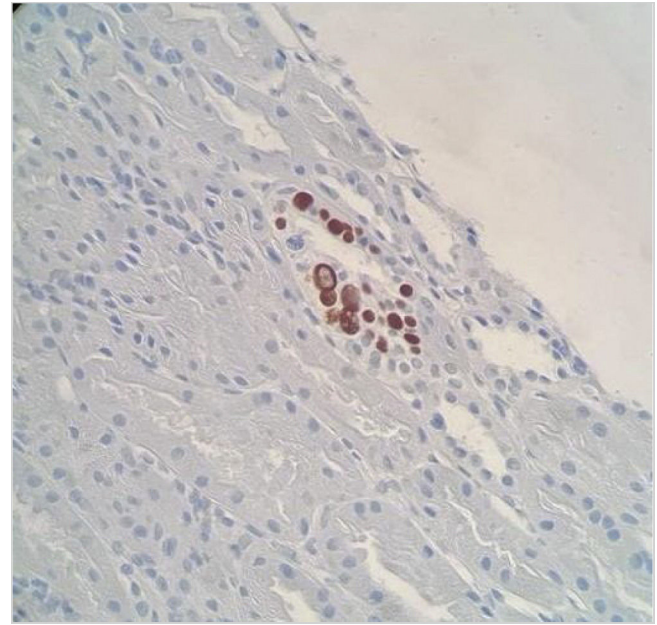


Figure 1 – Positive immunohistochemistry for SV40 antigen in JC virus-infected tubular cells.

Renal biopsy showed a total of 18 glomeruli (seven with global sclerosis) and one medium caliber artery, mild chronic lymphoplasmacytic inflammation and areas of interstitial fibrosis and tubular atrophy. We observed numerous nuclear images compatible with viral inclusions, which were positive for SV-40 immunohistochemical staining (Fig. 1). The study with immunofluorescence and C4d staining was negative. The presumptive diagnosis was nephropathy associated with polyomavirus BK (NAPV-BK), however, the detection of BKV viral load in plasma and urine samples was repeatedly negative; therefore, we considered the involvement of another polyomavirus.

The presence of JCV was investigated by PCR (Primerdesign Poliomavirus JC-Genesis) in the renal biopsy sample previously deparaffinized and in urine and plasma samples, all of which were positive, establishing the diagnosis of NAPV-JC.

Mycophenolate mofetil was discontinued and everolimus was started while maintaining reduced tacrolimus levels. In addition, non-specific intravenous immunoglobulins were added as complementary treatment (30 g every 3 weeks, total 6 doses). The presence of JCV virus in urine and blood decreased progressively, with a more marked decrease of viremia, and stable serum creatinine levels without a significant proteinuria (Table 1).

JCV is an exclusively human pathogen, causing asymptomatic infection in healthy adults. Between 70 and 90% of the population is infected in childhood,¹ producing a latent infection in the renal epithelium,² from where it can be reactivated and excreted in the urine in both immunocompetent and immunocompromised individuals.³

NAPV-JC is a rare complication that occurs in renal transplant patients, with the first case described in 2003.⁴ Its incidence is low, up to 0.9%, unlike NAPV-BK whose incidence is higher (1-10%).⁵ However, it is possible that there is under-

diagnosis, due to its atypical presentation and the high level of clinical suspicion required. Unlike NAPV-BK, which is usually observed within two years of transplantation, NAPV-VJC has a later onset, usually four years after graft implantation.^{4,6-8}

Histological diagnosis of NAPV is based on the presence of tubulointerstitial inflammatory infiltrate and fibrosis of multifocal distribution associated with histological identification of polyomavirus from basophilic nuclear viral inclusions in epithelial cells and/or positivity for immunohistochemical staining for SV40 T antigen, which cross-reacts with BK and JC polyomaviruses. Therefore, the presence of the previous histological findings in the midst of viruria and negative viremia for BKV makes it necessary to rule out the presence of NAPV-JC, and JCV can be detected by PCR in urine, blood or previously deparaffinized renal biopsy samples.

There is no consensus about the treatment of NAPV-JC, with most clinicians using an approach like that for NAPV-BK given the virological similarity, and the main strategy is reduction of immunosuppression. Other therapeutic agents such as intravenous immunoglobulins, leflunomide or conversion to m-TOR inhibitor (i-mTOR) have also been used with variable results.^{6,7}

In summary, NAPV-JC is an infrequent condition that requires a high clinical suspicion for its diagnosis, given its histological similarity to NAPV and negative virological tests for VBK. The main therapeutic measure consists of reducing immunosuppression; however, given the small number of published cases, more studies are needed to learn and establish more standardized management guidelines for this condition.

REFERENCES

- Costa C, Cavallo R. Polyomavirus-associated nephropathy. *World J Transplant.* 2012;2:84–94, <http://dx.doi.org/10.5500/wjt.v2.i6.84>. PMID: 24175200; PMCID: PMC3782238.
- Delbue S, Ferrareso M, Ghio L, Carloni C, Carluccio S, Belingheri M, et al. A review on JC virus infection in kidney transplant recipients. *Clin Dev Immunol.* 2013;9:26391, <http://dx.doi.org/10.1155/2013/926391>. Epub 2013 Jan 29. PMID: 23424601; PMCID: PMC3569895.
- Egli A, Infanti L, Dumoulin A, Buser A, Samaridis J, Stebler C, et al. Prevalence of polyomavirus BK and JC infection and replication in 400 healthy blood donors. *J Infect Dis.* 2009;199:837–46, <http://dx.doi.org/10.1086/597126>. PMID: 19434930.
- Kazory A, Ducloux D, Chalopin JM, Angonin R, Fontanière B, Moret H. The first case of JC virus allograft nephropathy. *Transplantation.* 2003;76:1653–5, <http://dx.doi.org/10.1097/01.TP.0000090749.42791.14>. PMID: 14702550.
- Drachenberg CB, Hirsch HH, Papadimitriou JC, Gosert R, Wali RK, Munivenkatappa R, et al. Polyomavirus BK versus JC replication and nephropathy in renal transplant recipients: a prospective evaluation. *Transplantation.* 2007;84:323–30, <http://dx.doi.org/10.1097/01.tp.0000269706.59977.a5>. PMID: 17700156.
- Yang D, Keys B, Conti JD, Foulke L, Stellrecht K, Cook L, et al. JC polyomavirus nephropathy, a rare cause of transplant dysfunction: case report and review of literature. *Transpl Infect Dis.* 2017;19, <http://dx.doi.org/10.1111/tid.12654>. Epub 2017 Feb 22. PMID: 28036142.
- Aguilar J, Chang DH, Lin M, Hou J, Huang E, Kittleson M, et al. JC virus-associated nephropathy in a post-heart and -kidney transplantation patient. *Transpl Infect Dis.* 2020;22:e13288, <http://dx.doi.org/10.1111/tid.13288>. Epub 2020 Apr 23. PMID: 32282976.
- Wiegley N, Walavalkar V, Auja H, Chen LX, Huang Y, Lee BK, Jen KY. Clinicopathologic characteristics of JC virus nephropathy in kidney transplant recipients. *Transplantation.* 2021;105:1069–76, <http://dx.doi.org/10.1097/TP.0000000000003363>. PMID: 32639410.

Cristo Adonay Santana Quintana^{a,*},
Roberto Gallego Samper^a, María José Pena López^b,
Rafael Camacho Galán^c, Raquel Santana Estupiñán^a,
Sara Aladro Escribano^a, Juan Carlos Quevedo Reina^a,
Daniel Medina García^a, Yuliana Stefanía Daruiz D'Orazio^a,
Patricia Pérez Borges^a

^a Servicio de Nefrología, Hospital Universitario de Gran Canaria Doctor Negrín, Las Palmas de Gran Canaria, Spain

^b Servicio de Microbiología, Hospital Universitario de Gran Canaria Doctor Negrín, Las Palmas de Gran Canaria, Spain

^c Servicio de Anatomía Patológica, Hospital Universitario de Gran Canaria Doctor Negrín, Las Palmas de Gran Canaria, Spain

* Corresponding author.

E-mail address: adocsq@hotmail.com

(C.A. Santana Quintana).

2013-2514/© 2024 Published by Elsevier España, S.L.U. on behalf of Sociedad Española de Nefrología. This is an open access article under the CC BY-NC-ND license (<http://creativecommons.org/licenses/by-nc-nd/4.0/>). <https://doi.org/10.1016/j.nefro.2024.03.003>