

Our experience demonstrates that the use of online HDF and a calcium-rich bath with post-dilutional replacement using citrate anticoagulation without calcium replacement is a simple and safe alternative in patients with contraindications to the use of heparin resulting in no coagulation of the extracorporeal system.

REFERENCES

1. Warkentin TE, Levine MN, Hirsh J, Horsewood P, Roberts RS, Gent M, et al. Heparin-induced thrombocytopenia in patients treated with low-molecular-weight heparin or unfractionated heparin. *N Engl J Med.* 1995;332:1330–5.
2. Martel N, Lee J, Wells PS. Risk for heparin-induced thrombocytopenia with unfractionated and low-molecular-weight heparin thromboprophylaxis: a meta-analysis. *Blood.* 2005;106:2710–5.
3. Warkentin TE. Platelet-activating anti-PF4 disorders: An overview. *Semin Hematol.* 2022;59:59–71.
4. Hutchison CA, Dasgupta I. National survey of heparin-induced thrombocytopenia in the haemodialysis population of the UK population. *Nephrol Dial Transplant.* 2007;22:1680–4.
5. Chang JJY, Parikh CR. When heparin causes thrombosis: significance, recognition, and management of heparin-induced thrombocytopenia in dialysis patients: Hit in esrd. *Semin Dial.* 2006;19:297–304.

6. Yamamoto S, Koide M, Matsuo M, Suzuki S, Ohtaka M, Saika S, et al. Heparin-induced thrombocytopenia in hemodialysis patients. *Am J Kidney Dis.* 1996;28:82–5.
7. Apsner R, Buchmayer H, Gruber D, Sunder-Plassmann G. Citrate for long-term hemodialysis: prospective study of 1,009 consecutive high-flux treatments in 59 patients. *Am J Kidney Dis.* 2005;45:557–64.
8. Schneider M, Liefeldt L, Slowinski T, Peters H, Neumayer H-H, Morgera S. Citrate anticoagulation protocol for slow extended hemodialysis with the Genius dialysis system in acute renal failure. *Int J Artif Organs.* 2008;31:43–8.

Lucas Ramos*, Rosario Luxardo, María Soledad Crucelegui, Nadia Satera, Yuliana Jordán Ordoñez, Guillermo Rosa-Diez

Nephrology, Hospital Italiano de Buenos Aires, Ciudad Autónoma de Buenos Aires, Buenos Aires, Argentina

*Corresponding author.

E-mail addresses: lucasramos0994@gmail.com, guillermo.rosadiez@hospitalitaliano.org.ar (L. Ramos).

2013-2514/© 2024 Published by Elsevier España, S.L.U. on behalf of Sociedad Española de Nefrología. This is an open access article under the CC BY-NC-ND license (<http://creativecommons.org/licenses/by-nc-nd/4.0/>). <https://doi.org/10.1016/j.nefro.2024.03.001>

Compassionate use of tolvaptan in acquired megacolon secondary to autosomal dominant polycystic kidney disease (ADPKD)

Uso compasivo de tolvaptán en megacolon adquirido secundario a poliquistosis renal autosómica dominante (PQRAD)



Dear Editor,

Autosomal dominant polycystic kidney disease (ADPKD) is the most common hereditary kidney disease. Estimates of prevalence vary depending on the sample, ranging from 1 in 500 to 1 in 2000 persons. It is the fourth leading cause of end-stage renal disease (ESRD), accounting for 6–10 % of the population on renal replacement therapy (RRT).¹

It is characterized by the gradual appearance of renal cysts and progression to ESRD, as well as by the association of systemic manifestations such as arterial hypertension, intracranial aneurysms and polycystic liver disease. Cyst

growth and renal size are related, in addition to progression to ESRD, with symptoms associated with the abdominal compartment syndrome and compression of other structures, generating satiety, pain and intestinal pseudo-obstruction.²

Knowledge of this disease has been progressing in recent decades. Since the main ADPKD-related genes, PKD1 and PKD2, were identified in the 1990s,^{3,4} a close genotype-phenotype correlation has been established, as well as the identification of those genes that confer a higher risk of progression. In addition, new genes related with cyst generation (GANAB, DNAJB11 and ALG9)^{5–7} have been discovered, as well as some of the metabolic pathways involved in cystogenesis, such as the overexpression of cyclic adenosine monophosphate (cAMP). This has led to the development of drugs such as tolvaptan, a vasopressin V2 receptor antago-

DOI of original article:

<https://doi.org/10.1016/j.nefro.2023.01.007>.

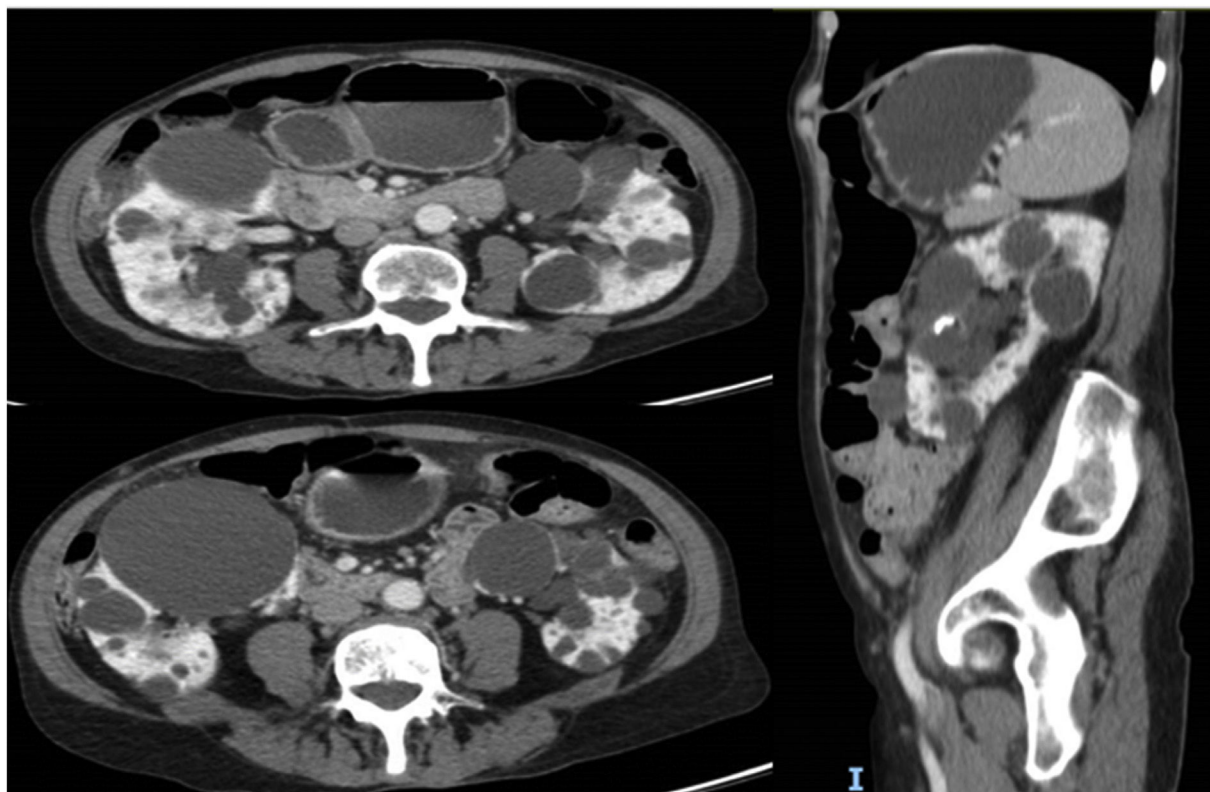


Figure 1 – Compression of intestinal loops by large renal cysts compatible with megacolon.

nist, which reduces cAMP levels in the collecting tubule and distal nephron, thus reducing fluid secretion into the cyst and cell proliferation, leading to a slowing of cystic development and disease progression.⁸

Currently, the indication for tolvaptan is limited to the objective of slowing the progression of renal disease and it is restricted to adult patients with CKD stages 1–4 and evidence of rapid progression.^{1,8,9} However, there are other potential benefits, such as the case we report below.

This is a 69-year-old woman with a history of hypertension, axonal sensory polyneuropathy due to Cerebellar Ataxia with Neuropathy and Vestibular Areflexia Syndrome (CANVAS) and ADPKD diagnosed at 40 years of age, with subsequent confirmation of PKD2 mutation. Throughout the course of the disease the following incidences stand out: evacuating puncture of the cysts compressing the renal artery approximately 30 years ago and several episodes of intestinal pseudo-obstruction justified by an acquired megacolon secondary to intestinal compression by the renal cysts (Fig. 1) that required the puncture and sclerosis of a large dominant cyst in the last year. Despite this, the patient continued to have difficulty swallowing and abdominal pain. At that time renal function remained normal and she did not present criteria for rapid progression, precluding the use of tolvaptan according to current indications. However, in September 2022, in agreement with the patient, we decided to trial compassionate treatment with tolvaptan, with the aim of decreasing abdom-

inal volume, as well as better pain control. She was prescribed 45 mg of tolvaptan in the morning and 15 mg eight hours later.

During follow-up in November and December 2022 the patient reported feeling better, with a decrease in the feeling of abdominal pressure, with no new episodes of intestinal pseudo-obstruction and decreased satiety and abdominal pain, which has allowed her to return to sports, travel and gain 1–2 kg of weight. The patient reports good tolerance to the aquaretic effects and no biochemical alterations in the analytical controls.

The effect of emptying the renal cysts was rapid, as usually occurs in the first 3–4 weeks after starting treatment with tolvaptan,¹⁰ a circumstance that could explain the rapid improvement of the patient.

In conclusion, ADPKD is an entity characterized by the appearance of renal cysts, progression to ESRD, associated systemic manifestations and symptomatology secondary to compression of structures by renal cysts. At present, the indications for the use of tolvaptan are restricted to slowing renal progression; however, the benefits may also include improvement of digestive symptoms, as in our case.

REFERENCES

1. Ars E, Bernis C, Fraga G, Furlano M, Martínez V, Martins J, et al. Documento de consenso de poliquistosis renal

- autosómica dominante. Revisión 2020. *Nefrología*. 2021;42:367–89, <http://dx.doi.org/10.1016/j.nefro.2021.05.009>.
2. Mikolajczyk AE, Te HS, Chapman AB. Gastrointestinal manifestations of autosomal-dominant polycystic kidney disease. *Clin Gastroenterol Hepatol*. 2017;15:17–24.
 3. Breuning MH, Snijdwint FG, Brunner H, Verwest A, Ijdo JW, Saris JJ, et al. Map of 16 polymorphic loci on the short arm of chromosome 16 close to the polycystic kidney disease gene (PKD1). *J Med Genet*. 1990;27:603–13.
 4. Peters DJM, Spruit L, Saris JJ, Ravine D, Sandkujil LA, Fossdal R, et al. Chromosome 4 localization of a second gene for autosomal dominant polycystic kidney disease. *Nat Genet*. 1993;5:359–62.
 5. Porath B, Gainullin VG, Cornec-Le Gall E, Dillinger EK, Heyer CM, Hopp K, et al. Mutations in GANAB, encoding the glucosidase II α subunit, cause autosomal-dominant polycystic kidney and liver disease. *Am J Hum Genet*. 2016;98:1193–207.
 6. Cornec Le Gall E, Olson RJ, Beese W, Heyer HM, Gainullin VG, Smith JM, et al. Monoallelic mutations to DNAJB11 cause atypical autosomal-dominant polycystic kidney disease. *Am J Hum Genet*. 2018;102:832–44.
 7. Beese W, Chang AR, Luo JZ, Triffo WJ, Moore BS, Gulati A, et al. ALG9 mutation carriers develop kidney and liver cysts. *J Am Soc Nephrol*. 2019;30:2091–102.
 8. Capuano I, Buonanno P, Riccio E, Amicone M, Pisani A. Therapeutic advances in ADPKD: the future awaits. *J Nephrol*. 2022;35:397–415.
 9. Ministerio de Sanidad, Agencia Española de Medicamentos y Productos Sanitarios. Informe de Posicionamiento Terapéutico de tolvaptan (Jinarc[®]) en poliquistosis renal autosómica dominante. IPT, 42/2022. V1. Available from: <https://www.aemps.gob.es/medicamentosUsoHumano/informesPublicos/docs/2022/IPT.42-2022-jinarc.pdf>.
 10. Irazabal MV, Torres VE, Hogan MC, Glockner J, King BF, Ofstie TG, et al. Short-term effects of tolvaptan on renal function and volume in patients with autosomal dominant polycystic kidney disease. *Kidney Int*. 2011;80:295–301.

Iris Viejo Boyano^{a,*}, Paul José Hernández Velasco^b,
Eduardo Gutiérrez Martínez^b

^a Servicio de Nefrología, Hospital Universitario i Politènic La Fe, Valencia, Spain

^b Servicio de Nefrología, Hospital Universitario 12 de Octubre, Madrid, Spain

*Corresponding author.

E-mail address: ivb_1993@hotmail.com (I. Viejo Boyano).

2013-2514/© 2024 Published by Elsevier España, S.L.U. on behalf of Sociedad Española de Nefrología. This is an open access article under the CC BY-NC-ND license (<http://creativecommons.org/licenses/by-nc-nd/4.0/>). <https://doi.org/10.1016/j.nefro.2024.03.002>

JC polyomavirus nephropathy in renal transplant patient: An uncommon guest

Nefropatía por poliomavirus JC en paciente trasplantado renal, un invitado infrecuente



Dear Editor,

BK virus (BKV) is the main cause of nephropathy associated with polyomavirus (NAPV) in renal transplantation and is an important cause of graft loss. In recent years, polyomavirus nephropathy has been associated with JC virus (JCV),¹ a less common entity with a later clinical presentation, which usually causes a delay in diagnosis. We present a case of nephropathy associated with JC polyomavirus (NAPV-JC) in a renal transplant patient, which is to our knowledge the first described in our country.

DOI of original article:
<https://doi.org/10.1016/j.nefro.2023.02.001>.

Our case is a 43-year-old male with a history of chronic kidney disease secondary to segmental and focal glomerulosclerosis on peritoneal dialysis since 2009, who received a deceased-donor kidney transplant in February 2011. He received basiliximab, steroids, tacrolimus and mycophenolate mofetil, and his maintenance therapy was: prednisone 5 mg/day, mycophenolate mofetil 2 g/day and tacrolimus (levels of 6–8 ng/dl).

During 2021 the patient presented a progressive deterioration of renal function with serum creatinine levels of 1.95 mg/dl as compared with baseline serum creatinine of 1.2–1.3 mg/dl (Table 1). Microbiological study of plasma and urine ruled out cytomegalovirus and KBV infection. Measurement of anti-HLA antibodies and an ultrasound of the abdomen did not show data of interest. Therefore, it was decided to perform a renal biopsy in April 2022.