

9. Bullard J, Dust K, Funk D, Strong JE, Alexander D, Garnett L, et al. Predicting infectious SARS-CoV-2 from diagnostic samples. *Clin Infect Dis*. 2020, <http://dx.doi.org/10.1093/cid/ciaa638> [accessed 06.06.20].
10. Roupael C, D'Amico G, Ricci K, Cywinski J, Miranda C, Koval C, et al. Successful orthotopic liver transplantation in a patient with a positive SARS-CoV-2 test and acute liver failure secondary to acetaminophen overdose. *Am J Transpl*. 2020;21:1312-6, <http://dx.doi.org/10.1111/ajt.16330>.

Diogo Francisco<sup>a,\*</sup>, Gonçalo Ávila<sup>a</sup>, Cristina Jorge<sup>a</sup>, Kamal Mansinho<sup>b</sup>, Cristina Toscano<sup>c</sup>, André Weigert<sup>a</sup>

<sup>a</sup> Serviço de Nefrologia do Hospital de Santa Cruz, Portugal  
<sup>b</sup> Serviço de Infecçiology do Hospital Egas Moniz, Portugal  
<sup>c</sup> Laboratório de Microbiologia Clínica e Biologia Molecular do Hospital Egas Moniz, Portugal

\*Corresponding author.

E-mail address: [diogofrbfrancisco@gmail.com](mailto:diogofrbfrancisco@gmail.com) (D. Francisco).

2013-2514/© 2022 Sociedad Española de Nefrología. Published by Elsevier España, S.L.U. This is an open access article under the CC BY-NC-SA license (<http://creativecommons.org/licenses/by-nc-sa/3.0/>).  
<https://doi.org/10.1016/j.nefro.2022.04.007>

## Online hemodiafiltration without calcium replacement using citrate as an anticoagulant and dialysis fluid with 3.5 mEq of post dilutional calcium in patients with heparin-induced thrombocytopenia: Report of 2 cases

### Hemodiafiltración online sin reposición de calcio utilizando citrato como anticoagulante y líquido de diálisis con 3,5 mEq de calcio posdilucional en pacientes con trombocitopenia inducida por heparina: reporte de 2 casos



Dear Editor,

Patients with renal disease on renal replacement therapy with hemodialysis require anticoagulation of the extracorporeal system and heparin is the most common.

Heparin-induced thrombocytopenia (HIT), a serious condition, occurs in patients exposed to heparin, regardless of the dose and route of administration, with a reported prevalence of around 5%.<sup>1,2</sup>

This condition is due to the development of autoantibodies against endogenous platelet factor 4 (PF4), which causes platelet activation, which in turn causes arterial and venous thrombosis in some severe cases.<sup>3</sup>

There are 2 types of HIT: type I, without significant decrease in platelet count or thrombosis; and type II, where there is thrombocytopenia with thrombosis, requiring the suspension of heparin and the use of another anticoagulant to treat thrombosis.

The presentation of HIT in hemodialysis patients motivates the search for alternatives for anticoagulation, such as the use

of predilution hemodiafiltration (HDF), continuous infusion of saline solution, use of citrate as an anticoagulant and even a change of modality to peritoneal dialysis.

The prevalence of HIT in hemodialysis patients may be up to 4%, although the presence of PF4 antibodies is higher in dialysis patients.<sup>4-6</sup>

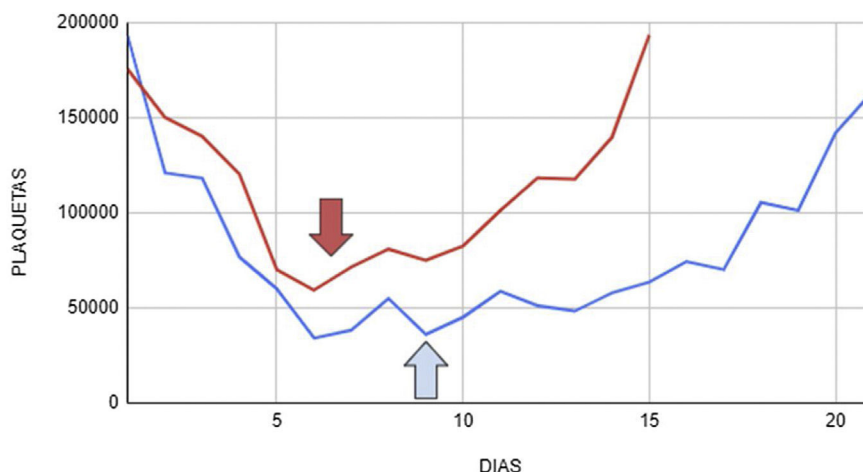
The use of citrate as an anticoagulant is common practice in continuous renal replacement therapy and requires the use of calcium replacement.<sup>7</sup> There are isolated reports of the use of citrate without calcium replacement in extended dialysis in patients with acute kidney failure.<sup>8</sup>

Online HDF is an increasingly common hemodialysis modality in patients with chronic kidney disease (CKD). We present two clinical cases of patients with CKD on chronic hemodialysis with a history of HIT, with the use of citrate as anticoagulant implemented during online HDF without calcium replacement.

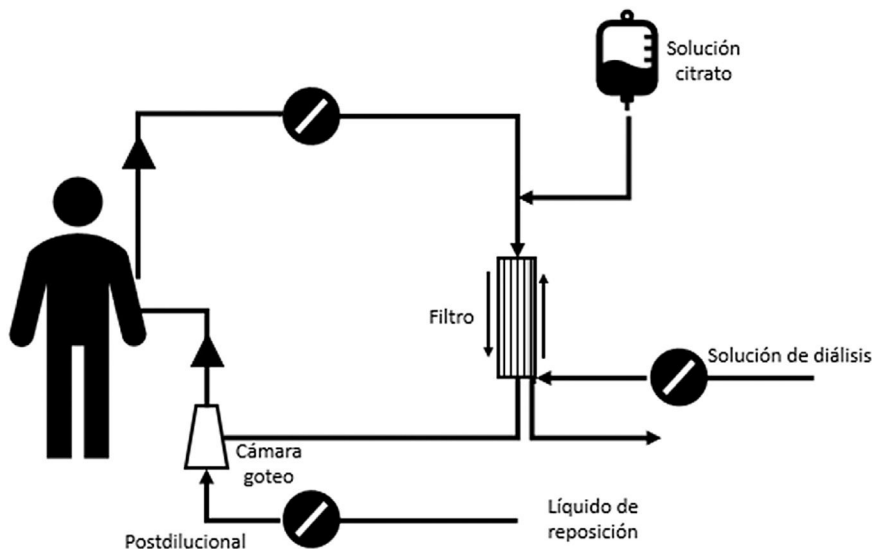
**Case A.** A 68-year-old male patient with a diagnosis of ANCA-p positive pauci-immune glomerulonephritis. With the progressive use of sodium heparin during dialysis sessions his platelet count decreased (Fig. 1) with positive anti-PF4, so we

DOI of original article:

<https://doi.org/10.1016/j.nefro.2023.01.006>.



**Figure 1** – Platelet count. Case A (red line). Case B (blue line) (arrows: heparin suspension and change to citrate). The color of the figure can only be seen in the electronic version of the article.



**Figure 2** – Diagram of online HDF with post-dilution replacement and use of predialysis citrate.

discontinued heparin, starting citrate as an anticoagulant to maintain chronic hemodialysis.

**Case B.** An 81-year-old female patient with a diagnosis of immune-mediated extra-capillary glomerulonephritis. With the progressive use of sodium heparin during dialysis sessions her platelet count progressively dropped (Fig. 1), with positive anti-PF4 and thrombosis of the right internal jugular vein, so we diagnosed HIT, discontinued heparin and started citrate as an anticoagulant.

The two patients performed post-dilutional online HDF, during 255 min, with Fresenius 5008 equipment, with Qb 350–400 mL/min Qd 500 mL/min, bath with calcium 3.5 mEq/L, sodium 138 mEq/L, potassium 2 mEq/L, bicarbonate 32 mEq/L, chlorine 109.5 mEq/L with high efficiency helixone FX 600–800 filters. The target replacement rate was between 20 and 24 L at each session. No calcium replacement was used in the venous branch, only calcium levels were monitored during the ses-

sions. The citrate solution used was Soluflex® 679S ACD (citric acid 0.8% sodium citrate 2.2%) at a citrate infusion rate varying between 200–300 mL/h connected to the circuit in the pre-filter arterial branch (Fig. 2). The technique included calcium measurement prior to dialysis, at 2 h and at the end of the dialysis session to avoid hypocalcemia during the first sessions. Patients and dialysis nurses were instructed in the detection of symptoms compatible with hypocalcemia.

Post-dilution replacement with a calcium-rich bath made it possible to maintain renal replacement therapy without producing thrombocytopenia or thrombotic episodes in patients diagnosed with HIT, avoiding coagulation of the extracorporeal system and episodes of hypocalcemia, without the need for calcium replacement as usually required by continuous renal replacement therapies.

We believe HIT is underdiagnosed in many dialysis clinics, although type II is a serious entity that implies a change in the prescription of anticoagulation during dialysis sessions.

Our experience demonstrates that the use of online HDF and a calcium-rich bath with post-dilutional replacement using citrate anticoagulation without calcium replacement is a simple and safe alternative in patients with contraindications to the use of heparin resulting in no coagulation of the extracorporeal system.

## REFERENCES

1. Warkentin TE, Levine MN, Hirsh J, Horsewood P, Roberts RS, Gent M, et al. Heparin-induced thrombocytopenia in patients treated with low-molecular-weight heparin or unfractionated heparin. *N Engl J Med.* 1995;332:1330–5.
2. Martel N, Lee J, Wells PS. Risk for heparin-induced thrombocytopenia with unfractionated and low-molecular-weight heparin thromboprophylaxis: a meta-analysis. *Blood.* 2005;106:2710–5.
3. Warkentin TE. Platelet-activating anti-PF4 disorders: An overview. *Semin Hematol.* 2022;59:59–71.
4. Hutchison CA, Dasgupta I. National survey of heparin-induced thrombocytopenia in the haemodialysis population of the UK population. *Nephrol Dial Transplant.* 2007;22:1680–4.
5. Chang JJY, Parikh CR. When heparin causes thrombosis: significance, recognition, and management of heparin-induced thrombocytopenia in dialysis patients: Hit in esrd. *Semin Dial.* 2006;19:297–304.

6. Yamamoto S, Koide M, Matsuo M, Suzuki S, Ohtaka M, Saika S, et al. Heparin-induced thrombocytopenia in hemodialysis patients. *Am J Kidney Dis.* 1996;28:82–5.
7. Apsner R, Buchmayer H, Gruber D, Sunder-Plassmann G. Citrate for long-term hemodialysis: prospective study of 1,009 consecutive high-flux treatments in 59 patients. *Am J Kidney Dis.* 2005;45:557–64.
8. Schneider M, Liefeldt L, Slowinski T, Peters H, Neumayer H-H, Morgera S. Citrate anticoagulation protocol for slow extended hemodialysis with the Genius dialysis system in acute renal failure. *Int J Artif Organs.* 2008;31:43–8.

Lucas Ramos\*, Rosario Luxardo, María Soledad Crucelegui, Nadia Satera, Yuliana Jordán Ordoñez, Guillermo Rosa-Diez

*Nephrology, Hospital Italiano de Buenos Aires, Ciudad Autónoma de Buenos Aires, Buenos Aires, Argentina*

\*Corresponding author.

E-mail addresses: [lucasramos0994@gmail.com](mailto:lucasramos0994@gmail.com), [guillermo.rosadiez@hospitalitaliano.org.ar](mailto:guillermo.rosadiez@hospitalitaliano.org.ar) (L. Ramos).

2013-2514/© 2024 Published by Elsevier España, S.L.U. on behalf of Sociedad Española de Nefrología. This is an open access article under the CC BY-NC-ND license (<http://creativecommons.org/licenses/by-nc-nd/4.0/>). <https://doi.org/10.1016/j.nefro.2024.03.001>

## Compassionate use of tolvaptan in acquired megacolon secondary to autosomal dominant polycystic kidney disease (ADPKD)

### Uso compasivo de tolvaptán en megacolon adquirido secundario a poliquistosis renal autosómica dominante (PQRAD)



Dear Editor,

Autosomal dominant polycystic kidney disease (ADPKD) is the most common hereditary kidney disease. Estimates of prevalence vary depending on the sample, ranging from 1 in 500 to 1 in 2000 persons. It is the fourth leading cause of end-stage renal disease (ESRD), accounting for 6–10 % of the population on renal replacement therapy (RRT).<sup>1</sup>

It is characterized by the gradual appearance of renal cysts and progression to ESRD, as well as by the association of systemic manifestations such as arterial hypertension, intracranial aneurysms and polycystic liver disease. Cyst

growth and renal size are related, in addition to progression to ESRD, with symptoms associated with the abdominal compartment syndrome and compression of other structures, generating satiety, pain and intestinal pseudo-obstruction.<sup>2</sup>

Knowledge of this disease has been progressing in recent decades. Since the main ADPKD-related genes, PKD1 and PKD2, were identified in the 1990s,<sup>3,4</sup> a close genotype-phenotype correlation has been established, as well as the identification of those genes that confer a higher risk of progression. In addition, new genes related with cyst generation (GANAB, DNAJB11 and ALG9)<sup>5–7</sup> have been discovered, as well as some of the metabolic pathways involved in cystogenesis, such as the overexpression of cyclic adenosine monophosphate (cAMP). This has led to the development of drugs such as tolvaptan, a vasopressin V2 receptor antago-

DOI of original article:  
<https://doi.org/10.1016/j.nefro.2023.01.007>.