



Influenza vaccine-induced leukocytoclastic vasculitis in a patient with a transplanted kidney

Vasculitis leucocitoclástica por vacuna de la influenza en un paciente trasplantado renal

Mr. Director:

Influenza virus or influenza (VI) is an RNA virus belonging to the Orthomyxoviridae family. Vaccination against this virus (VIV) is indicated in groups with a higher probability of VI transmission, developing complications or dying from the disease, such as renal transplant recipients.¹ It is considered a safe procedure, however vasculitis after VIV has been described exceptionally.^{2,3}

We describe the case of a 77-year-old woman, renal transplant recipient in 1999, due to bilateral urinary reflux and with a functioning graft. Her history included: positivity for total Hb core antibodies and Hbs antibodies and stage II-B diffuse large cell lymphoma treated with chemotherapy in 2006, achieving complete remission until the present. Her immunosuppressive treatment for more than five years was rapamycin and mycophenolate mofetil. She was administered VIV, fractionated virus (trivalent: A/Michigan/45/2015 (H1N1)pdm09-like strain; A/Hong Kong/4801/2014 (H3N2)-like strain; B/Brisbane/60/2008-like strain (Victoria lineage)). At 48 h after administration she began to feel unwell, complaining of joint pain, diarrhea and fever of 37 °C. Four days later, erythematous nodules appeared located on the arms and legs, 1-2 cm in diameter, poorly demarcated, painful on pressure, (Fig. 1).

A biopsy was performed showing a moderate perivascular inflammatory infiltrate, with predominance of polymorphonuclear cells, endothelial damage and presence of nuclear dust, located in papillary and reticular dermis with extension to subcutaneous cellular tissue with lobular and septal arrangement (Fig. 2). PAS, Grocott and Giemsa techniques were performed and no microorganisms were identified.

Laboratory tests with CRP, ESR, complement, urinalysis, immunity study (ANCA, cryoglobulins, rheumatoid factor, ANA) and microbiological study (HCV serology) were normal or negative.

With these data, she was diagnosed of leukocytoclastic vasculitis (LV) as a post-VVI reaction.

She was treated with prednisone 30 mg/24 h in a descending regimen for 20 days with complete resolution of symptoms.

Most vaccines used in European countries with specific vaccination programs, including Spain, are inactivated vac-

cines: whole, split or subunit vaccines. Around 1-10 % of people receiving VVI have some type of adverse effect, although most of them are mild and self-limited.

Different forms of vaccine-associated vasculitis have been described (Kawasaki disease,⁴ P-ANCA and C-ANCA positive⁵), but in the case of VIV the predominant form is cutaneous vasculitis,³ affecting mainly the elderly and women, conditions that were present in the patient described above. However, in most of the cases described, the causal relationship between immunization and VL has not been demonstrated.^{1,6}

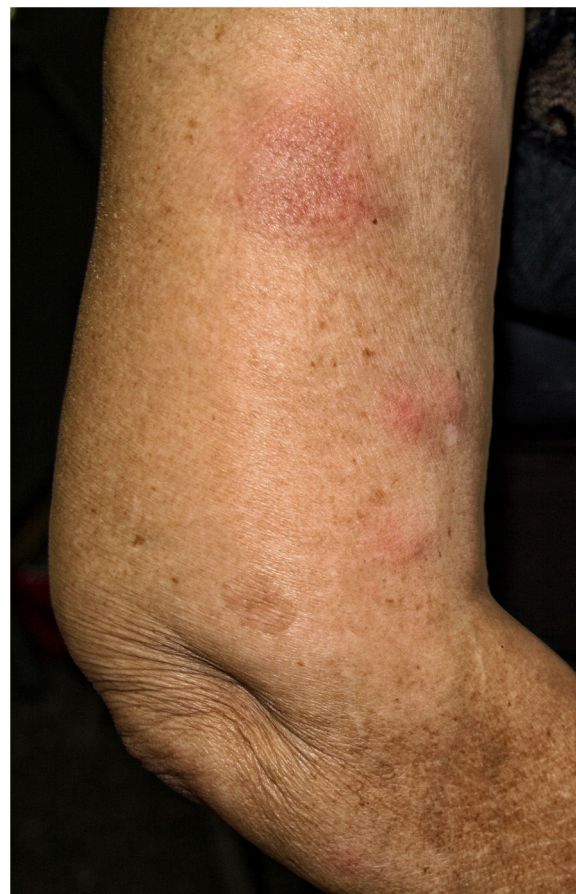

Fig. 1 – Erythematous and painful nodules on pressure located on the arms.

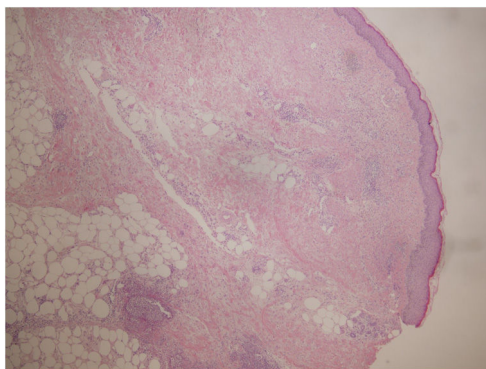


Fig. 2 – Hematoxylin-eosin (4×): skin with epidermis without significant histological alterations. Papillary and reticular dermis with moderate perivascular inflammatory infiltrate. Inflammation extends to subcutaneous cellular tissue.

Despite what has been published, this pathology is an infrequent adverse reaction, especially in immunosuppressed patients.¹ We have found only one case of a renal transplant patient with IgA nephropathy who developed IgA vasculitis after VIV.⁷ The authors propose the presence of autoimmunity as an etiopathogenic hypothesis. The patient described in this report is a renal transplant recipient due to urinary reflux who suffers a VL with no history of autoimmune diseases. This makes the case even more original since there has not been similar description previously.

The mechanism by which vasculitis secondary to VIV may occur remains unknown. The patient's immunosuppression, rapamycin and mycophenolate mofetil, produce a cytostatic effect on lymphocytes, although the effect it is not absolute. In addition, split virus vaccines (second generation), containing hemagglutinin, neuraminidase and part of the nucleoprotein and M protein, induce humoral immunity and are less reactogenic than whole virus vaccines. Although the inflammatory infiltrate is mainly neutrophilic, there are cases with a predominance of eosinophilic⁸ or mast cells.⁹ Therefore, and without ruling out other mechanisms, VIV could provoke the activation of autoreactive B/T cells, despite immunosuppressive treatment, the formation of antibodies and the deposition of immune complexes within the small vessels, which would lead to the activation of the complement system and leukocyte recruitment. However, one could also hypothesize an inflammatory response to some component of the vaccine that targets the endothelium and provokes small vessel vasculitis, causing direct cytopathic damage of the virus to the endothelial cell. In fact, a case of VL after VIV has been described in which an intradermal test was performed, showing a reticulated rash around the inoculation site probably caused by cytotoxic lymphokines.⁶

In addition, there are some cases of VL in solid organ transplant patients, where sirolimus is considered to be the causative agent. The relationship is established based on the temporality of the symptoms with respect to the introduction of the drug¹⁰ in the treatment. Our patient had been on this medication for more than five years, which makes us rule out sirolimus as the etiological agent.

There are no prospective studies on the progression of vasculitis after VIV to a systemic condition with or without renal involvement. For this reason, and taking into account the exceptionality of the case, we believe that this routine should not be restricted in general in renal transplant patients.

In conclusion, to our knowledge we present the first case of VL after VIV in a renal transplant patient.

REFERENCES

1. Fernández Prada M, Alonso Penanes P, Morales Del Burgo P, Pérez Martínez I, Villa Del Amo MC. Leukocytoclastic vasculitis after vaccination in a patient with inflammatory bowel disease. *Rev Esp Enferm Dig.* 2019;111(5):402–4.
2. Felicetti P, Trotta F, Bonetto C, Santuccio C, Brauchli Pernus Y, Burgner D, et al. Spontaneous reports of vasculitis as an adverse event following immunization: a descriptive analysis across three international databases. *Vaccine.* 2016;34:6634–40.
3. Watanabe T. Vasculitis following influenza vaccination: a review of the literature. *Curr Rheumatol Rev.* 2017;13(3):188–96.
4. Yung CF, Ma X, Cheung YB, Oh BK, Soh S, Thoon KC. Kawasaki disease following administration of 13-valent pneumococcal conjugate vaccine in young children. *Sci Rep.* 2019;9:14705.
5. Norton B, Kon SP, Perera R, Hull R. Vaccine: friend or foe? Double seropositive vasculitis following influenza vaccination. *Oxf Med Case Reports.* 2019;2019(5), omz031.
6. Barbarroja-Escudero J, Sánchez-González MJ, Vélez D, Abain S, Rodríguez-Rodríguez M, Alvarez-Mon M. Leukocytoclastic vasculitis after influenza vaccination: an allergy assessment. *J Investig Allergol Clin Immunol.* 2018;28(6):417–8.
7. McNally A, McGregor D, Searle M, Irvine J, Nicholas cross Henoch-Schönlein purpura in a renal transplant recipient with prior IgA nephropathy following influenza vaccination. *Clin Kidney J.* 2013;6(3):313–5.
8. Ichiyama S, Funasaka Y, Yamashita H, Tamura H, Inokuchi K, Saeki H. Leukocytoclastic vasculitis with eosinophilic infiltration associated with thalidomide therapy for multiple myeloma: a case report. *Allergol Int.* 2017;66:497–8, 9.
9. Inamura H, Igarashi Y, Kashiwase Y, Morioka J, Suzuki K, Kurosawa M. Mast cells in cutaneous allergic vasculitis: a case report. *Allergol Int.* 2006;55:343–5.
10. Schaffellner S, Jakoby E, Kniepeiss D, Stadlbauer V, Duller D, Iberer F, et al. Center Experience in Liver Transplantation (LTx): management of dermal side effects caused by sirolimus. *Int Immunopharmacol.* 2005;5(1):137–40.

González-Guerra Elena^{a,*}, Conde Taboada Alberto^a,
Lucía Campos Muñoz^a, María L. Suarez Solís^b,
Eduardo López-Bran^a, Ana Isabel Sánchez Fructuoso^c

^a Departamento de Dermatología, Hospital Clínico San Carlos, Madrid, Spain

^b Departamento de Anatomía Patológica, Hospital Clínico San Carlos, Madrid, Spain

^c Departamento de Nefrología, Hospital Clínico San Carlos, Madrid, Spain

* Corresponding author.

E-mail addresses: elenagonzalezguerra@yahoo.es
(E. González-Guerra), condetaboada@aedv.es
(A. Conde Taboada), luciacampos78@hotmail.com

(L.C. Muñoz), msuarezs@salud.madrid.org
 (M.L. Suarez Solís), lopezbran@salud.madrid.org
 (E. López-Bran), sanchezfructuoso@gmail.com
 (A.I. Sánchez Fructuoso).

2013-2514/© 2022 Sociedad Española de Nefrología. Published by Elsevier España, S.L.U. This is an open access article under the CC BY-NC-ND license (<http://creativecommons.org/licenses/by-nc-nd/4.0/>).
<https://doi.org/10.1016/j.nefro.2024.01.009>

Public-private collaboration in the gestion of hemodialysis vascular access

Colaboración público-privada en la gestión del acceso vascular para hemodiálisis



Dear Editor,

The native arteriovenous fistula (nAVF) is the vascular access (VA) of choice for haemodialysis (HD) as opposed to central venous catheters (CVC).^{1,2} Outcomes can be influenced by organisational and resource management factors.^{3,4} The high use of CVC in units is a long-standing problem,^{5,6} worsened by the COVID-19 pandemic,⁷ during which elective surgeries, including VA,⁸ were postponed and the public health service failed to resolve the problems of delayed interventions in all specialist areas.⁹ The high proportion of CVC makes it necessary to devise strategies to reverse this situation. From July 2021 at the Lalín centre, attached to Hospital de Santiago, an agreement was established that stipulated that the centre was responsible for the creation of VA which did not require hospital admission for patients in its area, including patients with advanced chronic kidney disease (ACKD). The hospital took care of VA requiring hospital admission (prosthesis or basilic superficialisation)^{4,5}; of patients who were dialysed at the centre from October 2020 to February 2022; 24 (53.3%) had CVC. Ten patients were assessed for nAVF at the external centre. Four patients were referred to the referral hospital; two because they required inpatient techniques and two refused the referral to the outpatient centre. Six autologous nAVF were performed at the external centre (two radiocephalic and four elbow nAVF), all of which were functional. The average time from mapping at the outpatient centre was 10.5 days and from mapping to surgery 11 days; at the hospital it was 73 days. The percentage of catheters decreased and the percentage of fistulae increased significantly in prevalent patients at the centre (Table 1). VA surgery does not require hospitalisation or general anaesthetic,¹⁰ so it can be performed at outpatient surgery centres outside hospital circuits, speeding up the intervention and not interfering with (or being interfered with by) more urgent or complex disorders. The strategy of combining resources and managing public and private capacities jointly from the referral hospital offers a valid and effective alterna-

Table 1 – Percentage of prevalent patients with CVC or nAVF/prosthesis at the end of the two study periods.

	Period 1: 1/October/2020 to 30/June/2021, before the start of the public-private partnership	Period 2: 1/July/2021 to 28/February/2022, after the start of the public-private partnership	p
Central venous catheter	26 (55.6%)	12 (26.7%)	<0.001
Native fistulae/prosthesis	20 (44.4%)	34 (73.3%)	

nAVF: native arteriovenous fistula.

tive to improve outcomes within a very short time, with the greatest safety.

REFERENCES

- Combe C, Mann J, Goldsmith D, Dellanna F, Zaoui P, London G, et al. Potential life-years gained over a 5-year period by correcting DOPPS-identified modifiable practices in haemodialysis: results from the European MONITOR-CKD5 study. *BMC Nephrol.* 2019;20:81.
- Al-Balas A, Lee T, Young CJ, Kepes JA, Barker-Finkel J, Allon M. The clinical and economic effect of vascular access selection in patients initiating hemodialysis with a catheter. *J Am Soc Nephrol.* 2017;28:3679-87.
- Gruss E, Portolés J, Jiménez P, Hernández T, Rueda JA, del Cerro J, et al. Seguimiento prospectivo del acceso vascular en hemodiálisis mediante un equipo multidisciplinar. *Nefrologia.* 2006;26:703-10.
- Gruss E, Portolés J, Caro P, Merino JL, López-Sánchez P, Tato A, et al. Grupo de Estudio del Acceso Vascular (AVE). Los modelos de atención al acceso vascular condicionan resultados heterogéneos en los centros de una misma comunidad. *Nefrologia.* 2010;30:310-6.
- Malek T, Alvarez-U de F, Gil MT, Moledous A, López-Collado M, Núñez C, et al. Cambios en el acceso vascular en una unidad de diálisis en los últimos años: problemas de planificación,