

- tubulointerstitial kidney disease due to mutations in UMOD and MUC1. *Kidney Int.* 2020;98:717–31.
6. Connaughton D, Kennedy C, Shril S, Mann N, Murray S, Williams P, et al. Monogenic causes of chronic kidney disease in adults. *Kidney Int.* 2019;95:914–28.
  7. Quaglia M, Musetti C, Ghiggeri GM, Battista G, Settanni F, Luciano R, et al. Unexpectedly high prevalence of rare genetic disorders in kidney transplant recipients with an unknown causal nephropathy. *Clin Transplant.* 2014;28:995–1003.
  8. Bullich G, Domingo-Gallego A, Vargas I, Ruiz P, Lorente-Grandoso L, Furlano M, et al. A kidney-disease gene panel allows a comprehensive genetic diagnosis of cystic and glomerular inherited kidney diseases. *Kidney Int.* 2018;94:363–71.
  9. Oh J, Shin J, Lee K, Lee C, Ko Y, Lee J. Clinical application of a phenotype-based NGS panel for differential diagnosis of inherited kidney disease and beyond. *Clin Genet.* 2021;99:236–49.

Verónica Andreina Barcia Odor\*, Elena Monfá, Benjamin de León, Catherine Martinez-Rosero, Silvia Sanchez-Montero, Carmen Barnes, Cristina Lucas, Arancha Sastre, Jorge Estifan, Mario Prieto

Servicio de Nefrología, Complejo Asistencial Universitario de León, León, Spain

\*Corresponding author.

E-mail address: [veronicaabarcia@gmail.com](mailto:veronicaabarcia@gmail.com)

(V.A. Barcia Odor).

2013-2514/© 2024 Published by Elsevier España, S.L.U. on behalf of Sociedad Española de Nefrología. This is an open access article under the CC BY-NC-ND license (<http://creativecommons.org/licenses/by-nc-nd/4.0/>). <https://doi.org/10.1016/j.nefro.2024.02.001>

## A rare case of two successful pregnancies in a female patient on hemodialysis

### Un caso raro de dos embarazos exitosos en una paciente en hemodiálisis



Dear Editor,

The occurrence of pregnancy in women with Chronic Kidney Disease (CKD) is unusual and these women are prone to more complications, especially among those on dialysis. Nevertheless, the high rate of complications such as hypertension, polyhydramnios, pre-eclampsia, restricted intrauterine growth and preterm birth make this physiological state a challenge in women with advanced CKD.

We report a case of a 29-year-old female patient with an obstetric history of a fetal loss at 31 weeks of gestation at the age of 18, in the sequence of an unsupervised pregnancy, diagnosed with gestational hypertension and severe pre-eclampsia at the time of delivery. At the age of 20, she presented with hypertension associated with thrombotic microangiopathy which required hemodialysis initiation. She was followed up as an outpatient in our hemodialysis department with dialysis prescription described in [Table 1](#). Additional medical history of anemia and mineral bone disease associated with CKD controlled with darbopoetin, intravenous iron and vitamin D analogs.

Five months after starting hemodialysis, she was found to be pregnant on a routine abdominal ultrasound, with an estimated gestational age of 12 weeks. At the time, she was

passing 1000 mL of urine a day and had a dry-weight of 42 kg. Immediately, dialysis prescription was changed to a 20 hours a week, as shown in [Table 1](#). Pre-dialysis urea values were kept under 60 mg/dL, potassium levels between 4.2 and 5.3 mg/dL, blood pressure maintained under 140/90 mmHg and dry weight was gradually incremented. An increment of dialysis time was proposed to the patient, but she promptly refused. Prenatal care and follow-up were carried out at the Obstetric Unit, with frequent ultrasound checks excluded fetal malformations. At 36 weeks of gestation she was submitted to a programmed cesarean section for pelvic presentation with active contractility. The newborn had a birthweight of 2375 g an Apgar score of 9 at 0' and 10 at 5' and normal neonatal development.

After delivery patient returned to similar dialysis prescription ([Table 1](#)). Also, she always refused a kidney transplant and there was suspicion of poor therapeutic adherence. Nine years later, she presented with amenorrhea for three consecutive months, and pregnancy was confirmed after the detection of beta-subunit of human chorionic gonadotropin (11568 mUI/mL). Fetal ultrasound showed an embryo with an estimated gestational age of 4/5 weeks. At the time, she was passing 500 mL of urine a day and had a dry weight of 57.5 kg. This time, the total weekly dialysis time was increased to 24 h per week ([Table 1](#)). Pre-dialysis urea values were kept under 30 mg/dL. Blood pressure was difficult to control and

DOI of original article:

<https://doi.org/10.1016/j.nefro.2022.01.004>.

**Table 1 – Dialysis prescription.**

	Before pregnancies	First pregnancy	Between pregnancies	Second pregnancy
Vascular access	Right brachiocephalic AVF	Right brachiocephalic AVF	Right brachiocephalic AVF	Right brachiocephalic AVF
Type of dialysis	On-line post-dilution hemodiafiltration	High-flux hemodialysis	On-line post-dilution hemodiafiltration	High-flux hemodialysis
Dialysis time	4 h	3 h	4 h	4 h
N° treatments per week	3	5	3	6
Dialyser	Fresenius FX100® dialyser 2.2 m <sup>2</sup>	Fresenius FX60® dialyser 1.4 m <sup>2</sup>	Fresenius FX100® dialyser 2.2 m <sup>2</sup>	Fresenius FX80® dialyser 1.8 m <sup>2</sup>
Blood flow rate (Qb) ml/min	400	250	450	300
Dialysate flow rate (Qd) ml/min	500	500	500	500
Anticoagulation	UFH	Enoxaparin	UFH	Enoxaparin
[Na <sup>+</sup> ] mmol/L	138	138	138	138
[K <sup>+</sup> ] mEq/L	2	2 + 40 mEq of potassium chloride 7.5%	2	2 + 40 mEq of potassium chloride 7.5%
[Ca <sup>2+</sup> ] mmol/L	1.25	1.50	1.25	1.50
[HCO <sub>3</sub> <sup>-</sup> ] mmol/L	28	28	28	26-28
Dry weight kg	42	41-51	45-57.5	57.5-65.3
Standard weekly Kt/V	2.6	3.8	2.8	5.12

AVF: arteriovenous fistula; UFH: unfractionated heparin.

varied between 130–180/60–100 mmHg. She was held on close obstetric monitoring, and at 25 weeks and 5 days of pregnancy she was referred to the Obstetrics Emergency Service due to decreased fetal movements and, after the diagnosis of fetal growth restriction, she was hospitalized for fetal pulmonary maturation and fetal surveillance. At 26 weeks and 4 days of pregnancy, an emergent cesarean section was performed due to a suspicion of placental abruption. With a birthweight of 660 g, and an Apgar score of 6 at 0' and 7 at 5' and 8 at 10', the newborn required prolonged hospitalization in the neonatal intensive care unit, which was uneventful and showed good neonatal development.

During both pregnancies, erythropoiesis-stimulating agents and intravenous iron dosing was increased. The patient's hemoglobin was maintained at 10–12 g/dl with the use of darbepoetin alpha once a week and IV iron sucrose dosage enough to maintain transferrin saturation of 30% or greater per unit protocol. Anti-hypertensive therapy was also changed in both cases with immediate suspension of angiotensin-converting enzyme-inhibitor and furosemide and the introduction of alpha-methyl dopa (while maintaining carvedilol and long-acting nifedipine). The patient also received multivitamin, calcium carbonate, and folic acid throughout the pregnancies. Programmed adjustment of the dry weight was made by revising the estimated dry weight weekly to an expected weight gain during pregnancy progression, and she was allowed unlimited protein intake. Metabolic alkalosis was also prevented by closely following acid-base status and adjusting dialysate bicarbonate concentration accordingly.

The two main determinants of hemodialysis schedule are dialysis frequency and dialysis duration that significantly correlated with prematurity and delivery of a small for gestational age baby.<sup>1</sup> The increase in dialysis time ensures a less uremic environment for the fetus, allows the mother a more liberal diet and fluid intake. It also helps to control

hypertension and reduce the amplitude of blood volume and electrolyte shifts.<sup>2-6</sup> Although no randomized prospective trials of pregnant women on dialysis exist, retrospective data suggest maintaining pre-dialysis BUN values at ≤50 mg/dl is an appropriate goal.<sup>2,3,5,6</sup>

Careful attention needs to be paid to dialysis strategy, anemia control, fluid balance, control of hypertension, nutrition, and close monitoring of fetal well-being and maternal morbidities. Approaching pregnancy in a CKD patient in hemodialysis requires careful multidisciplinary management among nephrologists, obstetricians, nutritionists, nurses and dialysis staff.

### Authors' contributions

João Carvão, Pedro Vieira and Luís Resende provided medical care of the patient. João Carvão wrote the manuscript. Luís Resende and Pedro Vieira reviewed the literature. All authors edited the manuscript. João Carvão is the article guarantor

### Statement of ethics

Informed consent was obtained for this report.

### Funding sources

No subsidies or grants contributed to this work.

### Conflicts of interest

The authors have no conflicts of interest to declare.

## REFERENCES

- Piccoli GB, Minelli F, Versino E, Cabiddu G, Attini R, Vigotti FN, et al. Pregnancy in dialysis patients in the new millennium: a systematic review and meta-regression analysis correlating dialysis schedules and pregnancy outcomes. *Nephrol Dial Transplant*. 2016;31:1915–34, <http://dx.doi.org/10.1093/ndt/gfv395>.
- Holley JL, Reddy SS. Pregnancy in dialysis patients: a review of outcomes complications, and management. *Semin Dial*. 2003;16:384–8, <http://dx.doi.org/10.1046/j.1525-139X.2003.16085.x>.
- Manisco G, Potì M, Maggiulli G, Di Tullio M, Losappio V, Vernaglione L. Pregnancy in end-stage renal disease patients on dialysis: how to achieve a successful delivery. *Clin Kidney J*. 2015;8:293–9, <http://dx.doi.org/10.1093/ckj/sfv016>.
- Yang LY, Thia EWH, Tan LK. Obstetric outcomes in women with end-stage renal disease on chronic dialysis: a review. *Obstet Med*. 2010;3:48–53, <http://dx.doi.org/10.1258/om.2010.100001>.
- Giatras I, Levy DP, Malone FD, Carlson JA, Jungers P. Pregnancy during dialysis: case report and management guidelines. *Nephrol Dial Transplant*. 1998;13:3266–72, <http://dx.doi.org/10.1093/ndt/13.12.3266>.
- Hou SH. Pregnancy in women on haemodialysis and peritoneal dialysis. *Baillieres Clin Obstet Gynaecol*. 1994;8:481–500, [http://dx.doi.org/10.1016/S0950-3552\(05\)80332-3](http://dx.doi.org/10.1016/S0950-3552(05)80332-3).

João Carvão<sup>a,\*</sup>, Ana Calhau<sup>b</sup>, Luís Resende<sup>a</sup>, Carlota Vida<sup>a</sup>, Francisca Silva<sup>a</sup>, Pedro Vieira<sup>a</sup>, Gil Silva<sup>a</sup>

<sup>a</sup> Nephrology Department, Hospital Central do Funchal, Funchal, Portugal

<sup>b</sup> Obstetrics and Gynaecology Department, Hospital Central do Funchal, Funchal, Portugal

\* Corresponding author.

E-mail address: [jnjarcao@campus.ul.pt](mailto:jnjarcao@campus.ul.pt) (J. Carvão).

2013-2514/© 2022 Sociedad Española de Nefrología. Published by Elsevier España, S.L.U. This is an open access article under the CC BY-NC-ND license (<http://creativecommons.org/licenses/by-nc-nd/4.0/>). <https://doi.org/10.1016/j.nefro.2022.01.012>

## Is the VasQ™ device useful in the maturation of native arteriovenous fistulas? A single-center experience

## ¿Es útil el dispositivo VasQ™ en la maduración de las fístulas arteriovenosas nativas? Experiencia de nuestro centro



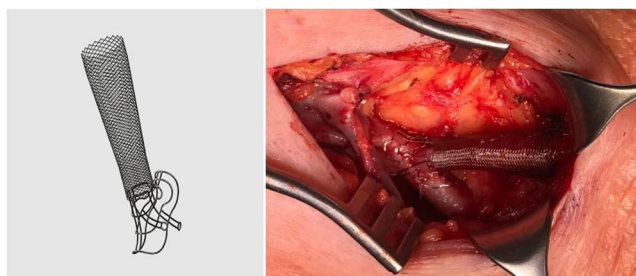
Dear Editor,

Native arteriovenous fistulas (nAVF) are the vascular access of choice in patients with stage 5 chronic kidney disease on dialysis (CKD 5D). However, some studies report maturation failure rates ranging from 20% to 50%.<sup>1</sup> According to the latest data from the Registre de Malalts Renals de Catalunya (RMRC) [Catalan Registry of Renal Patients],<sup>2</sup> the rate of use of nAVF has reduced (55.8%) and only 36.1% of incidents in 2020 involved this type of vascular access.

From a pathophysiological point of view, low shear stress has been associated with increased stress in the walls of the efferent vein, turbulent flow and the generation of accelerated venous neointimal hyperplasia as the main cause of juxta-anastomotic stenosis. These mechanisms are related to the release of a host of inflammatory factors that induce platelet aggregation, migration of myofibroblasts from the media to the intima layer and, ultimately, thrombosis and loss of vascular access.<sup>3</sup>

The VasQ™ external device (Laminate Ltd., Tel Aviv, Israel) was developed with these problems in mind. It consists of

two parts, a neck and arm, made of nitinol, and is implanted by the vascular surgeon at the surgical anastomosis and outside the first portion of the efferent vein (Fig. 1). This device enables the angle at the surgical anastomosis to be increased to 40–50°, resulting in a more uniform or laminar vascular flow and less stress at the juxta-anastomotic area of the vein (conical arrangement), as well as having a possible protective effect



**Figure 1** – VasQ™ external device (Laminate Ltd., Tel Aviv, Israel).

DOI of original article:

<https://doi.org/10.1016/j.nefro.2023.01.011>.