

- southeastern Spain: a study of attitudes toward organ donation. *Am J Transplant.* 2007;7:2020-30.
5. Edwards TM, Essman C, Thornton JD. Assessing racial and ethnic differences in medical student knowledge, attitudes and behaviors regarding organ donation. *J Natl Med Assoc.* 2007;99:131.
  6. Rydzewska M, Drobek NA, Małyszko ME, Zajkowska A, Małyszko J. Opinions and attitudes of medical students about organ donation and transplantation. *Transplant Proc.* 2018;50:1939-45.
  7. Figueroa CA, Mesfum ET, Acton NT, Kunst AE. Medical students' knowledge and attitudes toward organ donation: results of a Dutch survey. *Transplant Proc.* 2013;45:2093-7.
  8. Ohwaki K, Yano E, Shirouzu M, Kobayashi A, Nakagomi T, Tamura A. Factors associated with attitude and hypothetical behaviour regarding brain death and organ transplantation: comparison between medical and other university students. *Clin Transplant.* 2006;20:416-22.
  9. Borenstein M, Hedges LV, Higgins JP, Rothstein HR. *Introduction to meta-analysis.* UK: Wiley Chichester; 2011.
  10. Borenstein MJ, Hedges LV, Higgins J, Rothstein H. *Comprehensive meta-analysis vers. 3.3 [Computer program].* Englewood, NJ: Biostat, Inc; 2005.
- Antonio Ríos<sup>a,\*</sup>, Marina Iniesta-Sepúlveda<sup>d</sup>, Pablo Ramírez<sup>a,b,c</sup>, Ana Isabel López-Navas<sup>a,d</sup>
- <sup>a</sup> Proyecto Colaborativo Internacional Donante, Murcia, Spain  
<sup>b</sup> Departamento de Cirugía, Pediatría, Ginecología y Obstetricia, Universidad de Murcia, Murcia, Spain  
<sup>c</sup> Unidad de Trasplantes, Hospital Clínico Universitario Virgen de la Arrixaca - IMIB, Murcia, Spain  
<sup>d</sup> Departamento de Psicología, Universidad Católica de Murcia, UCAM, Murcia, Spain
- \* Corresponding author.  
 E-mail address: [arzrios@um.es](mailto:arzrios@um.es) (A. Ríos).
- 2013-2514/© 2021 Sociedad Española de Nefrología. Published by Elsevier España, S.L.U. This is an open access article under the CC BY-NC-ND license (<http://creativecommons.org/licenses/by-nc-nd/4.0/>).  
<https://doi.org/10.1016/j.nefro.2021.04.020>

## Does food ingestion during hemodialysis lead to change in hepatic oxygenation?

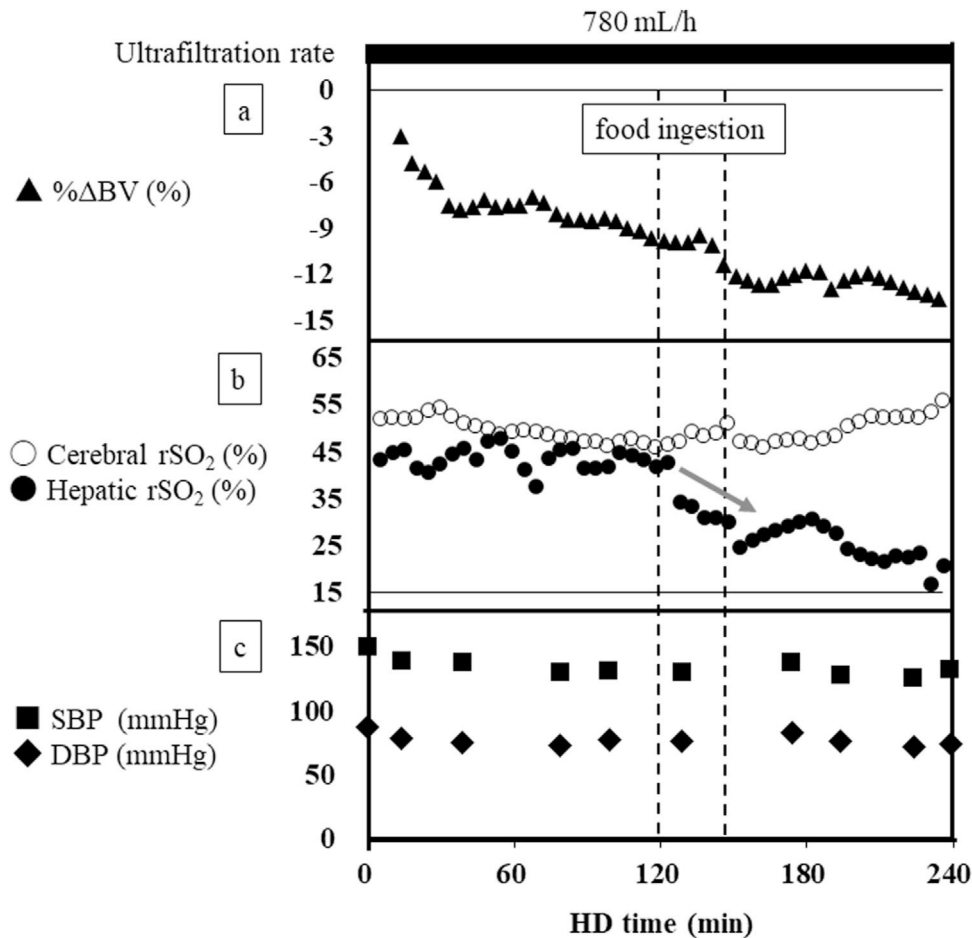
## La ingestión de alimentos durante la hemodiálisis, ¿produce cambios en la oxigenación hepática?

Dear Editor,

Food ingestion during hemodialysis (HD) reportedly decreases relative changes in blood volume (% $\Delta$ BV).<sup>1</sup> However, the influence of intradialytic food ingestion on changes in systemic tissue oxygenation remains unclear. Here we report a case of deteriorated hepatic oxygenation with food ingestion during HD despite cerebral oxygenation being well maintained. A 68-year-old woman received HD therapy three times per week due to chronic glomerulonephritis. She usually ate a meal at each HD session, after which intradialytic hypotension (IDH) sometimes occurred. Therefore, in addition to the blood pressure measurement, we monitored the % $\Delta$ BV using a BV monitor (Nikkiso, Tokyo, Japan). Furthermore, cerebral and hepatic regional oxygen saturation (rSO<sub>2</sub>) were monitored using an INVOS 5100c oxygen saturation monitor (Covidien Japan, Tokyo, Japan) to investigate the association between changes in tissue oxygenation and food ingestion during HD with her informed consent. She ingested 100 g of rice, 200 g of side dishes, and 200 mL of water between 120 min and 150 min after HD initiation. During this monitoring session, her blood

pressure did not change, while the % $\Delta$ BV decreased soon after food ingestion. In addition, prior to the decrease in % $\Delta$ BV, the hepatic rSO<sub>2</sub> rapidly decreased in response to food ingestion, whereas the cerebral rSO<sub>2</sub> was maintained until the end of HD (Fig. 1).

Intrahepatic circulation consists of two different blood supply, one is from hepatic artery and the other is from portal vein. Oxygen saturation in portal vein was low compared with that in systemic arterial circulation, including hepatic artery.<sup>2,3</sup> Hepatic rSO<sub>2</sub> are usually maintained during HD without IDH and food ingestion.<sup>4</sup> In addition, the deterioration of hepatic oxygenation would precede IDH onset during HD.<sup>5</sup> However, investigations of the influence of intradialytic food ingestion to the change in hepatic oxygenation has been limited. In this case, deterioration of hepatic oxygenation in response to food ingestion during HD were confirmed prior to the decrease in % $\Delta$ BV, and there might be possible two reasons to explain these associations. First, in animal experiments, the increase in oxygen consumption in the blood flowing through the intestine was confirmed in response to food ingestion.<sup>6</sup> Therefore, portal blood into the liver might decrease the oxygen saturation. Second, portal venous blood flow increased and hepatic



**Fig. 1 – (a) Changes in % $\Delta$ BV during hemodialysis. (b) Changes in cerebral and hepatic rSO<sub>2</sub> during hemodialysis. Grey arrow represents the decrease in hepatic rSO<sub>2</sub> associated with food ingestion. (c) Changes in SBP, DBP and HR during hemodialysis. % $\Delta$ BV, relative change in blood volume; DBP, diastolic blood pressure; HR, heart rate; rSO<sub>2</sub>, regional oxygen saturation; SBP, systolic blood pressure; UFR, ultrafiltration rate.**

artery blood flow decreased after food ingestion,<sup>7</sup> which would be associated with the regulation of a hepatic artery buffer response.<sup>8,9</sup> Because of the increase in portal vein blood flow (low oxygen saturation) and the decrease in hepatic arterial blood flow (high oxygen saturation),<sup>7</sup> hepatic rSO<sub>2</sub> might decrease during HD with food ingestion. In contrast to the deterioration of hepatic oxygenation associated with intradialytic food ingestion, cerebral oxygenation was maintained during HD in this case. This result may be explained by the fact that regulation of the systemic circulation usually prioritizes cerebral blood flow and oxygenation at the expense of blood flow and oxygen supply to other compartments, including hepatic circulation.<sup>4</sup> However, precise mechanisms regarding the association between intradialytic food ingestion and changes in systemic tissue oxygenation, including the liver, has not been elucidated and further studies are needed to clarify these associations during HD. Based on our experience, food ingestion during HD was possibly associated with the rapid deterioration of hepatic oxygenation; therefore, changes in hepatic oxygenation with food ingestion during HD should be carefully considered in the clinical setting of HD therapy.

## Funding

This work was supported by a grant from the Japanese Association of Dialysis Physicians (JADP Grant 2017-9) and JSPS KAKENHI under Grant No. JP20K11534 to SO. The funder of this study had no role in the study design, collection, analysis and interpretation, writing, or decision to submit the manuscript for publication.

## Conflict of interest

The authors have no conflicts of interest to declare.

## Acknowledgement

We thank the study participant and the staff of the clinical dialysis centre in Minami-Uonuma City Hospital.

## REFERENCES

- Shibagaki Y, Takaichi K. Significant reduction of the large-vessel blood volume by food intake during hemodialysis. *Clin Nephrol.* 1998;49:49-54.
  - Kitai T, Tanaka A, Tokuka A, Tanaka K, Yamaoka Y, Ozawa K, et al. Quantitative detection of hemoglobin saturation in the liver with near-infrared spectroscopy. *Hepatology.* 1993;18:926-36, <http://dx.doi.org/10.1002/hep.1840180426>.
  - Hughes S, Yang W, Juszczak M, Jones GL, Powis SH, Seifalian AM, et al. Effect of inspired oxygen on portal and hepatic oxygenation: effective arterialization of portal blood by hyperoxia. *Cell Transplant.* 2004;13:801-8, <http://dx.doi.org/10.3727/000000004783983413>.
  - Ookawara S, Ito K, Ueda Y, Miyazawa H, Hayasaka H, Kofuji M, et al. Differences in tissue oxygenation and changes in total hemoglobin signal strength in the brain, liver, and lower-limb muscle during hemodialysis. *J Artif Organs.* 2018;21:86-93, <http://dx.doi.org/10.1007/s10047-017-0978-1>.
  - Imai S, Ookawara S, Ito K, Kiryu S, Tabei K, Morishita Y. Deterioration of hepatic oxygenation precedes an onset of intradialytic hypotension with little changes in blood volume during hemodialysis. *Blood Purif.* 2018;45:345-6, <http://dx.doi.org/10.1159/000486232>.
  - Hentz F, Kozloski GV, Zeni D, Brun MV, Stefanello S. Relationship between level of forage intake, blood flow and oxygen consumption by splanchnic tissues of sheep fed a tropical grass forage. *J Anim Physiol Anim Nutr (Berl).* 2017;101:121-6, <http://dx.doi.org/10.1111/jpn.12519>.
  - Berzigotti A, De Gottardi A, Vukotic R, Siramolpiwat S, Abalde JG, Garcia-Pagan JC, et al. Effect of meal ingestion on liver stiffness in patients with cirrhosis and portal hypertension. *PLOS ONE.* 2013;8:e58742, <http://dx.doi.org/10.1371/journal.pone.0058742>.
  - Lautt WW. Mechanism and role of intrinsic regulation of hepatic arterial blood flow: Hepatic arterial buffer response. *Am J Physiol.* 1985;249:G549-56, <http://dx.doi.org/10.1152/ajpgi.1985.249.5.G549>.
  - Richter S, Mucke I, Menger MD, Vollmar B. Impact of intrinsic blood flow regulation in cirrhosis: maintenance of hepatic arterial buffer response. *Am J Physiol.* 2000;279:G454-62, <http://dx.doi.org/10.1152/ajpgi.2000.279.2.G454>.
- Sojiro Imai<sup>a</sup>, Kiyonori Ito<sup>b</sup>, Susumu Ookawara<sup>b,\*</sup>, Satoshi Kiryu<sup>a</sup>, Miho Iguchi<sup>a</sup>, Hidenori Sanayama<sup>c</sup>, Masafumi Kakei<sup>d</sup>, Kaoru Tabei<sup>d</sup>, Yoshiyuki Morishita<sup>b</sup>
- <sup>a</sup> Department of Dialysis, Minami-Uonuma City Hospital, Niigata, Japan  
<sup>b</sup> Division of Nephrology, Department of Integrated Medicine, Saitama Medical Center, Jichi Medical University, Saitama, Japan  
<sup>c</sup> Division of Neurology, Department of Integrated Medicine, Saitama Medical Center, Jichi Medical University, Saitama, Japan  
<sup>d</sup> Department of Internal Medicine, Minami-Uonuma City Hospital, Niigata, Japan
- \* Corresponding author.  
 E-mail address: [su-ooka@hb.tp1.jp](mailto:su-ooka@hb.tp1.jp) (S. Ookawara).
- 2013-2514/© 2021 Sociedad Española de Nefrología. Published by Elsevier España, S.L.U. This is an open access article under the CC BY license (<http://creativecommons.org/licenses/by/4.0/>).  
<https://doi.org/10.1016/j.nefro.2022.11.009>

## Erythematous-violaceous and bullous skin lesions after administration of iodinated contrast in a patient on hemodialysis. A case of fixed drug eruption due to iodinated contrast

### Lesiones cutáneas eritematovioláceas y ampollosas tras administración de contraste yodado en un paciente en hemodiálisis. Un caso de exantema fijo medicamentoso por contraste yodado

Dear Editor,

Non-immediate hypersensitivity adverse reactions secondary to the use of iodinated contrast generally occur between 6 and 72 h after exposure,<sup>1</sup> with the most common manifestation being maculopapular rash, urticaria with or without

angioedema and contact dermatitis. Most cases involve a mild to moderate acute rash. Severe late skin reactions are rare, but there have been reports of acute generalised exanthematous pustulosis, DRESS syndrome, vasculitis, Stevens-Johnson syndrome and toxic epidermal necrolysis.<sup>2</sup> Fixed drug eruption (FDE) is another non-immediate hypersensitivity reaction that