

therapy is unknown. The report of these cases is of major role for better understanding the pathophysiology of this disease and in order to improve treatment and prognosis offered to this rare group of patients.

REFERENCES

1. Weltgesundheitsorganisation. In: Swerdlow SH, Campo E, Harris NL, Jaffe ES, Pileri SA, Stein H, et al., editors. WHO classification of tumours of haematopoietic and lymphoid tissues. Revised 4th ed. Lyon: International Agency for Research on Cancer; 2017, 585 p. (World Health Organization classification of tumours).
2. Wanchoo R, Bernabe Ramirez C, Barrientos J, Jhaveri KD. Renal involvement in chronic lymphocytic leukemia. *Clin Kidney J.* 2018;11:670–80.
3. Strati P, Shanafelt TD. Monoclonal B-cell lymphocytosis and early-stage chronic lymphocytic leukemia: diagnosis, natural history, and risk stratification. *Blood.* 2015;126:454–62.
4. Strati P, Nasr SH, Leung N, Hanson CA, Chaffee KG, Schwager SM, et al. Renal complications in chronic lymphocytic leukemia and monoclonal B-cell lymphocytosis: the Mayo Clinic experience. *Haematologica.* 2015;100:1180–8.
5. Ravindran A, Fervenza FC, Smith RJH, Sethi S. C3 glomerulopathy associated with monoclonal Ig is a distinct subtype. *Kidney Int.* 2018;94:178–86.
6. Scott R. Leukæmia. *Lancet.* 1957;269:1162–7.
7. Poitou-Verkinder A-L, Francois A, Drieux F, Lepretre S, Legallier B, Moulin B, et al. The spectrum of kidney pathology in B-cell chronic lymphocytic leukemia/small lymphocytic lymphoma: a 25-year multicenter experience. *PLOS ONE.* 2015;10:e0119156.
8. Cambier J-F, Ronco P. Onco-nephrology: glomerular diseases with cancer. *Clin J Am Soc Nephrol.* 2012;7:1701–12.
9. Mallouk A, Pham P-TT, Pham P-CT. Concurrent FSGS and Hodgkin's lymphoma: case report and literature review on the link between nephrotic glomerulopathies and hematological malignancies. *Clin Exp Nephrol.* 2006;10:284.
10. Luciano RL, Brewster UC. Kidney involvement in leukemia and lymphoma. *Adv Chronic Kidney Dis.* 2014;21:27–35.
11. Senej FD, Federgreen WR, Stein H, Kashgarian M. A review of nephrotic syndrome associated with chronic lymphocytic leukemia. *Arch Intern Med.* 1986;146:137–41.
12. Chauvet S, Frémeaux-Bacchi V, Petitprez F, Karras A, Daniel L, Burtsey S, et al. Treatment of B-cell disorder improves renal outcome of patients with monoclonal gammopathy-associated C3 glomerulopathy. *Blood.* 2017;129:1437–47.
13. Ravindran A, Fervenza FC, Smith RJH, Sethi S. C3 glomerulopathy associated with monoclonal Ig is a distinct subtype. *Kidney Int.* 2018;94:178–86. *Kidney Int.* 2018;94:1025.
14. Hallek M. Chronic lymphocytic leukemia: 2020 update on diagnosis, risk stratification and treatment. *Am J Hematol.* 2019;94:1266–87.
15. Servais A, Noël L-H, Roumenina LT, Le Quintrec M, Ngo S, Dragon-Durey M-A, et al. Acquired and genetic complement abnormalities play a critical role in dense deposit disease and other C3 glomerulopathies. *Kidney Int.* 2012;82:454–64.

Filipa Silva^{a,*}, Joana Tavares^a, Rita Pinho Peixeiro^b, João Oliveira^a, Diana Fernandes^c, Ana Castro^a, Sofia Santos^a, Rita Coutinho^b, Cristina Freitas^a, Josefina Santos^a, João Pedro Pimentel^a, Jorge Coutinho^b, António Cabrita^a

^a Nephrology Department, Centro Hospitalar e Universitário do Porto, Portugal

^b Hematology Department, Centro Hospitalar e Universitário do Porto, Portugal

^c Internal Medicine Department, Unidade Local de Saúde do Nordeste, Portugal

*Corresponding author.

E-mail address: filipasofiasantossilva@gmail.com (F. Silva).

0211-6995/© 2020 Sociedad Española de Nefrología. Published by Elsevier España, S.L.U. This is an open access article under the CC BY-NC-ND license (<http://creativecommons.org/licenses/by-nc-nd/4.0/>). <https://doi.org/10.1016/j.nefro.2020.08.010>

Letter to the Editor

Acute interstitial nephritis in a patient with chronic idiopathic urticaria

Nefritis intersticial aguda en un paciente con urticaria crónica idiopática

Dear Editor,

Acute interstitial nephritis (AIN) which is characterized as inflammation and oedema around renal tubuli mostly due

to hypersensitivity to drugs, has been reported to be underlying aetiology among 5–27% of acute kidney injury cases in hospitalized patients.¹ Chronic idiopathic urticaria (CIU), is an intrinsic immunological abnormality independent of external

Table 1 – Clinical and laboratory findings of the patient.

Parameter	Patient
Age (years)	53
Gender	Female
Complain	Nausea
Blood pressure (mmHg)	120/80
Serum creatinine level (mg/dL)	0.65/1.64/2.21/0.82
6 months earlier/at admission/during AKI/last visit	
Proteinuria level (g/d)	1.3
At admission	
Albuminuria (mg/d)	98
At admission	
Beta-2 microglobulinuria level ($\mu\text{g/L}$)	21,300
At admission	
Past drug history for the last 6 months	Methylprednisolone, diclofenac, dexketoprofen, and omalizumab
Serum ANA, anti dsDNA, and ANCA test results	Negative
Present drug history	Gliclazide, metformin, bilastine, and omalizumab
Diagnosis based on	Clinical and histopathological data
Comorbid diseases	Diabetes mellitus, chronic idiopathic urticaria
Renal pathology	Acute interstitial nephritis accompanied with chronic interstitial injury and early stage of diabetic nephropathy

causes without a triggering stimulus like stress, physical factor, drug and food. It usually affects females with a prevalence of 1% and mostly begins at the age of 30–50 years.² Diagnosis mostly depend on chronic recurrent itching persisting at least six weeks with exclusion of diseases like infections, malignities, auto-immune and auto-inflammatory diseases.^{2,3} Treatment is needed for cumbersome symptom of pruritis and life-threatening medical emergency of angioedema. Omalizumab, which is recombinant humanized monoclonal antibody for immunoglobulin (Ig) E is advised for treatment of CIU as the third or fourth line of therapy after histamine receptor type 1 (H_1) antihistamines and leukotriene receptor antagonists are unsuccessful.^{3,4}

A 53-year-old female patient with diabetes mellitus, hysterectomy and CIU had symptoms of nausea and fatigue. In her medical history, she has been taking bilastine (20 mg/day) for 1 year, methylprednisolone was prescribed to the patient due to angioedema which affected tongue and larynx for 30 days until 5 months ago, diclofenac was given for pain relief after hysterectomy, she had taken dexketoprofen (25 mg/every 3 day) for 3 months until 2 months ago and she was injected the fifth monthly dose of 150 mg omalizumab 15 days ago. Laboratory evaluation revealed increased serum creatinine level (1.64 mg/dL) with respect to basal levels (0.65 mg/dL) of 6 months earlier, decreased glomerular filtration rate (GFR) (estimated GFR using Chronic Kidney Disease Epidemiology Collaboration, CKD-EPI equation was 34 mL/min/1.73 m², creatinine clearance using 24-h urine collection was 37.4 mL/min), microalbuminuria (98 mg/d), increased proteinuria (1.3 g/d), and increased beta-2 microglobulinuria (21,300 $\mu\text{g/L}$, normal value <300 $\mu\text{g/L}$ ⁵). Her urinary beta-2 microglobulin: creatinine ratio was 76071 ($\mu\text{g/g}$) (normal <300 $\mu\text{g/g}$ ⁶). Biochemically her serum creatinine level was increased to 2.21 mg/dL within 8 days (Table 1). Presence of high amount of low molecular weight proteins (beta-2 microglobulin) in her urine analysis indicated tubular type consisting majority of proteinuria. Kidney biopsy showed acute interstitial nephritis accompanied with chronic interstitial injury related findings without

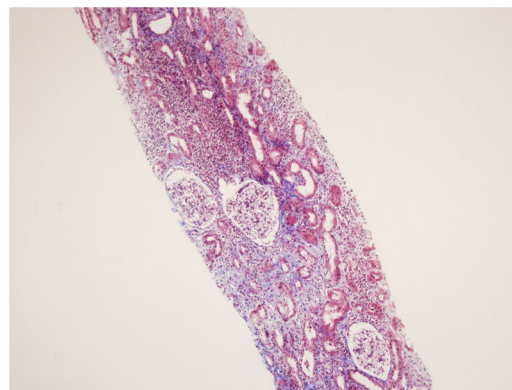


Fig. 1 – Severe interstitial lymphocytic (including eosinophilic lymphocytes, plasma cells and mostly mononuclear leukocytes) infiltration affected 60% of cortical area, and interstitial fibrosis with tubular atrophy involved 30% of the tissue, H.E. 100x.

immune deposition (Fig. 1). In addition, early stage of diabetic nephropathy was observed due to diffuse basal membrane thickening. Oral methylprednisolone was given to the patient at the dose of 1 mg/kg/d for treatment of AIN.⁷ Dose was slowly tapered to 5 mg/day after a month and prescribed for another 3 months. Her serum creatinine level was decreased from 2.24 mg/dL to 1.58 mg/dL in 10 days of treatment, and after 4 months her serum creatinine level was 0.82 mg/dL.

The cause of AIN in majority of the patients was known as hypersensitivity towards drugs (75% of the cases).⁸ Practically, every drug may have a potential for causing AIN, yet mostly reported drugs are antibiotics, NSAID, proton pump inhibitors and allupurinol.⁹ The time interval between drug intake and onset of AIN can vary from 1 week to 9 months (10–11 weeks being the commonest) among the patients.⁹ The most possible offending agent for AIN of the patient was thought as diclofenac since absence of any report regarding

the other medications that our patient had taken (methylprednisolone, dexketoprofen, gliclazide, metformin, bilastine, and omalizumab). It is known that NSAID induced AIN does not generally response to glucocorticoid therapy.⁷ Conflicting with this information, our patient responded well to corticosteroid treatment which made us suspect some other drug she used might have led to AIN other than NSAID. The association of CIU with AIN has not been reported yet. It might be possible but needs to be clarified that AIN of our patient may result from one of the hypersensitivity reaction and manifestation of CIU. However, her itching symptoms completely abolished by omalizumab and this AIN developed during omalizumab treatment of 5 months duration. Omalizumab has been shown to decrease serum eosinophil levels and effective in treatment of CIU through its functions against eosinophils.¹⁰ In theory, omalizumab might have been protective for development of AIN via these eosinophil depleting effects. However, even though 5 months of omalizumab treatment, our patient had AIN which was treated successfully with methylprednisolone.

In conclusion, AIN of our case most probably was secondary to diclofenac intake 5 months earlier even though presence of response to glucocorticoids. Whether presence of CIU increase the tendency of patients to development of AIN secondary to offending drugs has not been known yet. Renal functions especially tubular proteinuria should be evaluated and searched thoroughly in order to diagnose early and treat appropriately for AIN among individuals with CIU before and during prescription of any drug.

Authors' contributions

Kubra Kaynar: Conception, design, drafting the article.
 Nejla Küçük: Drafting the article.
 Sevdegül Mungan: Drafting the pathological data of the case.
 Beyhan Güvercin: Drafting the article.
 Şükrü Ulusoy: Drafting the article.

Conflicts of interest

None declared.

REFERENCES

1. Caravaca-Fontan F, Fernandez-Juarez G, Praga M. Acute kidney injury in interstitial nephritis. *Curr Opin Crit Care*. 2019;25:558–64, <http://dx.doi.org/10.1097/MCC.0000000000000654>.
2. Hon KL, Leung AKC, Ng WGG, Loo SK. Chronic urticaria: an overview of treatment and recent patents. *Recent Pat Inflamm Allergy Drug Discov*. 2019;13:27–37, <http://dx.doi.org/10.2174/1872213X13666190328164931>.

3. Schaefer P. Acute and chronic urticaria: evaluation and treatment. *Am Fam Physician*. 2017;95:717–24.
4. Tonacci A, Billeci L, Pioggia G, Navarra M, Gangemi S. Omalizumab for the treatment of chronic idiopathic urticaria: systematic review of the literature. *Pharmacotherapy*. 2017;37:464–80, <http://dx.doi.org/10.1002/phar.1915>.
5. Heidegger H, Hümfner A, Corradini R. Beta 2-microglobulinuria and lysozyme-uria. Their role as diagnostic and therapeutic indicators in dilatation of the upper urinary tract during pregnancy. *Minerva Ginecol*. 1990;42:243–50.
6. Otaki Y, Watanabe T, Shishido T, Takahashi H, Funayama A, Narumi T, et al. The impact of renal tubular damage, as assessed by urinary β 2-microglobulin-creatinine ratio, on cardiac prognosis in patients with chronic heart failure. *Circ Heart Fail*. 2013;6:662–8, <http://dx.doi.org/10.1161/CIRCHEARTFAILURE.112.000089>.
7. Kshirsagar AV, Falk RJ. Treatment of acute interstitial nephritis. 2020 May. UpToDate.com. Available at <https://www.uptodate.com/contents/treatment-of-acute-interstitial-nephritis?> [accessed 25.06.20].
8. Praga M, Appel GB. Clinical manifestations and diagnosis of acute interstitial nephritis. 2020 May. UpToDate.com. Available at <https://www.uptodate.com/contents/clinical-manifestations-and-diagnosis-of-acute-interstitial-nephritis?> [accessed 25.06.20].
9. Praga M, Sevillano A, Aunon P, Gonzalez E. Changes in the aetiology, clinical presentation and management of acute interstitial nephritis, an increasingly common cause of acute kidney injury. *Nephrol Dial Transplant*. 2015;30:1472–9, <http://dx.doi.org/10.1093/ndt/gfu326>.
10. Tamer F, Gulru Erdogan F, Dincer Rota D, Yildirim D, Akpınar Kara Y. Efficacy of omalizumab in patients with chronic spontaneous urticaria and its association with serum IgE levels and eosinophil count. *Acta Dermatovenerol Croat*. 2019;27:101–6.

Kubra Kaynar^{a,*}, Nejla Küçük^b, Sevdegül Mungan^c, Beyhan Güvercin^a, Şükrü Ulusoy^a

^a Department of Nephrology, Karadeniz Technical University, Faculty of Medicine, Trabzon, Turkey

^b Department of Internal Medicine, Karadeniz Technical University, Faculty of Medicine, Trabzon, Turkey

^c Department of Pathology, Karadeniz Technical University, Faculty of Medicine, Trabzon, Turkey

* Corresponding author.

E-mail address: kkaynar@yahoo.com (K. Kaynar).

0211-6995/© 2020 Sociedad Española de Nefrología. Published by Elsevier España, S.L.U. This is an open access article under the CC BY-NC-ND license (<http://creativecommons.org/licenses/by-nc-nd/4.0/>). <https://doi.org/10.1016/j.nefro.2020.08.009>