

6. Ficha Técnica de Praluent® (alirocuma). [Internet]. Disponible en [http://www.ema.europa.eu/docs/es\\_ES/document\\_library/EPAR\\_-Product\\_Information/human/003882/WC500194521.pdf](http://www.ema.europa.eu/docs/es_ES/document_library/EPAR_-Product_Information/human/003882/WC500194521.pdf).
7. Toth PP, Dwyer JP, Cannon CP, Colhoun HM, Rader DJ, Upadhyay A, et al. Efficacy and safety of lipid lowering by alirocumab in chronic kidney disease. *Kidney International*. 2018;93:1397–408, <http://dx.doi.org/10.1016/j.kint.2017.12.011>.
8. Mafham M, Haynes R. PCSK9 inhibition: ready for prime time in CKD? *Kidney Int*. 2018;93:1267–9, <http://dx.doi.org/10.1016/j.kint.2018.01.030>.
9. Del Vecchio L, Baragetti I, Locatelli F. New agents to reduce cholesterol levels: implications for nephrologists. *Nephrol Dial Transplant*. 2020;35:213–8 <https://doi.org/10.1093/ndt/gfz013>
10. Shrestha P, van de Sluis B, Dullaart RPF, van den Born J. Novel aspects of PCSK9 and lipoprotein receptors in renal disease-related dyslipidemia. *Cell Signal*. 2019;55(53) <https://doi.org/10.1016/j.cellsig.2018.12.001>
- Alba Rivas Oural\*, Elena Astudillo Cortés, Jose Joaquín Bande Fernández, María del Carmen Rodríguez Suárez, María del Carmen Díaz Corte
- Departamento de Nefrología, Hospital Universitario Central de Asturias, Oviedo, Asturias, Spain*
- \*Corresponding author.
- 6 November 2019  
<https://doi.org/10.1016/j.nefro.2020.04.006>
- 2013-2514/© 2020 Sociedad Española de Nefrología. Published by Elsevier España, S.L.U. This is an open access article under the CC BY-NC-ND license (<http://creativecommons.org/licenses/by-nc-nd/4.0/>).

## Letter to the Editor

# Intravesical cidofovir, use in BK polyomavirus-associated haemorrhagic cystitis after haematopoietic stem cell transplantation: off-label<sup>☆</sup>

## Cidofovir intravesical, uso en cistitis hemorrágica por poliomavirus bk tras un trasplante de progenitores hematopoyéticos: off-label

### ARTICLE INFO

#### Article history:

Dear Editor,

Haemorrhagic cystitis is defined as inflammation of the bladder mucosa that causes acute or subacute diffuse bleeding.<sup>1</sup> It is caused by the inappropriate activation of proinflammatory cytokines, which destroy the mucosa and chorion through inflammatory apoptosis (pyroptosis), which leads to the opening of the microvessels to the bladder lumen. The main causes of bladder pyroptosis are bacterial or viral pathogens, ionising radiation or acrolein, a urinary metabolite of cyclophosphamide and ifosfamide.<sup>2</sup>

The BK virus is one of the most important causes of late-onset haemorrhagic cystitis in patients undergoing haematopoietic cell transplantation (HCT). The evidence for the treatment of BK virus-associated haemorrhagic cystitis

(BKV–HC) is limited, with cidofovir being one of the treatment options.<sup>3</sup> Cidofovir is a cytidine analogue that demonstrates in vitro and in vivo activity against human cytomegalovirus (HCMV) because it suppresses replication by selective inhibition of viral DNA synthesis.<sup>4</sup> The use of this drug in BKV–HC would be off-label.

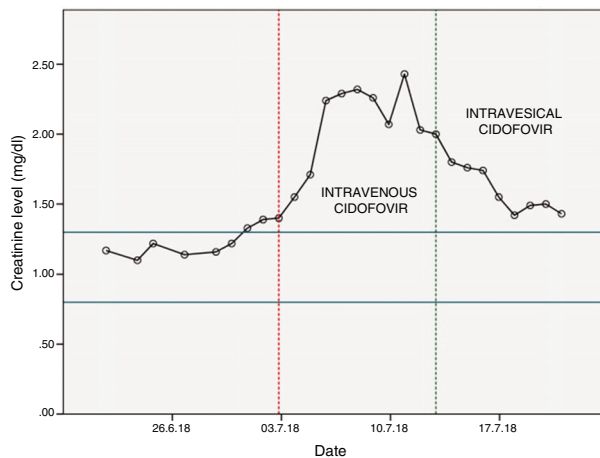
This is the case of a 53-year-old man with no known drug allergies and with a personal history of dyslipidaemia and arterial hypertension.

The patient was diagnosed in 2016 with chronic myelomonocytic leukaemia (CML) and, after several cycles of chemotherapy (MAZE: amsacrine-azacitidine-etoposide; IDA-ARA-C: idarubicin-cytarabine), he underwent allogeneic haematopoietic stem cell transplantation (Allo-HSCT) in May 2018.

DOI of original article:

<https://doi.org/10.1016/j.nefro.2020.02.005>.

<sup>☆</sup> Please cite this article as: Ferrer A, Viña MM, Limiñana EP, Merino J. Cidofovir intravesical, uso en cistitis hemorrágica por poliomavirus BK tras un trasplante de progenitores hematopoyéticos: off-label. *Nefrologia*. 2021;41:79–80.



**Figure 1 – Evolution of creatinine levels during hospital stay.**

Two months later, the patient went to the haematology day unit (HDU) to receive treatment with foscarnet against cytomegalovirus (CMV), acquired after Allo-HSCT, having reported haematuria accompanied by dysuria and burning over the previous few days. With these symptoms, the patient was admitted and diagnosed with haemorrhagic cystitis.

After several tests to discover the aetiology of the disease, copies of BK polyomavirus were detected in his urine. In light of these findings and after communication with the regional referral centre, it was proposed the use of intravenous cidofovir at a daily dose of 400 mg/24 h for 2 weeks (induction) and then every 15 days until virus eradication.

Renal function was assessed before starting treatment with cidofovir (>60 ml/min) and the treatment start date was set: 03/07/2018. To decrease renal toxicity, probenecid was co-administered with cidofovir.

After the first dose of cidofovir, it was observed a significant increase in blood creatinine levels (Fig. 1), so the haematology unit contacted the pharmacy to find a solution to the problem.

As previously mentioned, the main toxicity associated with cidofovir is dose-dependent nephrotoxicity. The Spanish Agency of Medication and Health products (Agencia Española de Medicamentos y Productos Sanitarios — AEMPS) reports that the safety of cidofovir has not been evaluated in patients receiving other agents that are known to be potentially nephrotoxic (for example: tenofovir, aminoglycosides, amphotericin B, foscarnet, intravenous pentamidine, adefovir and vancomycin).<sup>4</sup> In our case, the nephrotoxicity by cidofovir was exacerbated by the concomitant use of foscarnet, which could not be discontinued since the patient maintained positive CMV copies in plasma.

In light of the above, from the pharmacy department we conducted a literature search and found a systematic review that compared intravenous and intravesical administration of cidofovir in the treatment of BK polyomavirus-associated haemorrhagic cystitis after Allo-HSCT. It was found that the intravesical route gave a high rate of complete responses, but without renal toxicity.<sup>5</sup>

Based on these information, the use of intravesical cidofovir was recommended at 5 mg/kg diluted in 60 ml of 0.9% physiological saline solution and instilled for one hour into the bladder, with changes in posture (supine position, left lateral position, prone position and right lateral position) every 15 min so that the drug could penetrate the entire mucosa of the bladder (nursing recommendation).

The first dose of intravesical cidofovir was administered on 13/07/2018, after which an improvement in renal function was observed (Fig. 1). After the first instillation of intravesical cidofovir, the urine PCR was repeated to detect copies of BK polyomavirus. The result was negative, so treatment with cidofovir was discontinued.

Our case shows that the use of intravesical cidofovir can be proposed as an effective alternative in patients with creatinine clearance  $\leq 55$  ml/min (the limit for contraindication of intravenous cidofovir).

## REFERENCES

- García Criado J, Corbacho Cambero I, Sánchez Moro V, Muñoz Galindo A, Sánchez Serrano JA. *Manual terapéutico*. 4ª ed. Corregida y ampliada. Salamanca: Ediciones Universidad de Salamanca; 2019.
- Colombel M, Wallet HL. *Cistitis hemorrágica: fisiopatología y conducta práctica*. EMC - Urología. 2019;51:1–10.
- Aldiwani M, Tharakan T, Al-Hassani A, Gibbons N, Pavlu J, Hrouda D. BK virus associated haemorrhagic cystitis. A systematic review of current prevention and treatment strategies. *Int J Surg*. 2019;63:34–42, <http://dx.doi.org/10.1016/j.ijsu.2019.01.019>.
- Ficha Técnica de Cidofovir. The European Agency for the Evaluation of Medicinal Products (EMA). Available from: <http://www.eudra.org/emea.html>.
- Schneidewind L, Neumann T, Schmidt CA, Krüger W. Comparison of intravenous or intravesical cidofovir in the treatment of BK polyomavirus-associated hemorrhagic cystitis following adult allogeneic stem cell transplantation—a systematic review. *Transpl Infect Dis*. 2018;20:e12914.

Alejandro Ferrer<sup>a,\*</sup>, María Micaela Viña<sup>a</sup>,  
Elisa Pérez Limiñana<sup>b</sup>, Javier Merino<sup>a</sup>

<sup>a</sup> Servicio de Farmacia Hospitalaria, Hospital Universitario Nuestra Señora de Candelaria, Santa Cruz de Tenerife, Spain

<sup>b</sup> Servicio de Enfermería, Hospital Universitario Nuestra Señora de Candelaria, Santa Cruz de Tenerife, Spain

\* Corresponding author.

E-mail address: [Alefermac1989@gmail.com](mailto:Alefermac1989@gmail.com) (A. Ferrer).  
<https://doi.org/10.1016/j.nefro.2020.02.006>

2013-2514/© 2020 Sociedad Española de Nefrología. Published by Elsevier España, S.L.U. This is an open access article under the CC BY-NC-ND license (<http://creativecommons.org/licenses/by-nc-nd/4.0/>).