

4. Chirumbolo S, Vella A, Ortolani R, De Gironcoli M, Solero P, Tridente G, et al. Differential response of human basophil activation markers: a multi-parameter flow cytometry approach. *Clin Mol Allergy*. 2008;6:12.
5. Chirumbolo S. Basophil activation test in allergy: time for an update? *Int Arch Allergy Immunol*. 2012;158:99–114.
6. Chirumbolo S, Brizzi M, Ortolani R, Vella A, Bellavite P. Inhibition of CD203c membrane up-regulation in human basophils by high dilutions of histamine: a controlled replication study. *Inflamm Res*. 2009;58:755–64.
7. Mommert S, Kleiner S, Gehring M, Eiz-Vesper B, Stark H, Gutzmer R, et al. Human basophil chemotaxis and activation are regulated via the histamine H4 receptor. *Allergy*. 2016;71:1264–73.
8. Tedeschi A, Lorini M, Arquati M, Miadonna A. Regulation of histamine release from human basophil leucocytes: role of H1, H2 and H3 receptors. *Allergy*. 1991;46:626–31.
9. Chirumbolo S, Bjorklund G, Vella A. Using a CD45dim/CD123bright/HLA-DRneg phenotyping protocol to gate basophils in FC for airway allergy. CD123 does not decrease. *Adv Respir Med*. 2017;85:193–201.
10. Santos AF, Bécares N, Stephens A, Turcanu V, Lack G. The expression of CD123 can decrease with basophil activation: implications for the gating strategy of the basophil activation test. *Clin Transl Allergy*. 2016;6:11.
11. Chirumbolo S. Major pitfalls in BAT performance may be caused by gating protocols and CD63% cut off evaluation. *Cytometry A*. 2014;85:382–5.
12. Moharana AK, Bhattacharya SK, Mediratta PK, Sharma KK. Possible role of histamine receptors in the central regulation of immune responses. *Indian J. Physiol Pharmacol*. 2000;44:153–60.
13. Jutel M, Blaser K, Akdis CA. The role of histamine in regulation of immune responses. *Chem Immunol Allergy*. 2006;91:174–87.

Salvatore Chirumbolo<sup>a,\*</sup>, Geir Bjørklund<sup>b</sup>, Antonio Vella<sup>c</sup>

<sup>a</sup> Department of Neurosciences, Biomedicine and Movement Sciences, University of Verona, Verona, Italy

<sup>b</sup> Council for Nutritional and Environmental Medicine (CONEM), Mo i Rana, Norway

<sup>c</sup> Unit of Immunology and Cytofluorimetry-AOUI, Policlinico GB Rossi piazzale AL Scuro 10, 37134 Verona, Italy

\*Corresponding author.

E-mail address: [salvatore.chirumbolo@univr.it](mailto:salvatore.chirumbolo@univr.it) (S. Chirumbolo).

<https://doi.org/10.1016/j.nefro.2019.06.005>

0211-6995/© 2019 Sociedad Española de Nefrología. Published by Elsevier España, S.L.U. This is an open access article under the CC BY-NC-ND license (<http://creativecommons.org/licenses/by-nc-nd/4.0/>).

## Necrotising glomerulonephritis in a patient with HIV, HCV and visceral leishmaniasis<sup>☆</sup>

### Glomerulonefritis necrosante en un paciente con VIH, VHC y leishmaniasis visceral

Dear Editor,

Concomitant human immunodeficiency virus (HIV) infection and visceral leishmaniasis is frequent and follows a torpid and recurrent course. Kidney involvement includes glomerulonephritis and tubular impairment. We report an uncommon case.

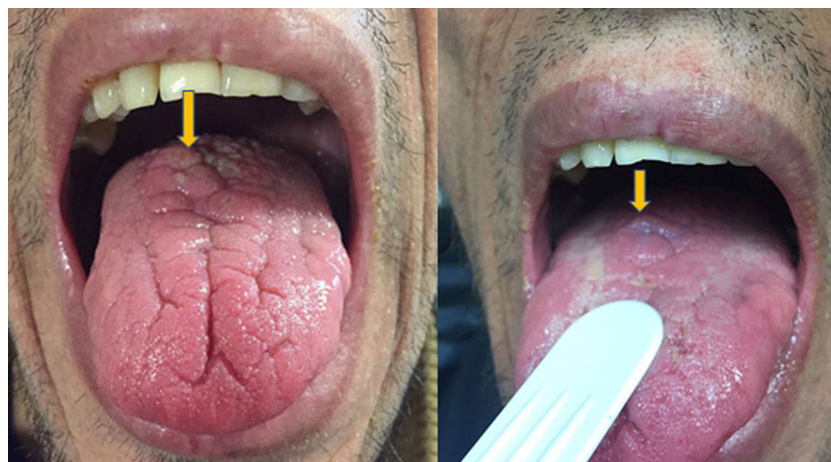A 46-year-old man addicted to alcohol and parenteral drugs was diagnosed in 2006 with stage C HIV infection and hepatitis C virus (HCV) genotype 4. He started highly active antiretroviral therapy (HAART) in 2011, following his first episode of decompensated ascites due to cirrhosis with a Child-Pugh score of C, with portal hypertension, splenomegaly and pancytopenia. He voluntarily suspended HAART in May 2015 and restarted it in November 2016 (raltegravir, abacavir and lamivudine). A month later, with an undetectable viral

load and no immune restoration (CD4+T cells 74/mm<sup>3</sup>), he developed non-oliguric acute kidney failure (peak creatinine 5.7 mg/dl), mixed proteinuria of 2 g/day, microhaematuria and swelling on the back of the tongue (Fig. 1). A biopsy demonstrated severe epithelial dysplasia and mucosal candidiasis. Complementary tests revealed decreased C3, polyclonal gammopathy, increased immunoglobulins and kappa and lambda chains, and positive antinuclear antibodies (ANAs) (1/640). Cryoglobulins, a Mantoux test and serology (hepatitis B virus [HBV], syphilis, *Toxoplasma*) were negative. Cytomegalovirus (CMV) and *Leishmania* IgG and rK39 antigen in blood were tested and found to be positive. PCR for *Leishmania* in the tongue and bone marrow were negative. A kidney biopsy was performed in which six glomeruli were identified, one with

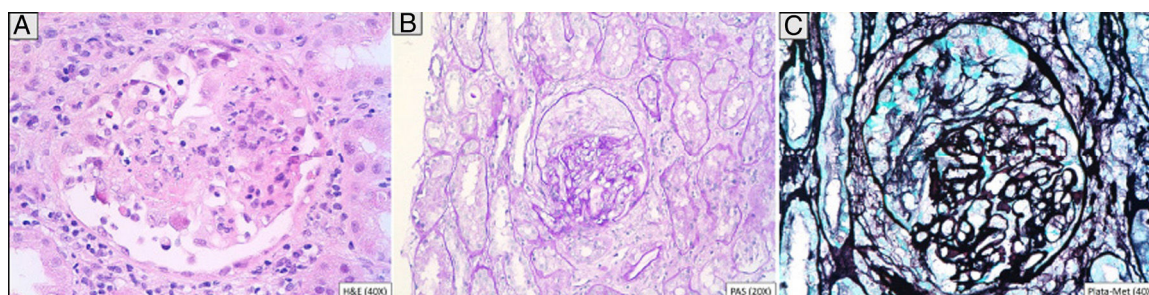
DOI of original article:

<https://doi.org/10.1016/j.nefro.2019.05.003>.

<sup>☆</sup> Please cite this article as: Puerta Carretero M, Ortega Díaz M, Corchete Prats E, Roldán Cortés D, Cuevas Tascón G, Martín Navarro JA, et al. et al. Glomerulonefritis necrosante en un paciente con VIH, VHC y leishmaniasis visceral. *Nefrología*. 2020;40:481–484.



**Fig. 1 – Lesion on the back of the tongue.**



**Fig. 2 – Kidney biopsy. A) Haematoxylin–eosin staining: segmental necrotising lesion with fibrin and remnants of fragmented nuclei. B) Periodic acid–Schiff (PAS) staining: epithelial half-moon. C) Silver staining: epithelial half-moon.**

foci of segmental necrosis with fibrin and two with crescents without thrombi (Fig. 2). Moderate chronic inflammation and fibrosis were seen in the interstitial space, with no tubular abnormalities. There were no signs of vasculitis. Direct immunofluorescence (DIF) was positive with a mesangial predominance for C3 (++) , IgG (+) , C1q and IgM (+) , and negative for IgA and light chains. Amyloid was not identified with Congo red staining. Electron microscopy (EM) was not available. The patient started treatment with liposomal amphotericin B; three weeks later, his kidney function normalised and his urinary abnormalities improved. Two months later he started treatment for HCV with a sustained virologic response. After 16 months of follow-up in which prophylaxis with amphotericin was maintained, his glomerular filtration rate (GFR) was normal and minimal microhaematuria and albuminuria persisted. The patient's tongue swelling and acute kidney failure were interpreted as secondary to acute leishmaniasis.

Leishmaniasis is caused by the *Leishmania infantum/chagasi* protozoon in the Mediterranean, Asia and South America, and by *Leishmania donovani* in India and eastern Africa. Encompassed by the cells of the reticuloendothelial system, its multiplication induces severe polyclonal hypergammaglobulinaemia and pancytopenia. Subsequently, it enters the peripheral blood and may trigger a cutaneous, mucocutaneous, visceral or postvisceral dermatological condition.

There are 1-2 million patients in the world, 500,000 new cases and 50,000 deaths per year.<sup>1-3</sup> It primarily affects immunosuppressed, HIV-infected and transplant patients. In Spain, its incidence is 0.25/10<sup>5</sup> patients per year. From 1986 to 1994, 858 cases of concomitant infection were reported to the World Health Organization (WHO) Division for Control of Tropical Diseases in France, Italy, Portugal, Greece and Spain. Between 1.6% and 4.9% of cases of HIV will involve concomitant infection with *Leishmania* in southern Europe due to reinfection or reactivation.<sup>4</sup> In HIV-infected patients, visceral leishmaniasis occurs in 60% of cases following treatment, since accumulation of the protozoon in atypical organs such as the kidneys affects the response of macrophages and dendritic cells and induces cytokine deregulation, an increase in IL-10, activation of CD8+ (cytotoxic) T cells, abnormal apoptosis, production of autoantibodies and immune complexes and incomplete responses to treatment, with frequent recurrences and chronic inflammatory reaction.<sup>5-7</sup> In addition, it leads to CD4+ T cell depletion which worsens the course of the patient's HIV infection. Most concomitant infections occur when CD4+ T cell levels are below 200/ $\mu$ l. Diagnostic criteria include identification of the parasite in bone marrow and positivity of the rK39 antigen in blood during active infection, with specificity and sensitivity close to 100%.<sup>1</sup> It is common to find complement consumption; positivity for rheumatoid fac-

**Table 1 – Cases published in the literature of concomitant visceral leishmaniasis and HIV infection with kidney damage.**

Author	Sex/age	HCV/Cryoglobs	CD4+	VL HIV	Start	HIV diagnosis	Renal clinical course	Kidney biopsy
Clevenbergh et al. (2002) <sup>11</sup>	M/45	+/+	60	<200	NOAKF	7 months	FR	Mesangial HT
Rollino et al. (2003) <sup>12</sup>	F/28	-/-	NS	NS	Subnephrotic PRTu HMTu OAKF, PRTu, HMTu	NS	D	FSGS Collapsing FSGS with HMs, ATN, toxic tubulitis, leukocytoclastic vasculitis
Navarro et al. (2006) <sup>13</sup>	M/28	+/-	62	<80	OAKF, nephrotic PRTu	NS	ESRD in HD	AA amyloidosis
Alexandru et al. (2008) <sup>5</sup>	F/42	+/+	344	ND	NoS with intact GFR	5 years	PR with frequent recurrences until D	Mesangial GN with negative immunofluorescence (IF)
Amann et al. (2012) <sup>14</sup>	M/45	-/-	174	790	NOAKF, NiS, NoS	23 years	CKD with NoS	Type 1 MPGN
De Vallière et al. (2009) <sup>15</sup>	M/32	+/+	160-170	ND	NoS, AKF	Simultaneous	PR CKD with NoS and PR	Mesangial hyperplasia
Rybniker et al. (2010) <sup>7</sup>	M/49	-/-	180	ND	AKF	16 years	ESRD in HD	Extracapillary GN
Suankratay et al. (2010) <sup>16</sup>	M/37	+/-	129	ND	NoS, AKF	4 years	FR	MPGN and FSGS
Vassallo et al. (2014) <sup>17</sup>	M/40	-/+	114	162	NiS	15 years	PR	Type 3 MPGN
Ortiz et al. (2015) <sup>3</sup>	M/35	-/¿	12	411,000	NoS	11 years	D	Type 3 MPGN
	F/24	-/+	70	0.2	AKF	24 years	PR D	AIAN
	M/49	+/+	84	<40	NoS	2 years		Type 3 MPGN
	M/46	-/+	786	ND	NoS, AKF and macroHMTu	3 years	FR	Type 3 MPGN and Cryoglobs with AIAN
Enríquez et al. (2015) <sup>18</sup>	M/47	-/-	93	ND	NoS	3 years	CKD with nephrotic PRTu	MPGN
Puerta et al. (2018)	M/46	+/-	78	ND	NOAKF, nephrotic PRTu MicroHMTu	10 years	FR	Necrotising GN with HMs

AIAN: acute immunoallergic nephritis; AKF: acute kidney failure; ATN: acute tubular necrosis; CKD: chronic kidney disease; Cryoglobs: cryoglobulins; D: death; ESRD: end-stage renal disease; F: female; FSGS: focal segmental glomerulosclerosis; FR: full recovery; GN: glomerulonephritis; HD: haemodialysis; HIV: human immunodeficiency virus; HMs: half-moons; HMTu: haematuria; HT: hypertrophy; M: male; MPGN: membranoproliferative glomerulonephritis; ND: not detectable; NiS: nephritic syndrome; NOAKF: non-oliguric acute kidney failure; NoS: nephrotic syndrome; NS: not specified; OAKF: oliguric acute kidney failure; PR: partial recovery; PRTu: proteinuria; VL: viral load.

tor; cryoglobulins<sup>3</sup>; and antiplatelet, anti-smooth muscle and anti-glomerular basement membrane (GBM) antibodies. In the kidneys,<sup>8</sup> the damage is due to immune complex deposition, with activation of cytotoxic T cells and adhesion molecules.<sup>2</sup> Initially the mesangium is affected with focal hypercellularity and granular deposits of IgG, IgM, C3 in the matrix, GBM (subendothelial, intramembranous and subepithelial) and interstitial space. If the immune complexes breach this barrier, they may become deposited in the glomerulus, thereby inducing epithelial and endothelial proliferation (MPGN). It is

characteristic to find peritubular intramacrophage protozoa,<sup>5</sup> interstitial damage<sup>9</sup> which manifests with distal renal tubular acidosis (RTA).<sup>1,2,10</sup> hyponatraemia, hypomagnesaemia, hypocalcaemia, hypokalaemia and hypouricaemia. **Table 1** summarises the cases collected from the literature of concomitant infection with visceral leishmaniasis and HIV infection with kidney damage. In our case, the patient started with nephrotic syndrome and acute kidney failure with haematuria. The biopsy resulted in a diagnosis of necrotising glomerulonephritis. The fact that cryoglobulins were nega-

tive rendered the conclusion that it was not likely related to HCV infection. It is uncommon to identify the parasite in neither the bone marrow nor the kidney tissue, but the patient's positivity for the rK39 antigen and resolution of signs and symptoms after starting the treatment confirmed the diagnosis.

## REFERENCES

- Oliveira MJ, Silva Júnior GB, Abreu KL, Rocha NA, Garcia AV, Franco LF, et al. Risk factors for acute kidney injury in visceral leishmaniasis (Kala-Azar). *Am J Trop Med Hyg.* 2010;82:449-53.
- Libório AB, Rocha NA, Oliveira MJ, Franco LF, Aguiar GB, Pimentel RS, et al. Acute kidney injury in children with visceral leishmaniasis. *Pediatr Infect Dis J.* 2012;31:451-4.
- Ortiz M, Mon C, Herrero JC, Olié A, Rodríguez I, Ortega O, et al. Glomerulonephritis and cryoglobulinemia: first manifestation of visceral leishmaniasis. *Clin Nephrol.* 2015;83:370-7.
- Alexandru S, Criado C, Fernández-Guerrero ML, de Górgolas M, Petkov V, Garcia Perez A, et al. Nephrotic syndrome complicating chronic visceral leishmaniasis: re-emergence in patients with AIDS. *Clin Nephrol.* 2008;70:65-8.
- Laguna F, Adrados M, Alvar J, Soriano V, Valencia ME, Moreno V, et al. Visceral leishmaniasis in patients infected with the human immunodeficiency virus. *Eur J Clin Microbiol Infect Dis.* 1997;16:898-903.
- Rybníček J, Goede V, Mertens J, Ortmann M, Kulas W, Kochanek M, et al. Treatment of visceral leishmaniasis with intravenous pentamidine and oral fluconazole in an HIV-positive patient with chronic renal failure – a case report and brief review of the literature. *Int J Infect Dis.* 2010;14:e522-25.
- Duvic C, Nedelec G, Debord T, Herody M, Didelot F. Important parasitic nephropathies: update from the recent literature. *Nephrologie.* 1999;20:65-74.
- Caravaca F, Muñoz A, Pizarro JL, Saez de Santamaría J, Fernandez-Alonso J. Acute renal failure in visceral leishmaniasis. *Am J Nephrol.* 1991;11:350-2.
- Dutra M, Martinelli R, de Carvalho EM, Rodrigues LE, Brito E, Rocha H. Renal involvement in visceral leishmaniasis. *Am J Kidney Dis.* 1985;6:22-7.
- Clevenbergh P, Okome MN, Benoit S, Bendini JC, de Salvador F, Elbeze M, et al. Acute renal failure as initial presentation of visceral leishmaniasis in an HIV-1-infected patient. *Scand J Infect Dis.* 2002;34:546-7.
- Rollino C, Bellis D, Beltrame G, Basolo B, Montemagno A, Bucolo S, et al. Acute renal failure in leishmaniasis. *Nephrol Dial Transplant.* 2003;18:1950-1.
- Navarro M, Bonet J, Bonal J, Romero R. Secondary amyloidosis with irreversible acute renal failure caused by visceral leishmaniasis in a patient with AIDS. *Nefrologia.* 2006;26:745-6.
- Amann K, Bogdan C, Harrer T, Rech J. Renal leishmaniasis as unusual cause of nephrotic syndrome in an HIV patient. *J Am Soc Nephrol.* 2012;23:586-90.
- De Vallière S, Mary C, Joneberg JE, Rotman S, Bullani R, Greub G, et al. AA-amyloidosis caused by visceral leishmaniasis in a human immunodeficiency virus-infected patient. *Am J Trop Med Hyg.* 2009;81:209-12.
- Suankratay C, Suwanpimolkul G, Wilde H, Siriyasatien P. Autochthonous visceral leishmaniasis in a human immunodeficiency virus (HIV)-infected patient: the first in Thailand and review of the literature. *Am J Trop Med Hyg.* 2010;82:4-8.
- Vassallo M, Moranne O, Ambrosetti D, Jeandel PY, Pomares C, Cassuto E, et al. Visceral leishmaniasis due to *Leishmania infantum* with renal involvement in HIV-infected patients. *BMC Infect Dis.* 2014;14:561.
- Enríquez R, Sirvent AE, Padilla S, Toro P, Sánchez M, Millán I. Membranoproliferative glomerulonephritis due to visceral leishmaniasis in a HIV patient. *Am J Case Rep.* 2015;16:8-11.
- Nylén S, Sacks D. Interleukin-10 and the pathogenesis of human visceral leishmaniasis. *Trends Immunol.* 2007;28:378-84.

Marta Puerta Carretero<sup>a</sup>, Mayra Ortega Díaz<sup>a</sup>, Elena Corchete Prats<sup>a</sup>, David Roldán Cortés<sup>b</sup>, Guillermo Cuevas Tascón<sup>c</sup>, Juan A. Martín Navarro<sup>a,\*</sup>, María Teresa Jaldo Rodríguez<sup>a</sup>, Laura Medina Zahonero<sup>a</sup>, Melissa Cintra Cabrera<sup>a</sup>, Pablo Ryan Murúa<sup>b</sup>, Marta Albalade Ramón<sup>a</sup>, Patricia de Sequera Ortiz<sup>a</sup>, Roberto Alcázar Arroyo<sup>a</sup>

<sup>a</sup> Servicio de Nefrología, Hospital Universitario Infanta Leonor, Madrid, Spain

<sup>b</sup> Servicio de Anatomía Patológica, Hospital Universitario Infanta Leonor, Madrid, Spain

<sup>c</sup> Servicio de Medicina Interna, Hospital Universitario Infanta Leonor, Madrid, Spain

\* Corresponding author.

E-mail address: [juanmartinnav@hotmail.com](mailto:juanmartinnav@hotmail.com) (J.A. Martín Navarro).

2013-2514/© 2019 Sociedad Española de Nefrología. Published by Elsevier España, S.L.U. This is an open access article under the CC BY-NC-ND license (<http://creativecommons.org/licenses/by-nc-nd/4.0/>).

<https://doi.org/10.1016/j.nefro.2020.09.005>