

Letters to the Editor

Sustained severe intestinal edema after nafamostat mesilate-associated anaphylactic reaction during hemodialysis

Edema intestinal grave y prolongado después de reacción anafiláctica relacionada con nafamostat mesilato durante la hemodiálisis

Dear Editor,

Anticoagulant use is essential to safe hemodialysis (HD) therapy because it prevents thrombosis in the extracorporeal circuit. For HD therapy in Japan, nafamostat mesilate (NM) is usually used during HD in patients with a tendency to bleed because of its short half-life.¹ However, NM use is reportedly associated with adverse effects, including hyperkalemia,^{2,3} agranulocytosis,⁴ and anaphylactic reaction.^{5,6} A recent report indicated the development of anaphylactic shock in HD patients who received NM.⁶ Here, we report a case of NM-associated anaphylactic reaction in a patient on HD, followed by severe intestinal edema.

A 64-year-old man with diabetes mellitus and a 5-year history of HD was admitted to our hospital for body-fluid status evaluation because of a recent episode of intradialytic hypotension at his dialysis facility. The intradialytic hypotension was suspected to be associated with ultrafiltration-induced hypovolemia during HD before admission. NM was used several times instead of heparin sodium for retinal bleeding complicated by diabetes mellitus in his dialysis facility. At our dialysis center, HD was performed in the same manner using NM. We carefully monitored for the occurrence of ultrafiltration-induced intradialytic hypotension. His blood pressure (BP) was 195/90 mmHg before HD but rapidly decreased to 114/56 mmHg. The arterial oxygen saturation measured by pulse oximetry (SpO₂) was 88% with dyspnea and deterioration of consciousness shortly after the HD initiation. Based on the clinical course from before admission to this episode, intradialytic hypotension with NM-associated anaphylactic reaction was diagnosed. At a later date, specific immunoglobulin E (IgE) antibodies to NM were detected in his blood. The HD therapy was discontinued to avoid

further worsening of his systemic circulation. Although his BP recovered and his symptoms disappeared after HD was discontinued, he suffered from mild abdominal tenderness after the anaphylactic reaction; therefore, contrast computed tomography of the abdomen and pelvis was performed, which revealed remarkable mucosal edema at a circumference of the sigmoid colon (Fig. 1a) and along the entire intestine on a coronal view (Fig. 1b). During the next HD session using low-molecular-weight heparin, the intradialytic hypotension completely disappeared; thereafter, HD was safely performed. However, because the intestinal edema persisted on lower gastrointestinal endoscopy 2 weeks after the reaction, total parenteral nutrition instead of solid and liquid foods was necessary for approximately 3 weeks. Thereafter, he ate normally without worsening of the intestinal edema and fully recovered after 1 month of treatment.

An anaphylactic reaction usually occurs by an IgE-dependent immunologic mechanism and is commonly triggered by foods, stinging insect venom, and medications through acute onset within minutes to several hours. Furthermore, its reaction frequently increases vascular permeability, which increases the risk of death due to fluid extravasation with resultant sequential decreases in circulating blood volume, venous return, and BP.⁷ Interestingly, the increase in vascular permeability induced by the anaphylactic reaction differs among systemic organs, and the extent of vascular permeability changes vary considerably among tissues: vascular permeability increases markedly in the trachea, moderately in the mesentery and intestines, and slightly in the other organs.⁸ In this case, the whole-intestine edema associated with increased vascular permeability was surprisingly remarkable compared to other systemic organs in the NM-associated anaphylactic reaction, although the presence of

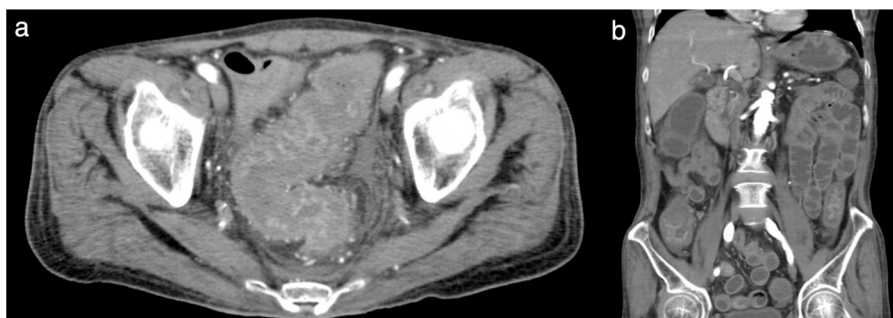


Fig. 1 – (a) Pelvic computed tomography scan at the level of the sigmoid colon. Remarkable mucosal edema was confirmed in the circumference of the sigmoid colon. (b) Abdominal and pelvic computed tomography scan (coronal view) showing severe whole-intestine edema.

tracheal edema might be suspected because of his respiratory distress and the SpO₂ decrease at the reaction's onset. In addition to the intestinal edema, it was interesting that improvement of the intestinal edema and dysfunction took several weeks. The reason for the difference between the rapid improvement of the circulating status and respiratory distress and the sustained gastrointestinal symptoms, including intestinal edema, in this case remains unclear. However, reports to date of the association between NM-associated anaphylactic reactions and remarkable intestinal edema are scarce. Therefore, this case report is relevant and showed that we should carefully monitor the systemic vascular permeability increase caused by the anaphylactic reaction, particularly in the intestine, in patients in whom NM is used during HD.

In Japan, the use of NM as an anticoagulant during blood purification is recommended in patients with various hemorrhagic complications as it has a lower risk of hemorrhage.¹ However, in patients with a history of NM-induced allergic reactions, low-molecular-weight heparin is usually administered instead of NM.⁵ In this case, HD was performed without worsening of the retinal bleeding after switching to low-molecular-weight heparin. Furthermore, rinsing the dialysis circuit with heparin and albumin⁹ and introducing a regional citrate infusion into the circuit¹⁰ have recently shown good survival of the extra corporeal circuit without increasing the bleeding risk. Therefore, HD may have been better performed using these methods to avoid the occurrence of the NM-associated anaphylactic reaction.

In conclusion, our experience described here suggests that patients administered NM during HD because of hemorrhagic complications should be carefully observed for anaphylactic reaction including BP reduction, respiratory distress, and intestinal edema via increased vascular permeability.

Conflicts of interest

The authors have no conflicts of interest to declare.

Acknowledgement

We thank our hospital's dialysis staff members.

REFERENCES

- Hirakata H, Nitta K, Inaba M, Shoji T, Fujii H, Kobayashi S, et al. Japanese Society for Dialysis therapy guidelines for management of cardiovascular diseases in patients on chronic hemodialysis. *Ther Apher Dial.* 2012;16:387–435.
- Muto S, Imai M, Asano Y. Mechanisms of hyperkalemia caused by nafamostat mesilate. *Gen Pharmacol.* 1995;26:1627–32.
- Ookawara S, Tabei K, Sakurai T, Sakairi Y, Furuya H, Asano Y. Additional mechanisms of nafamostat mesilate-associated hyperkalemia. *Eur J Clin Pharmacol.* 1995;51:149–51.
- Okada H, Suzuki H, Deguchi N, Saruta T, et al. Agranulocytosis in a haemodialysed patient induced by a proteinase inhibitor, nafamostat mesilate. *Nephrol Dial Transplant.* 1992;7:980.
- Higuchi N, Yamazaki H, Kikuchi H, Gejyo F. Anaphylactoid reaction induced by a proteinase inhibitor, nafamostat mesilate, following nine administrations in a hemodialysis patient. *Nephron.* 2000;86:400–1.
- Kim HS, Lee KE, Oh JH, Jung CS, Choi D, Kim Y, et al. Cardiac arrest caused by nafamostat mesilate. *Kidney Res Clin Pract.* 2016;35:187–9.
- Alvarez-Perea A, Tanno LK, Baeza ML. How to manage anaphylaxis in primary care. *Clin Trans Allergy.* 2017;7:45.
- Yang W, Shibamoto T, Kuda Y, Zhang T, Tanida M, Kurata Y. β_2 -Adrenoceptor blockade deteriorates systemic anaphylaxis by enhancing hyperpermeability in anesthetized mice. *Allergy Asthma Immunol Res.* 2018;10:52–61.
- Kyrk T, Bechara A, Skagerlind M, Stegmayr B. Heparin and albumin as part of the priming solution limits exposure to anticoagulation during hemodialysis: in vitro studies. *Int J Artif Organs.* 2014;37:734–40.
- Singer RF, Williams O, Mercado C, Chen B, Talaulikar G, Walters G, et al. Regional citrate anticoagulation in hemodialysis: an observational study of safety, efficacy, and effect on calcium balance during routine care. *Can J Kidney Health Dis.* 2016;3:22.

Mitsutoshi Shindo, Susumu Ookawara*, Taisuke Kitano, Hiroki Ishii, Haruhisa Miyazawa, Kiyonori Ito, Yuichiro Ueda, Keiji Hirai, Taro Hoshino, Yoshiyuki Morishita

Division of Nephrology, First Department of Integrated Medicine, Saitama Medical Center, Jichi Medical University, Saitama, Japan

* Corresponding author.

E-mail address: su-ooka@hb.tp1.jp (S. Ookawara).

2013-2514/© 2018 Sociedad Española de Nefrología. Published by Elsevier España, S.L.U. This is an open access article under the CC BY-NC-ND license (<http://creativecommons.org/licenses/by-nc-nd/4.0/>).

<https://doi.org/10.1016/j.nefro.2019.02.005>

Frailty prevalence and associated factors in hemodialysis patients[☆]

Prevalencia de fragilidad y factores asociados en pacientes en programa de hemodiálisis

Dear Editor,

Frailty has been defined as a syndrome or state of deterioration and increased vulnerability to situations of stress which occurs with ageing. It is characterised by weakness and diminishing of functional biological reserves, which leads to an increased risk of further deterioration towards disability, hospitalisation and death.^{1,2} Frailty is not the same as disability and comorbidity; although the three concepts are closely related and affect each other, they do not always coexist.³

Although frailty has been defined as generally associated with advanced age and ageing, there are conditions and diseases that cause changes similar to ageing which can lead to a state of frailty at younger ages, and one of these situations is chronic kidney disease.⁴⁻⁶ The prevalence of frailty in patients on haemodialysis has been estimated by different studies at 26–73%.^{7,8} The huge variability can be explained by differences in the populations studied and the different tools used to assess frailty.^{9,10} In Spain, no studies have been published to date on the prevalence of frailty in patients on haemodialysis.

Our aim was to estimate the prevalence of frailty in patients on haemodialysis in the southern health area of Gran Canaria and to study some of the associated demographic, clinical and analytical factors. We designed a cross-sectional study of 277 patients on haemodialysis, estimating frailty using the Fried Frailty Phenotype Index (FFPI) and the Edmonton Frail Scale (EFS). The FFPI is a standardised five-item scale that measures weakness, slow gait speed, exhaustion, low physical activity

and weight loss. The EFS contains 11 items that also measure other spheres of frailty, such as cognitive, psychological and social factors. We collected demographic and clinical data, the Charlson comorbidity index and analytical parameters. Patients were then followed up for a year to assess mortality rates according to frailty.

The prevalence of frail patients with the FFPI was 41.2% and, with the EFS, 29.6%. **Fig. 1** shows graphs of the prevalences found with both tests. We found a lack of consistency between the scales; of patients frail with EFS, 83% were frail with FFPI and 17% pre-frail, and of patients frail with FFPI, 60% were frail with EFS and 40% vulnerable or non-frail. The EFS classified a larger number of patients as non-frail, while the FFPI classified a larger number as pre-frail. It is difficult in a cross-sectional study to determine the reason and the prognostic implications of this lack of consistency, but it could be a result of the different spheres of frailty measured by each of the tests.

Table 1 shows the main demographic, clinical and analytical characteristics according to the results of the two tests. We can see that there is an association between frailty and other clinical data suggesting poor prognosis, such as advanced age, diabetes mellitus, a higher Charlson comorbidity index and being female. Among the analytical parameters, a slight but statistically significant decrease in haemoglobin, albumin and uric acid was found in the pre-frail and frail groups with respect to the non-frail. We found no differences between groups in the parameters of bone-mineral metabolism or lipid profile. There was a significant decrease in CPK with frailty, which may reflect a decrease in muscle mass due to

DOI of original article:
<https://doi.org/10.1016/j.nefro.2018.07.012>

* Please cite this article as: García-Cantón C, Ródenas Gálvez A, Lopez Aperador C, Rivero Y, Diaz N, Antón G, et al. Prevalencia de fragilidad y factores asociados en pacientes en programa de hemodiálisis. *Nefrología*. 2019;39:204–206.