

of severe hepatotoxicity associated with eculizumab. Hepatic enzyme levels should be controlled in patients receiving eculizumab. Further reports including large data are required to evaluate hepatotoxicity risk of this novel agent.

### Conflict of interest

The authors declare that they have no conflict of interest.

### REFERENCES

- Hayes W, Tschumi S, Ling SC, Feber J, Kirschfink M, Licht C. Eculizumab hepatotoxicity in pediatric aHUS. *Pediatr Nephrol.* 2015;30:775–81, <http://dx.doi.org/10.1007/s00467-014-2990-5>.
  - Greenbaum LA, Fila M, Ardissino G, Al-Akash SI, Evans J, Henning P, et al. Eculizumab is a safe and effective treatment in pediatric patients with atypical hemolytic uremic syndrome. *Kidney Int.* 2016;89:701–11, <http://dx.doi.org/10.1016/j.kint.2015.11.026>.
  - Giordano C, Rivas J, Zervos X. An update on treatment of drug-induced liver injury. *J Clin Transl Hepatol.* 2014;2:74–9, <http://dx.doi.org/10.14218/JCTH.2014.00005>.
  - Haque T, Sasatomi E, Hayashi PH. Drug-induced liver injury: pattern recognition and future directions. *Gut Liver.* 2016;10:27–36, <http://dx.doi.org/10.5009/gnl15114>.
  - Tajiri K, Shimizu Y. Practical guidelines for diagnosis and early management of drug-induced liver injury. *World J Gastroenterol.* 2008;14:6774–85.
  - Brodsky RA, Young NS, Antonioli E, Risitano AM, Schrezenmeier H, Schubert J, et al. Multicenter phase 3 study of the complement inhibitor eculizumab for the treatment of patients with paroxysmal nocturnal hemoglobinuria. *Blood.* 2008;111:1840–7, <http://dx.doi.org/10.1182/blood-2007-06-094136>.
  - Hillmen P, Hall C, Marsh JCW, Elebute M, Bombara MP, Petro BE, et al. Effect of eculizumab on hemolysis and transfusion requirements in patients with paroxysmal nocturnal hemoglobinuria. *N Engl J Med.* 2004;350:552–9, <http://dx.doi.org/10.1056/NEJMoa031688>.
  - Hillmen P, Muus P, Röth A, Elebute MO, Risitano AM, Schrezenmeier H, et al. Long-term safety and efficacy of sustained eculizumab treatment in patients with paroxysmal nocturnal haemoglobinuria. *Br J Haematol.* 2013;162:62–73, <http://dx.doi.org/10.1111/bjh.12347>.
  - Fakhouri F, Hourmant M, Campistol JM, Cataland SR, Espinosa M, Gaber AO, et al. Terminal complement inhibitor eculizumab in adult patients with atypical hemolytic uremic syndrome: a single-arm, open-label trial. *Am J Kidney Dis.* 2016;68:84–93, <http://dx.doi.org/10.1053/j.ajkd.2015.12.034>.
- Aysegul Oruc<sup>a,\*</sup>, Yavuz Ayar<sup>a</sup>, Berna Aytac Vuruskan<sup>b</sup>, Abdumecit Yildiz<sup>a</sup>, Nimet Aktas<sup>c</sup>, Mahmut Yavuz<sup>a</sup>, Mustafa Gullulu<sup>a</sup>, Kamil Dilek<sup>a</sup>, Alparslan Ersoy<sup>a</sup>
- <sup>a</sup> Department of Internal Medicine, Division of Nephrology, Uludağ University Medical School, Bursa, Turkey  
<sup>b</sup> Department of Pathology, Uludağ University Medical School, Bursa, Turkey  
<sup>c</sup> Cekirge State Hospital, Department of Nephrology, Bursa, Turkey
- \* Corresponding author.  
 E-mail address: [aysegul@uludag.edu.tr](mailto:aysegul@uludag.edu.tr) (A. Oruc).

2013-2514/© 2017 Sociedad Española de Nefrología. Published by Elsevier España, S.L.U. This is an open access article under the CC BY-NC-ND license (<http://creativecommons.org/licenses/by-nc-nd/4.0/>).  
<https://doi.org/10.1016/j.nefro.2018.04.004>

## Case report: C3 glomerulopathy advancing atypical hemolytic uremic syndrome

### Informe de caso: glomerulopatía C3 avanzando en síndrome urémico hemolítico atípico

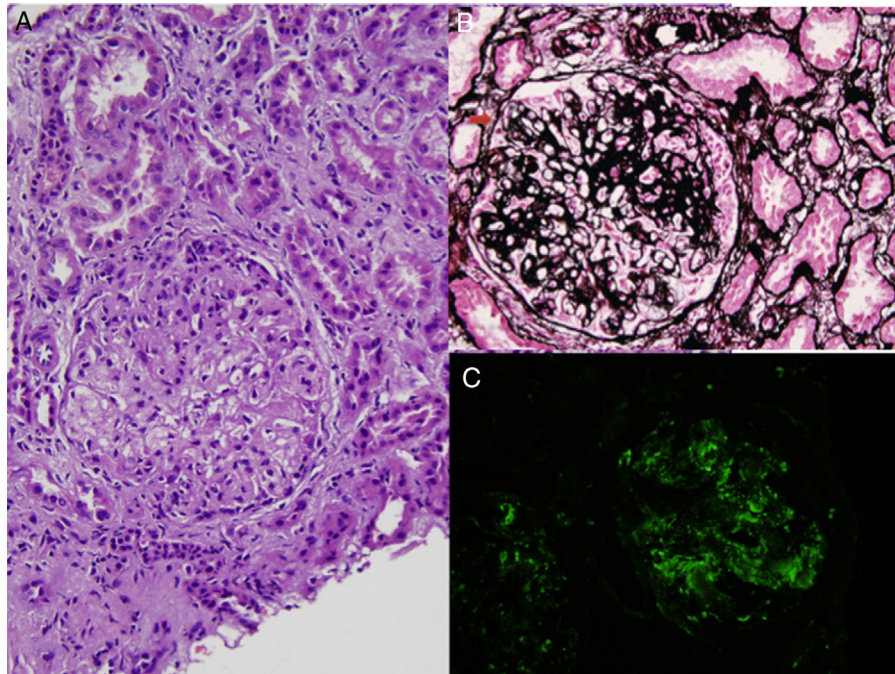
Dear Editor,

We present a case report that initially diagnosed as C3 glomerulopathy (C3G) and later developed aHUS treated with eculizumab that improved renal function.

A previously healthy 25-year-old woman presented with leg swelling. Only mild pretibial edema was detected in her physical examination. Laboratory workup revealed that an erythrocyte sedimentation rate 110 mm/h, a serum creatinine

concentration of 2 mg/dL and albumin level of 2 g/dL. Urinalysis revealed a proteinuria of 9 g/day and microscopic hematuria.

Antinuclear antibodies, cytoplasmic antineutrophil cytoplasmic antibodies and perinuclear anti-neutrophil cytoplasmic antibodies were negative, serum C3 and C4 levels were normal. Kidney biopsy was performed. The biopsy contained 7 glomeruli which showed mesangial hypercellularity, segmental endocapillary proliferation, basement membrane



**Fig. 1 – Glomerular mesangial and endocapillary hypercellularity (A), basement membrane duplication and crescent formation (B), and, mesangial and capillary C3 deposits by immunofluorescence (C) in renal biopsy (A, hematoxylin–eosin; B, periodic acid methenamin silver; C, anti-C3 FITC).**

thickening and duplication (Fig. 1A, B). Fibrocellular crescents were detected in 2 glomeruli (Fig. 1B). Focal segmental sclerosis was present in 40% of glomeruli. Immunofluorescence staining showed marked granular capillary wall and mesangial C3 deposition (Fig. 1C). Glomerular C1q and immunoglobulins were absent. The biopsy findings were consistent with C3G with a membranoproliferative pattern. Further classification of C3G could not be done, since electron microscopic examination was not available due to insufficient biopsy material. The patient was treated with 1 mg/kg/day methylprednisolone and 1 g/day mycophenolate mofetil (MMF), and previous treatment with ramipril was maintained.

Two months later, she was admitted to our clinic with shortness of breath with widely distributed crackles and ronchi on auscultation of both lungs. She had 3+ pretibial pitting edema in both legs. Laboratory results showed renal failure (serum creatinine: 3.2 mg/dL, uric acid: 8.2 mg/dL, Na: 126 mmol/L) with non-immune hemolytic anemia and thrombocytopenia. ADAMTS13 level was 30%. Atypical HUS was diagnosed and eculizumab treatment started after 5 sessions of plasmapheresis with hemodialysis because of persistent hypervolemia. Mycophenolate mofetil treatment was stopped because of thrombocytopenia. Genotyping of patient was performed with Sanger sequencing of *CFH* and *CFI* genes. Homozygosity for single-nucleotide polymorphism (SNPs) rs2298749 on 6 exon of *CFI* [S268S (TCG>TCA)] was detected. Hemodialysis was continued three times a week. After eight months of eculizumab therapy her serum creatinine levels were decreased to 3–4 mg/dL and her hemodialysis was further reduced to once a week.

C3 glomerulopathy is defined as the presence of C3 deposits without immunoglobulins on immunofluores-

cence microscopy along with subendothelial and mesangial electron-dense deposits by electron microscopy. Electron microscopy is required to differentiate C3 glomerulonephritis from dense deposit disease.<sup>1</sup> Although similarity between C3G and postinfectious glomerulonephritis is well known, we excluded postinfectious glomerulonephritis by clinical and follow-up data along with the presence of basement membrane changes by light microscopy.

Mutations in *CFH*, *CFI* and *C3*, and, the presence of anti-*CFH* antibodies have been previously demonstrated in patients with C3G and aHUS<sup>1</sup> and based on these findings authors recommended that special diagnostic tests [C3NeF, serum factor H, complement factor H-related (CFHR) protein gene mutations, serum factor B, serum factor I, and membrane cofactor protein (MCP or CD46), soluble C5b-9, complement factor H-related (CFHR) protein gene mutations] should be obtained in patients with DDD or C3G.<sup>1–3</sup> In our patient, we found a single nucleotide polymorphism in *CFI* gene; this SNP is not a disease-associated mutation but may cause susceptibility to these diseases.

To our knowledge, there is no prospective randomized trial on the treatment of C3G yet. Treatment suggestions are based on recent KDIGO meeting report.<sup>1</sup> In the present case, we also started MMF plus steroid regimen however we stopped MMF earlier because of persistent thrombocytopenia.

Eculizumab is a humanized monoclonal antibody that binds with high affinity to C5 and has been approved by FDA and EMA for the treatment of aHUS. Eculizumab prevents cleavage of C5, thereby precluding formation of C5a and the terminal complement complex (C5b-9), which has been implicated in the pathogenesis of both DDD and C3G.<sup>4–6</sup> In our case, eculizumab treatment resulted improvement of her residual

renal function. Eculizumab is a potent drug that can act even though in stage 5 kidney failure. Although re-biopsy could not be performed because of thrombocytopenia, treatment with eculizumab improved her renal function, including with long standing fibrotic changes.

In conclusion, we present a patient who was initially admitted with nephritic syndrome and C3G was diagnosed and immunosuppressive treatment was initiated, two months later after diagnosis she was re-admitted with thrombotic microangiopathy and aHUS was diagnosed. After administration of eight month of eculizumab therapy her residual renal clearance improved and her dialysis treatment was further reduced to once a week. The present case report demonstrated a CFI genetic variation associated alternative pathway dysregulation causing C3G and aHUS in the same patient and highlighted the shared pathogenesis in these alternative complement pathway associated diseases.

## Acknowledgments

The authors declare that they have no sources of funding for this study, and they have no conflicts of interest to declare.

## REFERENCES

1. Goodship TH, Cook HT, Fakhouri F, Fervenza FC, Frémeaux-Bacchi V, Kavanagh D, et al. Atypical hemolytic uremic syndrome and C3 glomerulopathy: conclusions from a “Kidney Disease: Improving Global Outcomes” (KDIGO) Controversies Conference. *Kidney Int.* 2017;91:539–51.
2. Goicoechea de Jorge E, Caesar JJ, Malik TH, Patel M, Colledge M, Johnson S, et al. Dimerization of complement factor H-related proteins modulates complement activation in vivo. *Proc Natl Acad Sci U S A.* 2013;110:4685.
3. Gale DP, de Jorge EG, Cook HT, Martinez-Barricarte R, Hadjisavvas A, McLean AG, et al. Identification of a mutation in complement factor H-related protein 5 in patients of Cypriot origin with glomerulonephritis. *Lancet.* 2010;376:794.
4. McCaughan JA, O'Rourke DM, Courtney AE. Recurrent dense deposit disease after renal transplantation: an emerging role for complementary therapies. *Am J Transplant.* 2012;12:1046.
5. Daina E, Noris M, Remuzzi G. Eculizumab in a patient with dense-deposit disease. *N Engl J Med.* 2012;366:1161.
6. Vivarelli M, Pasini A, Emma F. Eculizumab for the treatment of dense-deposit disease. *N Engl J Med.* 2012;366:1163.

Muge Catikkas<sup>a</sup>, Erol Demir<sup>a,\*</sup>, Yasemin Ozluk<sup>b</sup>,  
Yasar Caliskan<sup>a</sup>, Rabia Muberra Badur<sup>a</sup>, Aydin Turkmen<sup>a</sup>

<sup>a</sup> Division of Nephrology, Department of Internal Medicine, Istanbul Faculty of Medicine, Istanbul University, Istanbul, Turkey

<sup>b</sup> Department of Pathology, Istanbul Faculty of Medicine, Istanbul University, Istanbul, Turkey

\* Corresponding author.

E-mail address: [eroldemir83@yahoo.com](mailto:eroldemir83@yahoo.com) (E. Demir).

2013-2514/© 2018 Published by Elsevier España, S.L.U. on behalf of Sociedad Española de Nefrología. This is an open access article under the CC BY-NC-ND license (<http://creativecommons.org/licenses/by-nc-nd/4.0/>).  
<https://doi.org/10.1016/j.nefro.2018.04.001>

## Low rate of adverse events in home hemodialysis<sup>☆</sup>

## Baja tasa de eventos adversos en hemodiálisis domiciliaria

Dear Editor,

Currently due to the benefits reported with HHD,<sup>2,3</sup> there is growing interest in home haemodialysis (HHD).<sup>1</sup> In Spain, although the number of patients on HHD has increased in recent years, the percentage remains low,<sup>1</sup> one of the main problems being that there is little familiarity with the technique<sup>4</sup> and the fear of adverse events (AE) is manifested. For this reason, we considered it appropriate to analyse the AEs observed in the HHD unit of our Hospital from the beginning of the programme in March 2008 until June 2017.

We consider a serious adverse event (SAE) the one that required some type of emergency action by medical

professionals, being automatically reported by the patient to the hospital, usually over the phone. Minor adverse events (MAE) were recorded by the patient in the haemodialysis form, and we conducted a retrospective analysis of these.

Since the HHD programme was started, we have trained 35 patients, 32 were able to move home and 3 did not pass the training (2 patients lacked self confidence and one had associated comorbidity).

Of the 32 patients on HHD: average age 57.6 ± 13.1 years; Charlson index 4.1 ± 1.7; 18 men, 14 women, 25% with diabetes mellitus.

Haemodialysis (HD) time/session was 149.5 ± 16.1 min; frequency 5.3 ± 0.5 sessions/week; weekly time 791.9 ± 94.8 min;

DOI of original article:

<https://doi.org/10.1016/j.nefro.2017.09.009>.

\* Please cite this article as: Pérez Alba A, Reque Santiváñez J, Segarra Pedro A, Torres Campos S, Sánchez Canel JJ, Fenollosa Segarra MÁ, et al. Baja tasa de eventos adversos en hemodiálisis domiciliaria. *Nefrología.* 2018;38:452–454.