

effects: an observational study. *Nephrol Dial Transpl.* 2003;18:1135-41.

6. Helldén A, Lycke J, Vander T, Svensson JO, Odar-Cederlof I, Stahle L. The acyclovir metabolite CMMG is detectable in the CSF of subjects with neuropsychiatric symptoms during acyclovir and valaciclovir treatment. *J Antimicrob Chemother.* 2006;57:945-9.

Marta Ferreira*, Cristina Vega, Begoña Rivas, Rafael Selgas

Servicio de Nefrología, Hospital Universitario La Paz, Madrid, Spain

*Corresponding author.

E-mail address: martaferreirabermejo@gmail.com (M. Ferreira).

2013-2514/© 2017 Sociedad Española de Nefrología. Published by Elsevier España, S.L.U. This is an open access article under the CC BY-NC-ND license (<http://creativecommons.org/licenses/by-nc-nd/4.0/>). <https://doi.org/10.1016/j.nefro.2018.02.008>

Stenosis of the iliac artery after kidney transplantation as a cause of refractory hypertension and intermittent claudication[☆]

Estenosis de arteria ilíaca tras trasplante renal como causa de hipertensión arterial refractaria y claudicación

Dear Editor,

Vascular diseases in renal transplant patients are increasing in frequency due to the longer patient survival, the transplantation in older individuals with higher cardiovascular risk, and because many grafts come from donors with expanded criteria.¹ Post-transplant hypertension secondary to decreased renal blood flow, either due to involvement of the proximal aorto-iliac segment or the renal artery, is a form of hypertension that can be corrected. Abnormalities of the renal artery anastomosis should be suspected if there is evidence of ischemic nephropathy, resistant renovascular hypertension and claudication of the limb ipsilateral to the renal graft are associated, although all these findings may not always be present.²

We present the case of a kidney transplant woman who after 13 years of transplantation begins with a progressive deterioration of renal function associated with hypertension resistant to the treatment and claudication at a short distance of the left lower limb. The relevant history is polycystic kidney disease and ex-smoking (20 packages/year). On physical examination, she presented a decrease in the temperature of the left foot that appears pale and with absence of distal pulses.

The renal function decreased, serum creatinine increased from of 1.1 to 2.86 mg/dl without proteinuria.

Both the abdominal ultrasound and the Doppler ultrasound of the renal graft did not show abnormalities (resistance indices of 0.7-0.8).

The ankle-brachial index was 0.60 (normal: 0.9-1.2). A CT angiography was requested that showed a large intraluminal calcified lesion (reef coral) that caused a preocclusive lesion at the level of the left common iliac artery, immediately after the aorto-iliac bifurcation. Both the graft artery and the anastomosis and the hypogastric artery were permeable (Fig. 1).

Endovascular treatment by bilateral eco-guided femoral puncture with local anesthesia was performed. An Advanta[®] V12 8 mm × 3 mm balloon-expandable bilateral stent (Atrium, Hudson, NH, USA) was implanted in the aorto-iliac bifurcation without evidence of residual stenosis in the post-implant control arteriography (Fig. 2). This provision was used in kissing to cover the entire lesion avoiding compromising the ostium of the contralateral iliac axis.

There were no postoperative complications. After 30 days, blood pressure was controlled and renal function improved (serum creatinine was 2.17 mg/dl and eGFR by MDRD was 23 ml/min/1.73 m²). At 6 months, a new CT angiography was performed in which the permeability of the kissing stent persisted without associated lesions.

Causes of renal function deterioration: acute rejection, acute tubular necrosis, pharmacological toxicity and stenosis of the renal artery in its 2 presentations, proximal and

DOI of original article:

<https://doi.org/10.1016/j.nefro.2017.05.006>.

[☆] Please cite this article as: Sobrino Díaz L, Mosquera Rey V, Rodríguez García M, Alonso Pérez M, Ridao Cano N, Díaz Corte C, et al. Estenosis de arteria ilíaca tras trasplante renal como causa de hipertensión arterial refractaria y claudicación. *Nefrología.* 2018;38:325-327.

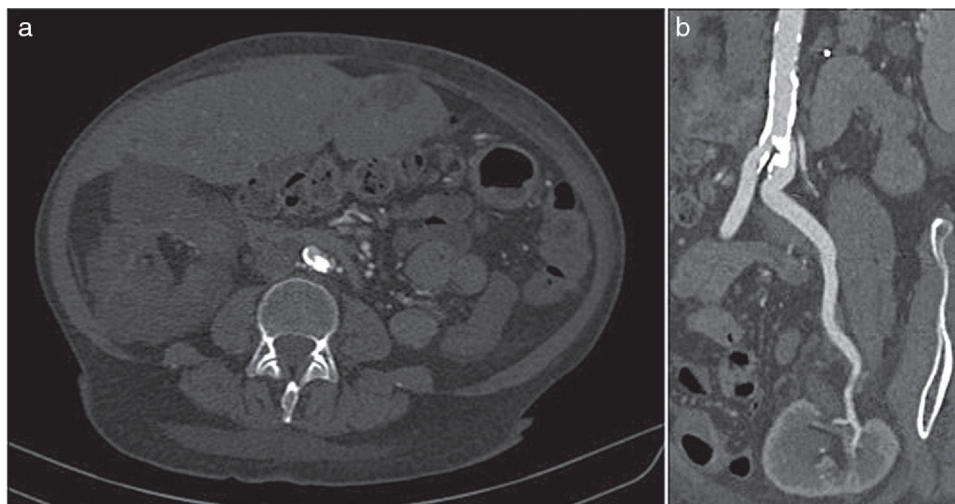


Fig. 1 – Computed tomographic angiography. (a) In the cross-section, an intraluminal calcified lesion was observed at the origin of the left common iliac artery. (b) In the multilane reconstruction, it is observed permeability without stenosis in the renal artery of the transplanted graft.

distal were ruled out. Due to the development of collateral circulation in the lower limbs the presence of intermittent claudication is not always present³ (in 50% of cases) and several groups highlight the presence of resistant hypertension as the key sign in the diagnosis of stenosis of the proximal aortic-iliac segment.⁴

Doppler ultrasound is the screening technique of choice to achieve a diagnosis^{5,6} which should be followed by angio-CT as confirmation test.⁷

The Doppler ultrasound findings characteristic of arterial stenosis, both in the proximal form and in the renal artery itself, are low intraparenchymal resistance indices and a velocity gradient of 2:1⁸ between the stenotic and prestenotic

segments. In our case it was necessary to perform the angio-CT for the definitive diagnosis.

The treatment of choice is percutaneous angioplasty with/without a stent, as long as the stenosis of the renal artery is short and distal to the anastomosis or when the stenosis is located in the iliac artery proximal to the graft.⁴ Angioplasty is effective in 80% of cases, although a recurrence of 20% has been observed. Surgery is used in complex cases, with arterial kinking, long lesions and stenosis in the anastomosis.

The COBEST study⁹ is the only prospective, randomized, multicenter trial comparing the use of coated stent versus the free stent in iliac occlusive disease. Their results have shown

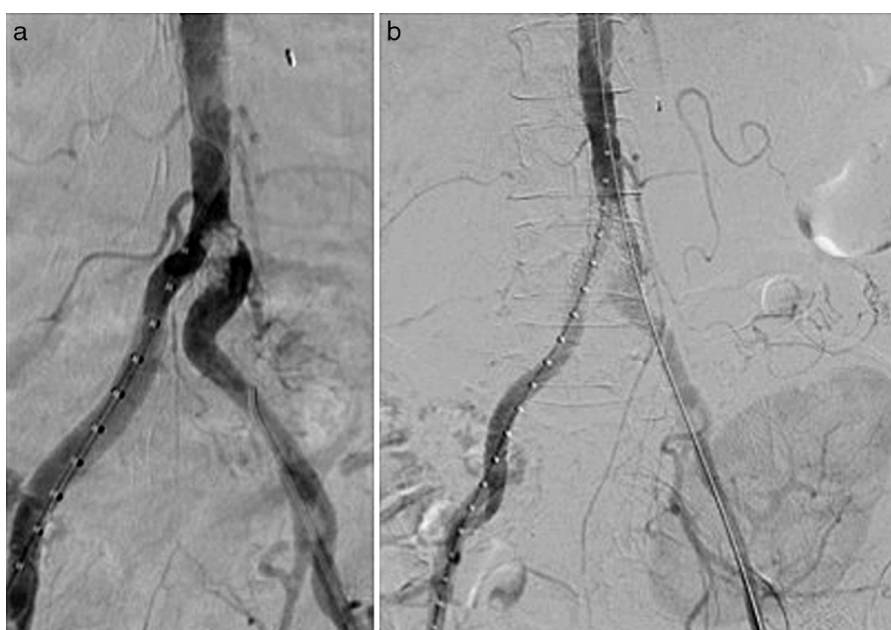

Fig. 2 – Intraoperative arteriography. (a) A calcified intraluminal lesion was observed at the origin of the left common iliac artery. (b) Post-implantation control of the coated stents without residual stenosis.

a significantly greater patency, in the short and long term, in favor of the coated stent versus the free stent in complex lesions classified as type C and D of the TASC II.

Although the use of the coated stent in the aorta-iliac bifurcation is not widespread, some authors such as Sabri et al.¹⁰ recommend its use since it provides better long-term patency (92%) than the free stent (62%). It has been seen that the aortic bifurcation coated stent provides greater laminar flow, decreased thrombogenicity, lower probability of plaque prolapse and less hyperplastic tissue growth compared to the free stent.

Endovascular treatment with kissing-coated stents in aorto-iliac occlusive disease is a low-invasive alternative that was effective in our case. After literature review we have not seen any case treated by this technique.

REFERENCES

1. Aikimbaev K, Akgul E, Aksungur E, Demir E, Erken U. Iliac artery stenosis as a cause of posttransplant renal failure and claudication. *Int Urol Nephrol.* 2007;39:1273-6.
2. Hypertension after renal transplantation [Internet]. Waltham (MA): UpToDate; 2016. Available from: <http://www.uptodate.com/contents/hypertension-after-renal-transplantation> [accessed 15.11.16].
3. Becker B, Odorico J, Becker Y, Levenson G, McDermott J, Grist T, et al. Peripheral vascular disease and renal transplant artery stenosis: a reappraisal of transplant renovascular disease. *Clin Transplant.* 1999;13:349-55.
4. Voiculescu A, Hollenbeck M, Plum J, Hetzel G, Mödder U, Pfeiffer T. Iliac artery stenosis proximal to a kidney transplant: clinical findings, duplex-sonographic criteria, treatment, and outcome. *Transplantation.* 2003;76:332-9.
5. Hollenbeck M, Kutkuhn B, Grabensee B. Colour Doppler ultrasound in the diagnosis of transplant renal artery stenosis. *Bildgebung.* 1994;61:248-54.
6. O'Neill W, Baumgarten D. Ultrasonography in renal transplantation. *Am J Kidney Dis.* 2002;39:663-78.
7. Rubin G. Spiral (helical) CT of the renal vasculature. *Semin Ultrasound CT MRI.* 1996;17:374-97.
8. Kobayashi K, Censullo M, Rossman L, Kyriakides P, Kahan B, Cohen A. Interventional radiologic management of renal transplant dysfunction: indications, limitations, and technical considerations. *Radiographics.* 2007;27:1109-30.
9. Mwipatayi BP, Sharma S, Daneshmand A, Thomas SD, Vijayan V, Altaf N. Durability of the balloon-expandable covered versus bare-metal stents in the Covered versus Balloon Expandable Stent Trial (COBEST) for the treatment of aortoiliac occlusive disease. *J Vasc Surg.* 2016;64, 83-94.e1.
10. Sabri SS, Choudhri A, Orgera G, Arslan B, Turba UC, Harthun NL. Outcomes of covered kissing stent placement compared with bare metal stent placement in the treatment of atherosclerotic occlusive disease at the aortic bifurcation. *J Vasc Interv Radiol.* 2010;21:995-1003.

Lucía Sobrino Díaz^{a,*}, Vicente Mosquera Rey^b,
Minerva Rodríguez García^a, Manuel Alonso Pérez^b,
Natalia Ridao Cano^a, Carmen Díaz Corte^c,
Ahmad Amer Zanabali Al-Sibbai^b

^a Área de Gestión Clínica de Nefrología, Hospital Universitario Central de Asturias, Oviedo, Asturias, Spain

^b Servicio de Angiología y Cirugía Vasculard, Hospital Universitario Central de Asturias, Oviedo, Asturias, Spain

^c REDinREN, FRIAT, Spain

*Corresponding author.

E-mail address: lucia.sobrino@gmail.com (L. Sobrino Díaz).

2013-2514/© 2017 Sociedad Española de Nefrología. Published by Elsevier España, S.L.U. This is an open access article under the CC BY-NC-ND license (<http://creativecommons.org/licenses/by-nc-nd/4.0/>).

<https://doi.org/10.1016/j.nefro.2018.01.010>

Heyde syndrome: Correction of anaemia after aortic valve replacement in a hemodialysis patient[☆]

Síndrome de Heyde: resolución de anemia tras reemplazo valvular aórtico en paciente en hemodiálisis

Dear Editor,

The coexistence of aortic stenosis (AS) and iron-deficiency anaemia due to gastrointestinal bleeding caused by angiodysplasia is known as Heyde syndrome. It was described in 1958

by Dr. Edward Heyde.¹ It is now defined by the triad of severe AS, coagulopathy due to acquired type 2A von Willebrand syndrome and anaemia secondary to angiodysplasia-induced gastrointestinal bleeding.²⁻⁴ We present the case of a 63-year-old woman with chronic kidney disease (CKD) due to

DOI of original article:

<http://dx.doi.org/10.1016/j.nefro.2017.05.002>.

[☆] Please cite this article as: Milla M, Hernández E, Mérida E, Yuste C, Rodríguez P, Praga M. Síndrome de Heyde: resolución de anemia tras reemplazo valvular aórtico en paciente en hemodiálisis. *Nefrología.* 2018;38:327-329.