

^b Departamento de Medicina Nuclear, Hospital Clínic, Barcelona, Spain

^c Departamento de Nefrología, Hospital Clínic, Barcelona, Spain

* Corresponding author.

E-mail address: nusanchez@clinic.ub.es (N. Sánchez).

2013-2514/© 2017 Sociedad Española de Nefrología. Published by Elsevier España, S.L.U. This is an open access article under the CC BY-NC-ND license (<http://creativecommons.org/licenses/by-nc-nd/4.0/>).
<https://doi.org/10.1016/j.nefro.2017.10.003>

Kidney damage due to the use of anabolic androgenic steroids and practice of bodybuilding[☆]

Consecuencias renales del uso de esteroides anabolizantes y práctica de culturismo

Dear Editor,

We report the case of a patient, male with acute kidney failure and haemolytic anaemia in the context of secondary malignant hypertension (HTN) and anabolic steroid user.

Malignant HTN is a disease characterised by a marked rise in blood pressure (BP) (systolic > 180–190 mmHg and diastolic > 120–130 mmHg), grade III–IV hypertensive retinopathy and abnormal kidney function.^{1,2} It is often accompanied by microangiopathic haemolytic anaemia (schistocytes in peripheral blood) with high LDH, undetectable haptoglobin, reticulocytosis, thrombocytopenia and a negative Coombs test. There may be proteinuria and micro- or macrohaematuria. An immunology study is usually negative and is useful to rule out connective tissue diseases. Lesions often develop in other target organs, leading to, for example, left-sided heart failure or hypertensive encephalopathy. Therefore, it is necessary to perform an electrocardiogram, a chest X-ray, an echocardiogram or a brain scan.³

Furthermore, the use of anabolic steroids has risen to alarming proportions in recent decades. Although effects on kidney function are uncommon, some cases have been documented in which a combination of anabolic steroids and creatine supplements has caused kidney damage. Anabolic steroids have a known effect on hypernatraemia, accompanied by an increase in urinary excretion of potassium and hydrogen ions, resulting in hypokalaemic alkalosis.^{4,5}

We report the case of a 37-year-old male with hypertension known for the last 10 years, with no treatment, who regularly practised bodybuilding; took intramuscular anabolic steroids (testosterone and stanozolol), growth hormone and oral creatine; and followed a protein-rich diet. He visited the Emergency Department due to signs and

symptoms of general malaise, nausea, headache and blurred vision that had lasted for one week. He was found to have high BP (250/180 mmHg) and severe acute kidney failure. Complementary tests revealed anaemia and thrombocytopenia (haemoglobin 9.9 g/dl, haematocrit 28.4%, platelets 91,000/mm³) as well as the above-mentioned kidney failure (urea 246 mg/dl, creatinine 23.5 mg/dl). An immunology study was negative (except for a slight decrease in C3 and C4 fraction), with proteinuria of 1.7 g/24 h and oligoalbuminuria of 491 mg/l. A peripheral blood smear showed real thrombocytopenia and schistocytes (2.1%). Venous blood gases were normal and potassium levels were at the lower limit of normal (this was likely an effect of the anabolic steroids). Given his haemolytic anaemia with mild thrombocytopenia and schistocytes on smear testing, the patient was thought to have microangiopathic haemolytic anaemia. A brain CT scan was performed (to rule out brain damage secondary to HTN). The scan showed a punctiform image in the caudate nucleus that was not suggestive of acute haemorrhagic lesion.

Despite intravenous hypotensive treatment (labetalol and nitrites), the patient's BP levels remained high. Therefore, it was decided to admit the patient to the Intensive Care Unit and start acute haemodialysis and plasmapheresis simultaneously on an emergency basis. A dilated eye fundi examination was performed and yielded a result consistent with grade IV hypertensive retinopathy. A kidney ultrasound showed destructured kidneys with poor corticomedullary differentiation and obvious asymmetry. An angio-CT scan (Fig. 1) ruled out left renal artery stenosis, but revealed an aneurysm in the left renal artery 2 cm in diameter with a calcified and thrombosed wall. An ECG showed signs of left ventricular hypertrophy and diastolic overload, and an echocardiogram showed severe concentric LV hypertrophy with preserved systolic function.

DOI of original article:

<http://dx.doi.org/10.1016/j.nefro.2017.03.004>.

[☆] Please cite this article as: Merino García E, Borrego Utiel FJ, Martínez Arcos MÁ, Borrego Hinojosa J, Pérez del Barrio MP. Consecuencias renales del uso de esteroides anabolizantes y práctica de culturismo. *Nefrología*. 2018;38:101–103.

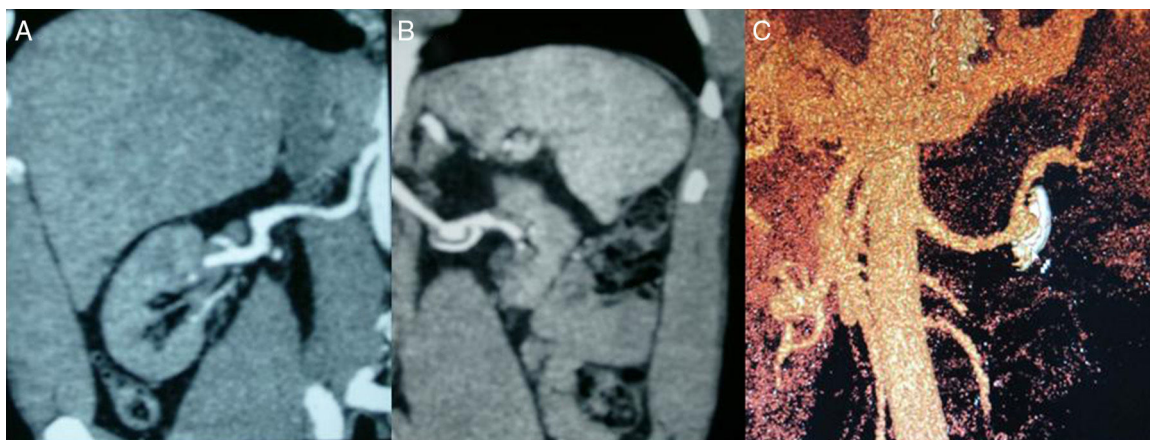


Fig. 1 - (A) Right renal artery with no signs of stenosis and right kidney with size preserved. **(B)** Left renal artery with no signs of stenosis; aneurysm 2 cm in diameter; atrophic left kidney. **(C)** 3D reconstruction of aneurysm with calcified and thrombosed wall.

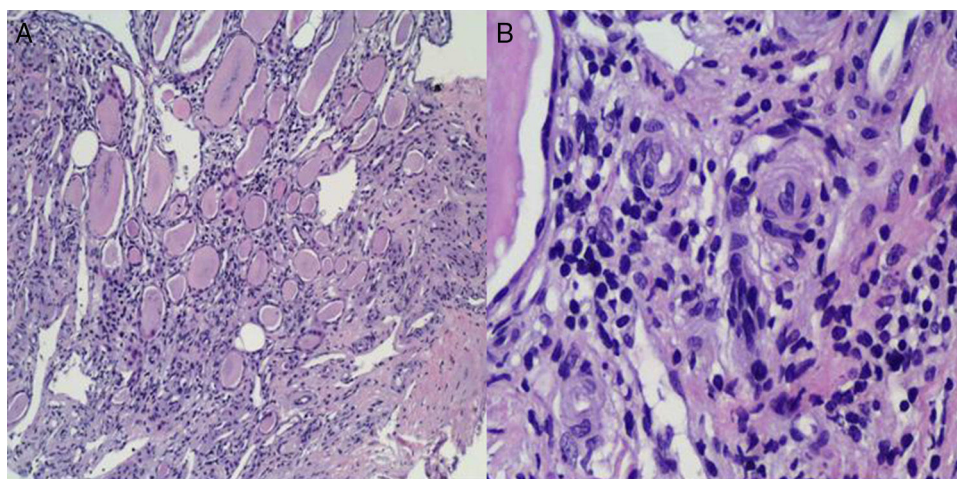


Fig. 2 - (A) Clear histological signs of chronic interstitial kidney disease characterised by tubular dilation rich in material with a colloid-like appearance offering a typical picture of “renal thyroidisation”. **(B)** In small vessels and the medullary region, myointimal proliferation is observed with luminal occlusion and initial middle-layer proliferation with incipient “onion-layer” formation.

As soon as the patient was admitted to the Intensive Care Unit, while he was being administered IV nitrites and labetalol, oral treatment with an ACE inhibitor (enalapril 20 mg/12 h) was started. After he had been hospitalised for 24 h, he started to show gradual clinical improvement: his BP levels stabilised and his platelet count recovered. This made it possible to discontinue his IV hypotensive medication and plasmapheresis after 4 sessions. A kidney biopsy (Fig. 2) yielded limited material, mainly medulla, and no cortex, due to technical difficulties given the patient's extensive muscle mass. Indications of chronic interstitial kidney disease and, in small vessels, indications suggestive of malignant HTN were seen. As the patient met certain obvious clinical criteria and had highly suggestive dilated fundus examination and histology results, he was thought to have accelerated malignant HTN. Associated glomerular disease could not be ruled out due to a lack of glomeruli in the kidney sample.

Treatment of malignant HTN should be started immediately. Initially, it may be necessary to use parenteral

drugs (labetalol, sodium nitroprusside) combined with oral drugs (ACE inhibitors/angiotensin II receptor antagonists, vasodilators such as calcium antagonists and other more powerful agents such as minoxidil plus beta-blockers and loop diuretics). Approximately 20% of cases require dialysis techniques.^{6,7} In our case, poor management of long-standing HTN, together with anabolic steroid use and intense anaerobic exercise, precipitated the development of malignant HTN. This disease requires immediate therapeutic action to prevent many complications leading to death in 25% of cases in 5 years, despite hypotensive treatment.

REFERENCES

1. Morales E, González R, Gutiérrez E, Gutiérrez-Solís E. Hipertensión arterial maligna. Una visión actualizada. *NefroPlus*. 2011;4:34-43.

2. Martínez Fernández G, Ortega Cerrato A, Oliver Galera E, NamCha T, Vara-Iniesta L, Gómez Roldán C, et al. Fallo renal causado por hipertensión maligna acelerada. *NefroPlus*. 2016;8:82-4.
3. Nzerue C, Oluwole K, Adejorin D, Pauksakon P, Fremont R, Akatue R, et al. Malignant hypertension with thrombotic microangiopathy and persistent acute kidney injury (AKI). *Clin Kidney J*. 2014;7:1-4.
4. Hickson RC, Ball KL, Falduto MT. Adverse effects of anabolic steroids. *Med Toxicol Adverse Drug Exp*. 1989;4:254-71.
5. Casavant MJ, Kathleen B, Griffith J. Consequences of use of anabolic androgenics steroids. *Pediatric Clin*. 2007;54:677-90.
6. Varon J, Marik PE. The diagnosis and management of hypertensive crises. *Chest*. 2000;118:214-27.
7. Montgomery HE, Kiernan LA, Whitworth CE. Inhibition of tissue angiotensin converting enzyme activity prevents malignant hypertension in TGR(mREN2)27. *J Hypertens*. 1998;16:635-43.

Enoc Merino García ^{a,*}, Francisco J. Borrego Utiel ^a, M. Ángeles Martínez Arcos ^b, Josefa Borrego Hinojosa ^a, M. Pilar Pérez del Barrio ^a

^a UGC de Nefrología, Complejo Hospitalario de Jaén, Jaén, Spain

^b UGC de Medicina Intensiva, Complejo Hospitalario de Jaén, Jaén, Spain

* Corresponding author.

E-mail address: enocmerino@gmail.com (E. Merino García).

2013-2514/© 2017 Sociedad Española de Nefrología. Published by Elsevier España, S.L.U. This is an open access article under the CC BY-NC-ND license (<http://creativecommons.org/licenses/by-nc-nd/4.0/>).

<https://doi.org/10.1016/j.nefro.2017.03.009>

Answer to the article: “*Serratia marcescens* bacteraemia outbreak in hemodialysis”. Comment on “*Serratia marcescens* bacteraemia outbreak in haemodialysis patients with tunnelled catheters due to colonisation of antiseptic solution. Experience at 4 hospitals”[☆]

Respuesta al artículo: «Brote de bacteriemia por *Serratia marcescens* en hemodiálisis». Comentarios al artículo: «Brote de bacteriemia por *Serratia marcescens* en pacientes portadores de catéteres tunelizados en hemodiálisis secundario a colonización de la solución antiséptica. Experiencia en 4 centros»

Dear Editor,

We appreciate the interest generated by the publication of the event that occurred in our hospitals. Although our article mentions the findings from only 4 sites, we are aware that it was a situation experienced at national level.¹ Even within the same region of Madrid, other hospitals have also presented their experience.²

In this issue of *Nefrología*, González Sanchidrián et al.³ describe the progress of their patients, showing outcomes similar to ours. As they rightly explain, the most critical aspect was the rapid detection of the presence of an atypical microor-

ganism as the cause of the complication. This set in motion the safety mechanisms present in all hospitals, with special emphasis on the importance of the involvement of the preventive medicine departments.⁴

This type of microorganism – although described as an agent of epidemic outbreaks – is rare in the colonisation of dialysis catheters.^{5,6} The presence of more than one patient affected in such a short period of time should be considered as potentially high risk, and a common origin must be investigated. All the affected hospitals made reasonable efforts to detect the origin of the microorganism, and the problem was solved once the focus had been confirmed. The presence of the antiseptic (source of infection) in all cases and its

DOI of original article:

<http://dx.doi.org/10.1016/j.nefro.2017.01.003>.

[☆] Please cite this article as: Merino JL, Bouarich H, Pita MJ, Paraíso V. Respuesta al artículo: «Brote de bacteriemia por *Serratia marcescens* en hemodiálisis». Comentarios al artículo: «Brote de bacteriemia por *Serratia marcescens* en pacientes portadores de catéteres tunelizados en hemodiálisis secundario a colonización de la solución antiséptica. Experiencia en 4 centros». *Nefrología*. 2018;38:103-104.