

7. Nseir W, Taha H, Abid A, Khateeb J. *Pseudomonas mendocina* sepsis in a healthy man. *Isr Med Assoc J.* 2011;13:375-6.
8. Ueda A, Saneoka H. Characterization of the ability to form biofilms by plant-associated *Pseudomonas* species. *Curr Microbiol.* 2015;70:506-13.
9. Warady B, Bakkaloglu S, Newland J, Cantwell M, Verrina E, et al. Consensus guidelines for the prevention and treatment of catheter-related infections and peritonitis in pediatric patients receiving peritoneal dialysis: 2012 update. *Perit Dial Int.* 2012;32:S32-86.
10. Li P, Szeto C, Piraino B, Bernardini J, Figueiredo AE, et al. Peritoneal dialysis - related infections recommendations: 2010 update. *Perit Dial Int.* 2010;30:393-423.

Teresa M. Jerónimo^{a,*}, Anabela M. Guedes^{a,b}, Sandra Stieglmair^c, Raquel Guerreiro^d, Ceú Laranjo^a, Idalécio Bernardo^a, Pedro L. Neves^{a,b}

^a Centro Hospitalar do Algarve, Nephrology Department, Rua Leão Penedo, 8000 Faro, Algarve, Portugal

^b Universidade do Algarve, Campus da Penha, 8005-139 Faro, Algarve, Portugal

^c Krankenhaus der Elisabethinen Linz, Fadingerstraße 1, 4020 Linz, Austria

^d Centro Hospitalar do Algarve, Clinical Pathology Department, Rua Leão Penedo, 8000 Faro, Algarve, Portugal

*Corresponding author.

E-mail address: teresa.jeronimo@hotmail.com (T.M. Jerónimo).

2013-2514/© 2016 Sociedad Española de Nefrología. Published by Elsevier España, S.L.U. This is an open access article under the CC BY-NC-ND license (<http://creativecommons.org/licenses/by-nc-nd/4.0/>).

<http://dx.doi.org/10.1016/j.nefro.2017.09.007>

Is acquired arterial-venous fistula related to Kaposi sarcoma?

Se adquiere la fístula arteriovenosa relacionada con sarcoma de Kaposi?

Dear Editor,

Kaposi's sarcoma (KS) is a rare inflammatory neoplasia originating from angiogenic vascular endothelial cells.¹ Human herpes virus-8 (HHV-8) is considered as a possible cause. KS is often observed in immunocompromised patients such as organ transplant or acquired immunodeficiency syndromes.² However, although not typical immunosuppression occurs in uraemic patients, various immunologic abnormalities occur.³

In previous reports, KS was described in dialysis patients with different co-morbidities.^{4,5} However, our report is the first case detected in the extremity where arterial-venous fistula (AVF) created for haemodialysis (HD).

Sixty-nine year's old male patient was on HD treatment for four years. Left arm AVF has been used as vascular access and had swelling for nearly one and half year. The lesions occurred firstly on the dorsal site of the hand. In medical history, there was no significant co-morbidity and history of drug use. In the physical examination deep purple, dark-brown black coloured macular, nodular lesions in the form of plaques starting on the left hand extending proximal forearm and oedema were detected (Fig. 1). In laboratory evaluation, except for blood urea nitrogen and serum creatinine levels, all tests were normal. Serological testing of hepatitis B/C and human immune deficiency viruses (HIV)

were negative. Complements, immunoglobulins, anti-nuclear antibodies and anti-neutrophil cytoplasmic antibody levels were normal. Chest X-ray and abdominal ultrasonography were normal. In punch biopsy, dilated irregular vascular proliferations surrounding the pre-existing capillaries in the superficial and deep dermis were observed (Fig. 2A). Spindle/oval shaped hyper chromatic atypical cells proliferation forming thin cords around stromal and vascular structures were observed (Fig. 2B). Focally extracellular PAS-positive hyaline globules were noted (Fig. 2C). Immune histochemical examination was positive for HHV-8 (Fig. 2D) and KS was diagnosed.

This is the first report in the literature in which KS occurred in the extremity where AVF exists. Also KS and HHV-8 co-existence was shown again in CKD.

KS incidence is very low and there are four different variants; classical, African-endemic, immunosuppressive therapy associated and HIV related.⁶ In our case, lesions localized in the left upper limb, progression rate was slow with no visceral organ involvement. Characteristic features and histopathological findings were consistent with classic KS.^{1,7}

KS is characterized by mutual stimulation of leucocyte and KS cells and cytokine-mediated cell proliferation process. HHV-8 is considered to be a causative agent.⁵ HHV-8 causes tumour growth by deletion of normal cell cycle and

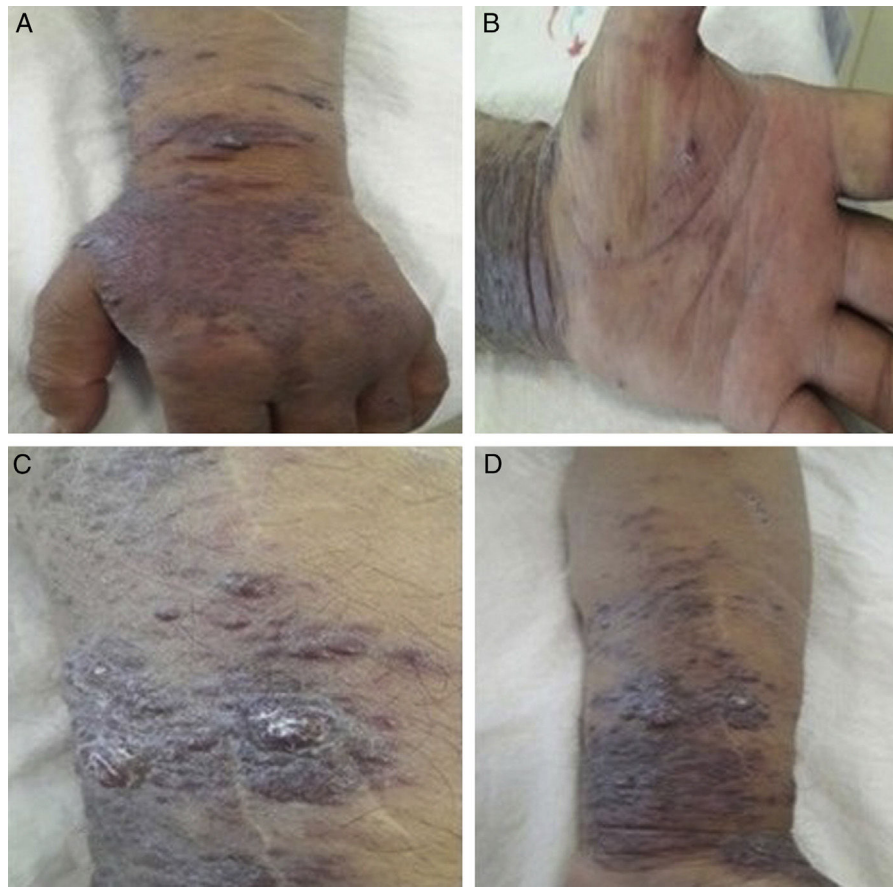

Figure 1 – Multiple discrete, (nonulcerated, erythematous-violaceous nodules and plaques on left forearm and hand(A,B,C,D).

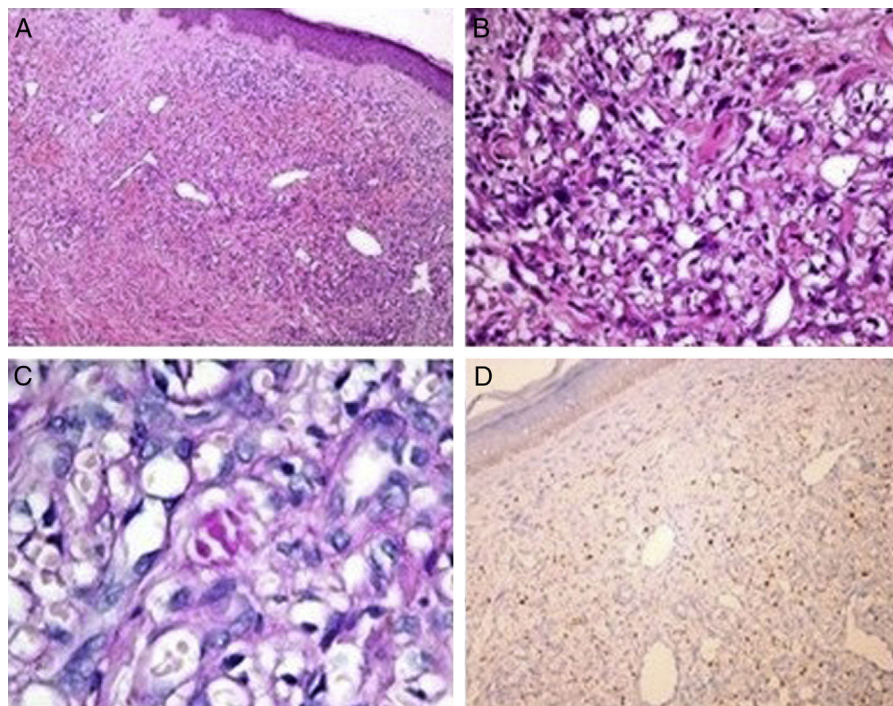


Figure 2 – (A) Dilated irregular vascular channels surround a pre-existing vessel with areas of haemorrhage and variable lymphoplasmacytic infiltration in the dermis (H&E, $\times 100$). (B) Proliferation of spindle-shaped endothelial cells arranged in fascicles in the dermis (H&E, $\times 400$). (C) PAS positive small hyalin globules are present in the cytoplasm (PAS $1000\times$). (D) Stromal spindle cells stain with antibody to HHV-8 (immunoperoxidase stain for HHV-8).

proliferation signal blockage.¹ Although the pathogenesis is still unclear, the uraemic toxins accumulated in the CKD may suppress both cellular and humoral immunity.⁸ Nevertheless, despite the known association between chronic inflammation and KS other malignancies are more prominent in dialysis patients.⁹ However, chronic inflammation caused by chronic venous stasis (CVS) may contribute to the development of KS in stasis area.¹⁰ As in our case, in previously submitted two cases KS is accompanied with venous stasis and this supports this data.⁴

As a result, in the extremity where AVF exists, HHV-8 and KS existed together. The inflammation and immunosuppression in CKD may contribute to the development and progression of KS.

REFERENCES

- Schwartz RA, Micali G, Nasca MR, Scuderi L. Kaposi sarcoma: a continuing conundrum. *J Am Acad Dermatol.* 2008;59:179-206.
- Chang Y, Cesarman E, Pessin MS, Lee F, Culpepper J, Knowles DM, et al. Identification of herpesvirus-like DNA sequences in AIDS-associated Kaposi's sarcoma. *Science.* 1994;266:1865-9.
- Kato S, Chmielewski M, Honda H, Pecoits-Filho R, Matsuo S, Yuzawa Y, et al. Aspects of immune dysfunction in end-stage renal disease. *Clin J Am Soc Nephrol.* 2008;3:1526-33.
- Lee D, Chun JS, Hong SK, Kang MS, Seo JK, Koh JK, et al. Kaposi sarcoma in a patient with chronic renal failure undergoing dialysis. *Ann Dermatol.* 2013;25:475-8.
- Herr H, Kim JU, Kang GH, Moon KC, Koh JK. Kaposi's sarcoma occurring during short-term dialysis: report of two cases. *J Korean Med Sci.* 2001;16:130-4.
- Schwartz RA. Kaposi's sarcoma: advances and perspectives. *J Am Acad Dermatol.* 1996;34:804-14.
- Akinde O, Obadofin O, Adeyemo T, Omoseebi O, Ikeri N, Okonkwo I, et al. Kaposi sarcoma among HIV infected patients in Lagos University Teaching Hospital, Nigeria: a 14-year retrospective clinico pathological study. *J Skin Cancer.* 2016;2016:9368023.
- Raska K Jr, Raskova J, Shea SM, Frankel RM, Wood RH, Lifter J, et al. T cell subsets and cellular immunity in end-stage renal disease. *Am J Med.* 1983;75:734-40.
- Rancho JA, Zarrabeitia MT, de Francisco AL, Amado JA, Napal J, Arias M, et al. Vitamin D therapy modulates cytokine secretion in patients with renal failure. *Nephron.* 1993;65:364-8.
- Pappas PJ, Teehan EP, Fallek SR, Garcia A, Araki CT, Back TL, et al. Diminished mononuclear cell function is associated with chronic venous insufficiency. *J Vasc Surg.* 1995;22:580-6.

Baris Eser, Ozlem Yayar, Ibrahim Dogan, Yilmaz Bas

Hitit University Corum Training and Research Hospital, Corum, Turkey

E-mail address: beser374@gmail.com (B. Eser).

2013-2514/© 2017 Published by Elsevier España, S.L.U. on behalf of Sociedad Española de Nefrología. This is an open access article under the CC BY-NC-ND license (<http://creativecommons.org/licenses/by-nc-nd/4.0/>). <http://dx.doi.org/10.1016/j.nefro.2017.09.008>

Calcimimetics have had no impact on the indications for surgery of tertiary hyperparathyroidism[☆]

Los calcimiméticos no han tenido impacto en la cirugía del hiperparatiroidismo terciario

Dear Editor,

Tertiary hyperparathyroidism (THPT) occurs in 2-25% of renal transplant patients with normal renal function. THPT is due to the autonomous proliferation of the parathyroid glands.^{1,2} Hypercalcemia impairs renal function through vasoconstriction and causes tubulointerstitial calcifications, which limits long-term graft survival.³ Therefore, early treatment of

hypercalcemia is important to prevent deterioration of renal graft function.

Until year 2005, when calcimimetics became available, surgical treatment of THPT was the only effective strategy to control hypercalcemia in renal transplant patients.^{3,4} The calcimimetic, cinacalcet controls hypercalcemia without affecting renal function.^{5,6} However, while cinacalcet reduces the need for parathyroidectomy in patients with severe

DOI of original article:

<http://dx.doi.org/10.1016/j.nefro.2016.10.021>.

[☆] Please cite this article as: Ruiz J, Ríos A, Rodríguez JM, Llorente S, Jimeno L, Parrilla P. Los calcimiméticos no han tenido impacto en la cirugía del hiperparatiroidismo terciario. *Nefrologia.* 2017;37:651-653.