

specific immunoglobulin secreting B lymphocytes against that protein, by cross-reactivity with antigens of the EBV itself.¹⁰ It is not known why, despite presenting this antibody, it does not develop symptoms although the titer presented has never been very high. The patient's HLA was performed and predisposing alleles for autoimmune diseases have not been found.

Regarding treatment, the glomerulopathy resolved in parallel to the mononucleosis. In the literature, some cases received corticosteroids, especially those with tubulointerstitial involvement. That was not our case that only had slight renal clinical and histological involvement (although the mesangial hypercellularity was diffuse in some glomeruli, it was segmental in others and, but in general it was mild). Acyclovir was not given since bibliography reports low efficacy.

We conclude that the frequent atypical presentation of IM in the adult can lead to delay in the diagnosis. The renal involvement is usually tubulointerstitial by cytotoxicity in which the virus can be found, and virus is less frequently observed in glomeruli. Should take into account the pathogenesis by immunocomplexes and complement activation. EBV is considered a "trigger" of self-reactive phenomena that can persist over the time and it may cause an autoimmune disease in cases with a predisposing environment.

REFERENCES

- Goltzman G, Nagornov S, Horwitz M, Rapoport MJ. Epstein-Barr virus infections in adults: a diagnostic challenge. *Harefuah*. 2000;138:640-3.
- Zafir B, Aviv A, Reichman N, Flatau E. Epstein-Barr virus-associated pericarditis and pericardial effusion: case report and diagnostic aspects. *Eur J Intern Med*. 2005;16:528-30.
- Lee S, Kjellstrand CM. Renal disease in infectious mononucleosis. *Clin Nephrol*. 1978;9:236-40.
- Joh K, Kanetsuna Y, Ishikawa Y, Aizawa S, Imadachi A, Tastusawa O, et al. Epstein-Barr virus genome-positive tubulointerstitial nephritis associated with immune complex-mediated glomerulonephritis in chronic active EB virus infection. *Virchows Arch*. 1998;432:567-4573.
- Andres GA, Kano K, Elwood C, Prezyna A, Sepulveda M, Milgrom F. Immune deposit nephritis in infectious

- mononucleosis. *Int Arch Allergy Appl Immunol*. 1976;53:136-44.
- Wollheim FA, Williams RC. Studies on the macroglobulins of human serum polyclonal immunoglobulin class M (IgM) increase in infectious mononucleosis. *N Engl J Med*. 1966;274:61-7.
- Charlesworth JA, Pussell BA, Roy LP, Lawrence S, Robertson MR. The complement system in infectious mononucleosis. *Aust N Z J Med*. 1977;7:23-6.
- Garzelli C, Incaprera M, Bazzichi A, Falcone G. Detection of an idiotope on a human monoclonal autoantibody by monoclonal anti-idiotypic antibody and its relationship to Epstein-Barr virus-induced autoimmunity. *Autoimmunity*. 1992;11:171-7.
- Niller HH, Wolf H, Minarovits J. Regulation and dysregulation of Epstein-Barr virus latency: Implications for the development of autoimmune diseases. *Autoimmunity*. 2008;41:298-328.
- Newkirk MN, van Venrooij WJ, Marshall GS. Autoimmune response to U1 small nuclear ribonucleoprotein (U1 snRNP) associated with cytomegalovirus infection. *Arthritis Res*. 2001;3:243-8.

M. Adoración Martín-Gómez^{a,*}, Mercedes Caba Molina^b, Gracia Cruz Caparros^c, Encarnación Guerrero Sánchez^d, Abelardo Caballero González^e, Mercedes Gómez Morales^b

^a Unidad de Nefrología, Hospital de Poniente, El Ejido, Spain

^b Servicio de Anatomía Patológica, Hospital San Cecilio, Granada, Spain

^c Medicina Interna, Hospital de Poniente, El Ejido, Spain

^d Sección de Anatomía Patológica, Hospital de Poniente, El Ejido, Spain

^e Servicio de Inmunología, Hospital Carlos Haya, Málaga, Spain

* Corresponding author.

E-mail address: doritamg@gmail.com (M.A. Martín-Gómez).

2013-2514/© 2016 Sociedad Española de Nefrología. Published by Elsevier España, S.L.U. This is an open access article under the CC BY-NC-ND license (<http://creativecommons.org/licenses/by-nc-nd/4.0/>).

<http://dx.doi.org/10.1016/j.nefro.2016.11.015>

Exophthalmos and hyperparathyroidism[☆]

Exoftalmos e hiperparatiroidismo

Dear Editor,

The brown tumor, also known as osteoclastoma, is a local and benign lesion of the bone. It appears as a consequence of an increase in osteoclastic activity and fibroblastic proliferation in the context of severe primary or secondary

hyperparathyroidism (2ndHPTH), the latter occurring in chronic kidney disease (CKD) due to decreased vitamin activity D at the renal level, with decreased phosphorus excretion and a tendency to hypocalcemia, which stimulates the growth of parathyroid glands. By microscopy the brown tumor is characterized by an increase in osteoclast activity, expansion

[☆] Please cite this article as: Mora Mora MT, Marín Álvarez JP. Exoftalmos e hiperparatiroidismo. *Nefrología*. 2017;37:441-443.

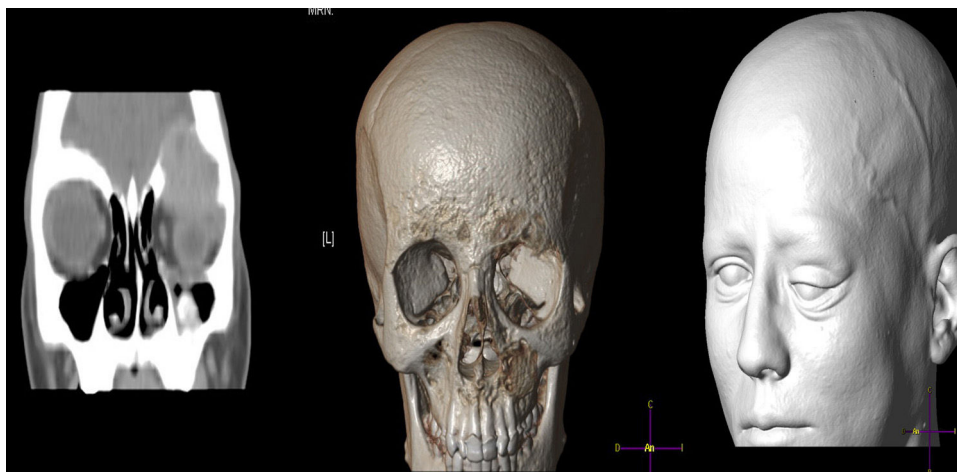

Fig. 1 – Cranial and orbital CT with pre-surgery reconstruction.

of bone resorption and formation of new bone tissue; there are irregularities in the of the trabecular tissue thickness and peritrabecular fibrosis. The presence of multinucleated giant cells and interstitial hemorrhage with hemosiderin deposits gives it the characteristic brown appearance.^{1,2}

Complete regression or disappearance of the brown tumor usually occurs after parathyroidectomy, although depending on the location and local destruction capacity, it can cause compression or pathological fractures. Generally, it is a multiple lesion that preferentially affects the ribs, clavicles, mandible and pelvis³; orbital involvement is infrequent.²

We present the case of a 27-year-old woman with CKD secondary to nephronoptosis that underwent 2 renal transplants, the first one anticipated at 7 years of age and the second at 9 years, with loss of both due to chronic graft nephropathy. She finally started hemodialysis at 23 years of age. After 4 years on hemodialysis and with a history of more than 5 months of evolution, the patient showed severe secondary HP with a maximum PTHi of 4876 pg/ml, hypercalcemia and normo- and hyperphosphatemia that is not controlled despite treatment with cinacalcet, vitamin D analogs and phosphate binders. ^{99m}Tc-sestamibi scan shows pathological uptake of the radiotracer in all parathyroid glands demonstrating a polyglandular hyperplasia. In addition, physical examination is remarkable for the progressive and pronounced appearance of an exophthalmos with caudal displacement of the left orbit and a decrease in vision. Reconstructive orthopedic CT (Fig. 1) and MRI describe several cystic-looking bone radiolucent lesions of 3 left periorbital brown tumors located respectively in the orbit ceiling with extension to the ipsilateral frontal sinus, in the left upper jaw and in the ascending branch of the left mandible with secondary arterial occlusion. With these findings, a total parathyroidectomy was performed with suprasternal autotransplantation to control 2nd HPTH and to achieve the reduction of tumors. After the intervention, PTHi levels fall rapidly with development of a hungry bone syndrome that requires high doses of calcium, vitamin D and hemodialysis with calcium of 1.75 μ mol/l, which ensures the success of the intervention. Two months later, the analytical improvement is not accompanied by reduction

of clinical symptoms; exophthalmos and compressive optic neuropathy continues. The CT scan shows an increase in size of the orbital ceiling lesion requiring excision. Microscopic examination revealed brown bone tumor.

At present, only 19 cases have been described with periorbital involvement. In most cases, tumor excision is performed, although other different locations are described in which with the total parathyroidectomy has been followed by remission of the bone lesion.³⁻⁵

Our case was resolved with parathyroidectomy and tumor excision (Fig. 2). The prevalence of brown tumor in patients with 2ndHPTH is 1.5-13% in CKD,¹ being more frequent in young women.⁶ However, a cautious differential diagnosis should be made and rule out bone tumor implants. Nowadays, the measurement of and the effective treatment of 2ndHPTH, the appearance of new cases is decreasing.⁷

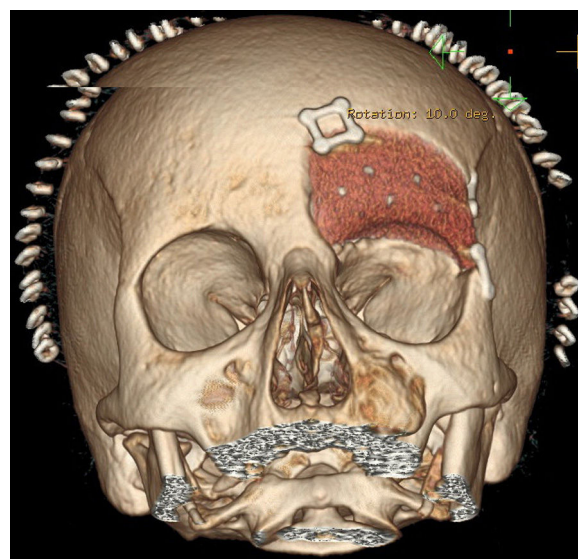


Fig. 2 – Cranial and orbital CT with post-surgery reconstruction.

REFERENCES

- Mateo L, Massuet A, Solá M, Pérez A, Musulen E, Sánchez MC. Brown tumor of the cervical spine: a case report and review of the literature. *Clin Rheumatol*. 2010;30:419-24.
- Bahrami E, Alireza T, Ebrahim H, Mohammadreza S. Maxillary and orbital brown tumor of primary hyperparathyroidism. *Am J Case Rep*. 2012;13:183-6.
- Monteiro ML. Multiple brown tumors of the orbital walls: case report. *Arq Bras Oftalmol*. 2009;72:116-8.
- Gonzalez-Martínez E, Santamarta-Gómez D, Varela-Rois P, García-Cosamalón J. Brown tumor of the orbital roof as an initial and isolated manifestation of secondary hyperparathyroidism. *Orbit*. 2010;29:278-80.
- Oliveira FM, Makimoto TE, Scalissi NM, Marone MM, Maeda SS. Regression of orbital brown tumor after surgical removal of parathyroid adenoma. *Arch Endocrinol Metab*. 2015;59:455-9.
- Daniels JS. Primary hyperparathyroidism presenting as a palatal brown tumor. *Oral Surg Oral Med Oral Pathol Oral Radiol Endod*. 2004;98:409-13.
- Jafari-Pozve N, Ataie-Khorasgani M, Jafari-Pozve S, Ataie-Khorasgani M. Maxillofacial brown tumors in secondary hyperparathyroidism: a case report and literature review. *J Res Med Sci*. 2014;19:1099-102.

María Teresa Mora Mora^{a,*}, Jesús Pedro Marín Álvarez^b

^a Sección de Nefrología, Complejo Hospitalario Universitario de Huelva, Huelva, Spain

^b Sección de Nefrología, Hospital San Pedro de Alcántara, Cáceres, Spain

*Corresponding author.

E-mail address: maytemorabis@hotmail.com

(M.T. Mora Mora).

2013-2514/© 2016 Sociedad Española de Nefrología. Published by Elsevier España, S.L.U. This is an open access article under the CC BY-NC-ND license (<http://creativecommons.org/licenses/by-nc-nd/4.0/>).

<http://dx.doi.org/10.1016/j.nefro.2017.06.009>

Transient hyperphosphatasemia in a child with nephrolithiasis and severe prematurity

Hiperfosfatemia transitoria en un niño con nefrolitiasis y antecedentes de prematuridad severa

Dear Editor,

Transient hyperphosphatasemia of infancy and early childhood (THI) is a benign, usually accidentally detected condition characterised by transiently increased activity of serum alkaline phosphatase (S-ALP) in children under five years of age, without any signs of metabolic bone disease or hepatopathy corresponding with the increased S-ALP.¹⁻⁴ When detected in a child with either chronic bone, liver or kidney disease, THI might may raise significant concerns.⁴⁻⁶

A 13-months' old boy with a complicated perinatal history (severe prematurity – 26th week of gestation, birthweight 1085 g, respiratory distress syndrome, reanimation, neonatal sepsis, pneumonia, artificial ventilation, necrotising enterocolitis, anaemia, hypophosphataemia and osteopathy of prematurity) and resulting bronchopulmonary dysplasia (with consequent furosemide treatment in the infantile period), was hospitalised because of renal colic manifested by painful crying with gross haematuria. Abdominal ultrasound revealed renal stones in each kidney, diameter 3 mm on the left and 6 mm on the right, respectively. The serum values of blood urea nitrogen (BUN), creatinine, potassium (S-K), sodium (S-Na), calcium (S-Ca), phosphate (S-P), magnesium (S-Mg), alanin-aminotransferase (S-AST), apartate-aminotransferase (S-ALT), parathyroid hormone (S-PTH) were all within normal

reference range, same as the urinary concentrations of Ca, P, Mg and urinary calcium/creatinine ratio (U-Ca/U-cr). However S-ALP was 34 μ kat/L (normal 2.5–9.5 μ kat/L). Wrist X-ray was normal without any signs of rickets. As rickets was ruled out, vitamin D levels were not assessed. The only possible relationship between vitamin D and urolithiasis could have been either vitamin D overdosage or hypophosphatemic rickets with hypercalciuria. As S-Ca, S-P and U-Ca/U-cr were all normal and rickets was ruled out, these possibilities were out of question. Hematuria resolved within 3 days. As there were neither laboratory nor clinical signs of liver or bone disease, THI was considered as the most likely diagnosis. Concerning the kidney stones management, conservative approach including periodic ultrasound assessment was decided. The boy was dismissed on day 4 and checked 28 days later. At that time the S-ALP dropped to normal value of 9.2 μ kat/L. S-Ca, S-P were also normal. Therefore the patient fulfilled the criteria for THI. There were no further increases in S-ALP and the patient, who is currently 18 months old, remains stable and is periodically checked on an out-patient basis.

Our patient had a history of prematurity, and according to the hospital records, hypophosphatemia occurred throughout 3rd and 4th month of age, thus indicating history of resolved osteopathy of prematurity.