

with serum creatinine levels that remain normal. They do not present other manifestations of kidney disease, such as anaemia or hypocalcaemia. On the other hand, those who are still alive at 10 years have a mean age above the current life expectancy for women,<sup>3</sup> have been asymptomatic in terms of heart disease, and have not progressed from kidney disease to end-stage kidney disease. As a result, we consider them to be an example of *healthy* people, and yet they are diagnosed as sick based on the ORD concept.

In conclusion, our elderly patients do not have a hidden kidney disease. The ORD concept should not be used to describe a reduction of GFR in elderly women with normal serum creatinine levels.

## REFERENCES

1. Heras M, Guerrero MT, Sow A, Muñoz A, Ridruejo E, Fernández-Reyes MJ. Enfermedad renal oculta en ancianos: ¿continúa oculta a los cinco años de seguimiento? *Nefrologia*. 2015;35:340-6.

2. Heras M, Fernández-Reyes MJ, Sánchez R, Guerrero MT, Molina A, Rodríguez MA, et al. Ancianos con enfermedad renal crónica: ¿qué ocurre a los cinco años de seguimiento? *Nefrologia*. 2012;32:300-5.
3. Tablas de mortalidad de la población de España por año, sexo, edad y funciones. Available from: <http://www.ine.es> [accessed 15.9.16].

Manuel Heras<sup>a,\*</sup>, María Teresa Guerrero<sup>b</sup>,  
María José Fernández-Reyes<sup>a</sup>, Angélica Muñoz<sup>b</sup>

<sup>a</sup> Servicio de Nefrología, Hospital General de Segovia, Segovia, Spain

<sup>b</sup> Servicio de Geriátrica, Hospital General de Segovia, Segovia, Spain

\* Corresponding author.

E-mail address: [mherasb@saludcastillayleon.es](mailto:mherasb@saludcastillayleon.es) (M. Heras).

2013-2514/© 2016 Sociedad Española de Nefrología. Published by Elsevier España, S.L.U. This is an open access article under the CC BY-NC-ND license (<http://creativecommons.org/licenses/by-nc-nd/4.0/>).

# Acute kidney injury secondary to diarrhea caused by “sprue-like” enteropathy associated with olmesartan

## Daño renal agudo secundario a diarrea debido a enteropatía “sprue-like” asociada al olmesartan

Dear Editor,

Olmesartan is an angiotensin II receptor antagonist used for managing hypertension. Despite being an effective and secure drug, several reports have shown that olmesartan treatment can induce “sprue-like” enteropathy.<sup>1</sup> Histological studies of kidney tissue from patients have often shown duodenal villous atrophy, increased intraepithelial lymphocytes and collagen depositions.<sup>2</sup> The pathophysiological mechanisms causing the olmesartan-induced sprue-like enteropathy (OSLE) are not fully elucidated, but recent observations suggest a cell-mediated hypersensitivity reaction<sup>3</sup> possibly related to the haplotype DQ2/DQ8.<sup>4</sup> Persistent diarrhea often accompanies enteropathy due to olmesartan use, which could have an impact on renal function. Indeed, three previous reports have shown renal involvement secondary to diarrhea due to olmesartan-related enteropathy.<sup>5-7</sup> Here we present a series of 19 cases of enteropathy related to olmesartan. Fourteen of these patients showed acute renal failure at admission, which was reverted after rehydration and discontinuing olmesartan.

Nineteen cases (9 females; median age 70, ranging from 56 to 88 years old) of OSLE were admitted to our hospital between September 2012 and June 2016. Patients went to the

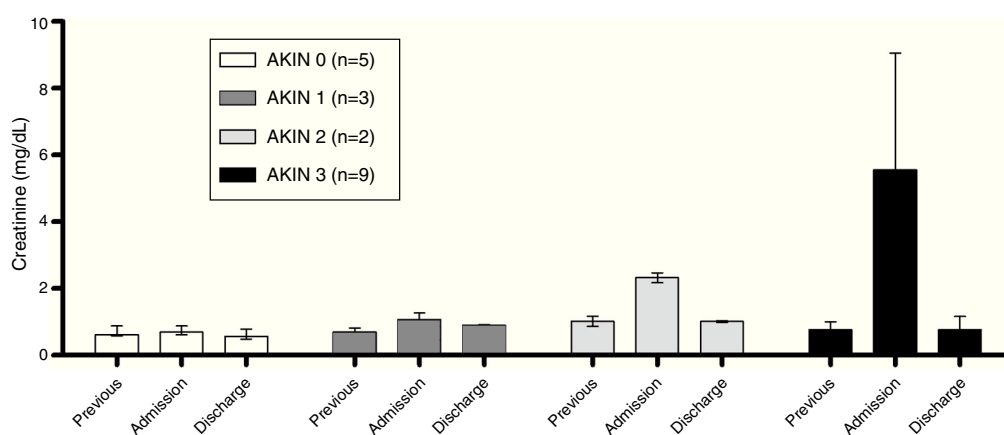
hospital due to persistent diarrhea that was non-responsive to conventional treatment. Prior to admission, patients had been treated with olmesartan for an average of 30 months (9-84 months). Most patients were taking 40 mg/day olmesartan (10-40 mg/day). OSLE was diagnosed after ruling out other possible causes for enteropathy (seronegative for tissue transglutaminase antibodies) and determining that the patient fulfilled the criteria set by Rubio et al.<sup>1</sup> Sixteen patients needed hospitalization for a time period ranging from 1 to 35 days and one was treated in the intensive care unit. Treatment consisted of rehydration therapy and olmesartan discontinuation, which reverted the enteropathy and associated diarrhea. At the time of this publication histological analyses in 12 patients showed full tissue recovery.

None of the patients had previous history of chronic renal disease, and estimated glomerular filtrate was normal prior to injury ( $86.0 \pm 17.4$  mL/min/1.73 m<sup>2</sup>). At admission, electrolyte imbalance was observed (Table 1) while serum creatinine was considerably higher in comparison to previous values (Figure 1). Acute Kidney Injury Network (AKIN) classification<sup>8</sup> showed 5 patients with no renal involvement, 3 patients at stage 1, 2 at stage 2 and 9 at stage 3. In addition, hypokalemia and metabolic acidosis was present in these patients (Table 1).

**Table 1 – Incidence of hypokalemia and serum biochemical values at hospital admission in olmesartan-related enteropathy patients classified by the Acute Kidney Injury Network (AKIN) stages.**

	AKIN=0 (n=5)	AKIN=1 (n=3)	AKIN=2 (n=2)	AKIN=3 (n=9)
Hypokalemia	2 (40%)	1 (33%)	0 (0%)	8 (89%)
Urea (mg/dL)	38.0 (57.0–30.0)	70.0 (87.0–44.0)	60.5 (78.0–43.0)	129.0 (242.0–38.0)
Cl <sup>-</sup> (mEq/L)	105.0 (107.0–102.0)	102.0 (108.0–98.0)	103.5 (104.0–103.0)	103.0 (116.0–95.0)
Na <sup>+</sup> (mEq/L)	139 (141–136)	139 (139–136)	137 (138–136)	136 (139–130)
K <sup>+</sup> (mEq/L)	4.0 (4.3–2.2)	3.6 (4.0–3.4)	4.3 (4.6–3.9)	3.3 (4.4–2.3)
pH	7.38 (7.46–7.37)	7.32 (7.32–7.32)	7.24 (7.29–7.18)	7.14 (7.29–6.98)
CO <sub>2</sub> (mEq/L)	39.4 (47.3–19.5)	49.0 (49.0–49.0)	45.1 (47.2–43.0)	13.7 (48.0–4.6)
HCO <sub>3</sub> <sup>-</sup> (mEq/L)	22.2 (27.5–16.9)	22.9 (24.7–21.0)	18.6 (20.1–17.0)	10.0 (16.0–4.5)
Hb (g/dL)	13.3 (14.5–12.1)	13.9 (14.6–10.5)	15.9 (16.6–15.2)	14.8 (18.1–12.0)

Hypokalemia (K<sup>+</sup> <3.5 mEq/L) data has been reported as count (percentage). The rest of the data is reported as median (max–min). Hb, hemoglobin.

**Figure 1 – Serum creatinine levels prior to the diarrhea episode, at admission and at discharge in 19 olmesartan-related enteropathy patients classified by the Acute Kidney Injury Network (AKIN) stages. Bar height denotes median values while error bars denote range.**

We have presented a series of cases (14 out of a total of 19) in which acute renal injury was secondary to dehydration due to OSLE. Renal involvement was severe in 11 patients (2 cases of AKIN stage 2 and 9 cases AKIN stage 3) accompanied by hypokalemia and metabolic acidosis.

The data obtained in this case series is similar to 2 cases in Spain with high creatinine and low potassium levels associated with enteropathy in patients treated with olmesartan, which reverted after drug discontinuation.<sup>5</sup> Along the same lines, another case of enteropathy related to olmesartan with high serum creatinine and hypokalemia has been reported.<sup>9</sup> Chronic enteropathy could be associated with severe dehydration and weight loss by diarrhea, which would explain the renal involvement observed in these patients.

Olmесartan is commonly used for hypertension treatment. Although it is a safe and reliable drug, the Food and Drug Administration has recommended suspending treatment if intestinal problems occur.<sup>10</sup> Our data highlight the severe effects on renal tissue due to chronic diarrhea secondary to OSLE. More than half of the patients had stage 2 or 3 AKIN, in which kidney tissue was affected. It is likely that the duration and severity of the diarrhea episodes and the patient's hydration pattern contribute to the extent of kidney injury. Rehydra-

tion therapy and suspension of olmesartan treatment reverted symptoms and renal function was normal at discharge. However, in some cases, the extent of kidney tissue damage was high, which in turn could jeopardize patients' renal function.

Besides weight loss, dehydration and other complications secondary to diarrhea, the renal involvement shown in this case series highlights the necessity of including olmesartan treatment in the differential diagnosis of chronic diarrhea in order to minimize the effects on kidney tissue and preserve patients' renal function.

#### REFERENCES

- Rubio-Tapia A, Herman ML, Ludvigsson JF, Kelly DG, Mangan TF, Wu TT, et al. Severe sprue like enteropathy associated with olmesartan. *Mayo Clin Proc.* 2012;87:732–8.
- Burbure N, Lebwohl B, Arguelles-Grande C, Green PH, Bhagat G, Lagana S. Olmesartan-associated sprue-like enteropathy: a systematic review with emphasis on histopathology. *Hum Pathol.* 2016;50:127–34.

3. Ianiro G, Bibbo S, Montalto M, Ricci R, Gasbarrini A, Cammarota G. Systematic review: sprue-like enteropathy associated with olmesartan. *Aliment Pharmacol Ther*. 2014;40:16–23.
4. DeGaetani M, Tennyson CA, Lebwohl B, Lewis SK, Abu Daya H, Arguelles-Grande C, et al. Villous atrophy and negative celiac serology: a diagnostic and therapeutic dilemma. *Am J Gastroenterol*. 2013;108:647–53.
5. Ulla-Rocha JL, Lopez-Pineiro S, Puga-Gimenez M. Acute renal failure secondary to diarrhea due to sprue like-enteropathy associated with olmesartan. *Gastroenterol Hepatol*. 2015;38:514–5.
6. van Beurden YH, Nijeboer P, Janssen J, Verbeek WH, Mulder CJ. Diarrhoea and malabsorption due to olmesartan use. *Ned Tijdschr Geneeskd*. 2014;158:A7370.
7. Koizumi T, Furuya K, Baba M, Sadaoka K, Sekiya C, Hattori A. Case report; Olmesartan associated enteropathy: a case of severe watery diarrhea with weight loss and acute renal failure. *Nihon Naika Gakkai Zasshi*. 2015;104:1167–72.
8. Mehta RL, Kellum JA, Shah SV, Molitoris BA, Ronco C, Warnock DG, et al. Acute Kidney Injury Network: report of an initiative to improve outcomes in acute kidney injury. *Crit Care*. 2007;11:R31.
9. Tellez Villajos L, Crespo Perez L, Cano Ruiz A, Moreira Vicente V. Enteropathy by olmesartan. *Med Clin (Barc)*. 2015;144:140–1.
10. FDA. Drug Safety Communication: FDA approves label changes to include intestinal problems (sprue-like

enteropathy) linked to blood pressure medicine olmesartan medoxomil. <http://www.fda.gov/Drugs/DrugSafety/ucm359477.htm>.

Lourdes Roca-Argente<sup>a</sup>, Francia-Carolina Diaz-Jaime<sup>b</sup>, Luis-Carlos López-Romero<sup>a</sup>, Yeri Manzur-Aguilar<sup>a</sup>, Jose-Luis Moll-Guillem<sup>a</sup>, Adolfo del Val-Antoñana<sup>b</sup>, Julio Hernandez-Jaras<sup>a,\*</sup>

<sup>a</sup> Servicio de Nefrología, Hospital Universitario y Politécnico La Fe, Valencia, Spain

<sup>b</sup> Unidad de Gastroenterología, Servicio de Medicina Digestiva, Hospital Universitario y Politécnico La Fe, Valencia, Spain

\* Corresponding author.

E-mail address: [Hernandez.jul@gva.es](mailto:Hernandez.jul@gva.es) (J. Hernandez-Jaras).

2013-2514/© 2016 Sociedad Española de Nefrología. Published by Elsevier España, S.L.U. This is an open access article under the CC BY-NC-ND license (<http://creativecommons.org/licenses/by-nc-nd/4.0/>).

<https://doi.org/10.1016/j.nefro.2017.02.004>

## Switch to belatacept in kidney graft recipients

### Cambio a belatacept en trasplante renal

Dear editor:

Calcineurin inhibitors (CNIs) are the gold standard immunosuppression in kidney transplant recipients. These drugs have shown better results in graft survival and patient outcome during the first year after transplantation. However, long-term use is associated with acute and chronic nephrotoxicity, which predisposes to graft loss.

Belatacept is a fusion protein binding to CD80 or CD86 ligands on antigen presenting cells that selectively blocks T-cell costimulatory signals. Data derived from two phase III trials (BENEFIT and BENEFIT-EXT) demonstrated the efficacy and safety of Belatacept in combination with Basiliximab, steroids and mycophenolic acid preventing graft acute rejection in Epstein-Barr virus positive recipients. Recently, the results of BENEFIT and BENEFIT-EXT study after 7 year follow up confirmed former data and showed a significant reduction in death and graft loss associated with the use of belatacept.<sup>1</sup>

Given the relevance of its beneficial effects in kidney function, some authors have proposed switching CNIs into belatacept treatment in intolerant patients to calcineurin or mTOR inhibitors showing an improvement in renal function.<sup>2-5</sup>

In our country, the administration of Belatacept is restricted by public health insurance. Public hospitals may use

belatacept after individualized assessment requiring specific approval by internal committees in each case.

We summarize (Table 1) our clinical experience of switching to belatacept in 5 kidney transplant recipients through 2013–2015 after failure or intolerant therapy to tacrolimus and/or everolimus. All patients were Epstein-Barr virus positive.

Pre-transplant kidney biopsies were not performed. Clinical data were compatible with suboptimal donors, predisposing to a recipient poorer renal function. After transplantation patients received immunosuppression therapy consisting of anti-lymphocyte depleting antibodies, steroids and mycophenolic acid postponing tacrolimus starting to minimize delayed graft function. In four patients (cases 2, 3, 4 and 5) renal function was not adequate in the first month post-transplant. Analysis of graft biopsy showed CNI toxicity and chronic vascular lesions (likely related with donor background), but no evidence of acute rejection. Everolimus was considered an alternative to tacrolimus in all four cases. However it was not tolerated because of proteinuria or bone pain. In case 1 the reason for graft dysfunction was a thrombotic microangiopathy (TMA) due to the sequential use of tacrolimus first and cyclosporine later. They were converted to belatacept between 2 and 8 months post-transplantation