

## Regression of vascular calcification in a patient with calciphylaxis<sup>☆</sup>

### Regresión de calcificaciones vasculares en paciente con calcifilaxia

Dear Sir,

We describe a case of calciphylaxis with severe vascular calcification (VC) in a patient with CKD, after initiation of treatment for hyperparathyroidism. The patient made satisfactory progress with healing of the lesions, but mammography revealed the return of the severe VC.

Calciphylaxis or calcific uraemic arteriopathy is a rare but significant cause of morbidity and mortality in patients with chronic kidney failure (CKF). It consists of calcification of the media layer in skin arterioles and produces very painful lesions that begin as subcutaneous nodules and progress to ischaemia and necrosis with formation of ulcers. It has been linked to multiple factors, including hyperparathyroidism, hyperphosphataemia, use of vitamin D and calcium-chelating agents, calcification-inhibitor deficiency, proteins C and S, and use of oral anticoagulants, among other causes.<sup>1,2</sup> VC is necessary but not sufficient for the disease to manifest itself clinically.<sup>3</sup>

VC and its aetiological mechanism is a subject of great interest, as it is an independent factor associated with cardiovascular mortality.<sup>4</sup> Classically, it has been thought to be an irreversible process, and the aim of nephrologists has been to prevent it or at least slow down its progression.

Our case was a 54-year-old woman with CKD secondary to extracapillary glomerulonephritis with IgA deposits since 1993. In April 2011, she was started on treatment with paricalcitol for hyperparathyroidism, being previously treated with calcium carbonate for hyperphosphataemia. The creatinine clearance (Cr) was 20 ml/m and PTH > 2000 pg/ml.

A year later, she was referred to the Advanced Chronic Kidney Disease (ACKD) clinic, where calciphylaxis was suspected due to the swollen and painful subcutaneous nodular pretibial lesions, which had developed into ulcers over the previous 5 months. Reviewing the patient's mammogram from 3 months earlier, severe linear calcifications could be seen in both breasts which were not apparent on her previous mammogram from 2008. Likewise she presented VC in other areas.

Kidney function had deteriorated (Cr 5.37, Cr clearance with 24 h urine of 12.3 ml/m with PTH > 2000 pg/ml, calcium [Ca] 9.2 mg/dl and phosphorus [P] 6.2 mg/dl) and it was decided to start haemodialysis and discontinue paricalcitol and calcium containing phosphate binders. She was started on cinacalcet, sevelamer, sodium thiosulfate (ST), antibiotics and opiates, and parathyroidectomy was scheduled. We decided not to take any biopsies due to the risk of infection of the lesions.<sup>5</sup>

Presently there is no standard therapy for calciphylaxis. Parathyroidectomy may be indicated, but does not always change the prognosis. Cinacalcet and bisphosphonates have demonstrated benefits, generally in combination with other treatments. Hyperbaric oxygen can also improve tissue hypoxia. ST has been associated with a rapid improvement in the pain and resolution of the ischaemic ulcers thanks to its antioxidant properties and it may also facilitate the elimination of vascular deposits of Ca.<sup>6</sup>

In our case, parathyroidectomy was performed a month later, with the development of hungry bone syndrome and the need for intravenous Ca and calcitriol supplementation for hypocalcaemia. After 5 months of treatment with ST and local wound care with silver patches, the ulcers healed (Fig 1).

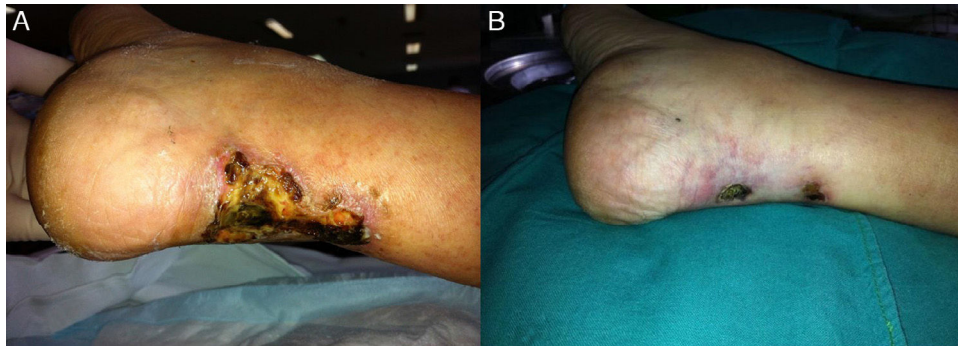Since then, the patient's Ca levels have persistently remained below 8 mg/dl, even with oral calcitriol supplementation at low doses during the first year after parathyroidectomy. Control of serum phosphate has been difficult. Three or more chelating agents: sevelamer, lanthanum and calcium acetate at full doses and, on occasion, aluminium based chelating agents have been required, despite having instructed the patient on how to take the chelating agents correctly and advise on foods with a better P/protein ratio. She has been on online post-dilution HDF with a minimum duration of 4 h with good efficiency, with Kt/V and infusion volume within current recommendations.

Initially, our aim was to prevent the death associated with calciphylaxis, but also we set a longer-term goal, which was to prevent the progression of the VC. As can be seen on

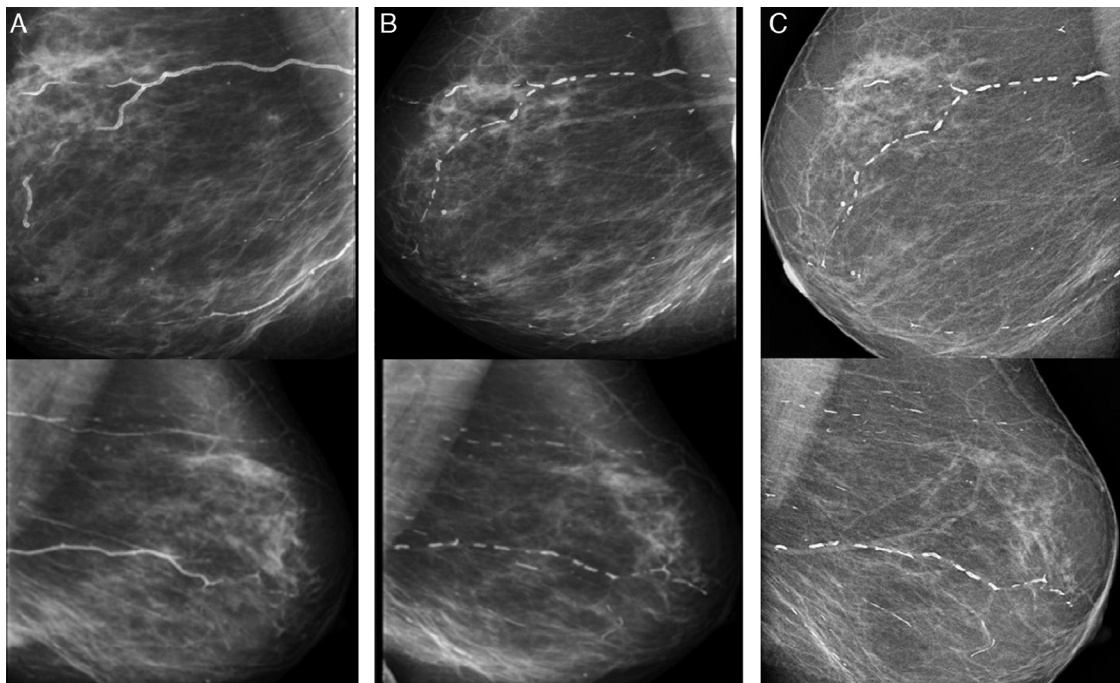
DOI of original article:

<http://dx.doi.org/10.1016/j.nefro.2016.03.015>.

<sup>☆</sup> Please cite this article as: Ruiz-Calero RM, Azevedo LM, Bayo MA, Gonzales B, Cubero JJ. Regresión de calcificaciones vasculares en paciente con calcifilaxia. Nefrología. 2016;36:569-571.



**Fig. 1** – Healing of calciphylaxis lesions after parathyroidectomy. At the beginning (A) and after 2 months (B) of treatment with ST.



**Fig. 2** – Right (above) and left (below) mammograms in 2011 (A), in 2013 (B) and in 2015 (C).

the mammograms, the change was remarkable, with striking regression of the calcifications which is sustained at present (Fig. 2).

We do not know which one of the various therapeutic actions applied brought about the regression of the severe VC presented at the start of haemodialysis. Correction of the hyperparathyroidism and discontinuation of vitamin D therapy, both of which could have been trigger factors, were probably decisive in the initial management. Starting haemodialysis and the treatment with ST also played an important role in the good calciphylaxis outcome. Control of P and Ca over the longer term are factors that we must not be complacent about.

As a general conclusion, we would emphasise the multifactorial approach in the treatment of calciphylaxis, without forgetting that, in terms of VC, the most important aspect is prevention: control of mineral metabolism; judicious use of vitamin D; and knowledge of precipitating factors in susceptible patients.

#### REFERENCES

1. Selye H, Gabbiani G, Strebel R. Sensitization to calciphylaxis by endogenous parathyroid hormone. *Endocrinology*. 1962;71:554-8.
2. Llach F. The evolving pattern of calciphylaxis: therapeutic considerations. *Nephrol Dial Transplant*. 2001;16:448-51.
3. Fernández E. La arteriopatía calcificante urémica (calcifilaxis) en el contexto del síndrome metabólico y la diabetes mellitus. *Perspectiva actual. Nefrología*. 2008;28:20-4.
4. Cozzolino M, Mazzaferro S, Pugliese F, Brancaccio D. Vascular calcification and uremia what do we know? *Am J Nephrol*. 2007;28:339-46.
5. Marron B, Coronel F, López-Bran, Barrientos A. Calcifilaxis: una patología incierta y un tratamiento controvertido. *Nefrología*. 2001;21:596-600.
6. Sood AR, Wazny LD, Raymond CB, Leung K, Komenda P. Sodium thiosulfate-based treatment in calcific uremic arteriopathy: a consecutive case series. *Clin Nephrol*. 2011;75:8-15.

Rosa M. Ruiz-Calero\*, Lilia M. Azevedo, Miguel A. Bayo, Boris Gonzales, Juan J. Cubero

Servicio de Nefrología, Hospital Infanta Cristina, Badajoz, Spain

\* Corresponding author.

E-mail addresses: [rosruizca@yahoo.com](mailto:rosruizca@yahoo.com), [rosruizca@gmail.com](mailto:rosruizca@gmail.com) (R.M. Ruiz-Calero).

2013-2514/© 2016 Sociedad Española de Nefrología. Published by Elsevier España, S.L.U. This is an open access article under the CC BY-NC-ND license (<http://creativecommons.org/licenses/by-nc-nd/4.0/>). <http://dx.doi.org/10.1016/j.nefro.2016.10.008>

## Amyloid angiopathy in the context of hemodialysis: An unknown field

### Angiopatía amiloide en el contexto de hemodiálisis: un terreno desconocido

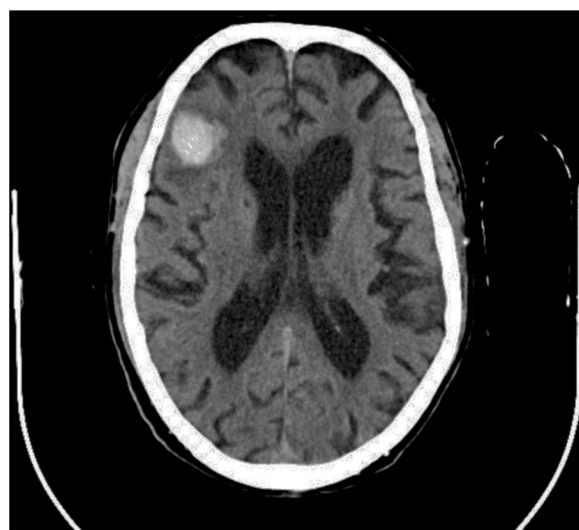Dear Editor:

It is known that cerebral amyloid angiopathy (CAA) is due to amyloid beta peptide ( $A\beta$ ) accumulation in the middle and outer coats of small cerebral arteries and arterioles. CAA irrupts as an intracranial hemorrhage, which can be a cerebral hematoma or multifocal microhemorrhages. It is difficult to estimate its real incidence because diagnosis confirmation requires an anatomopathological study, but it is rated that almost 57% of non-traumatic intracranial hemorrhages in patients between 71 and 80 years old might be caused by CAA.<sup>1</sup> The spectrum of disease due to  $A\beta$  includes several disorders. In 1985,  $\beta_2$  microglobulin was identified as the responsible of hemodialysis-associated amyloidosis.<sup>2</sup> In the 1980 decade, CAA was considered an Alzheimer's disease subtype,<sup>3,4</sup> and they have been proposed as different conditions since the 1990 early decade.<sup>5</sup> Therefore, CAA is a disease with its own entity, but it lacks diagnosis, prevention and treatment protocols.

There is evidence that uremic environment and glomerular filtration rate decline in patients with chronic kidney disease, aggravate cognitive functions and are related to microhemorrhages occurrence.<sup>6</sup> Both, it is necessary to clarify to what extent anticoagulant or antiplatelet treatments worsen CAA evolution. In this regard, it is interesting the case of an 82 years old patient with chronic kidney disease and hemodialysis for four years, who was evaluated due to a 48 hours disorientation state. His antecedents included memory impairment for nine years and an episode of multiple microangiopathic infarcts eight years ago. Non-contrast head CT showed a right frontal hematoma with perilesional edema, and hypodense lesions located in periventricular and subcortical white matter and left cerebellar hemisphere. That supported former infarcts or hemorrhages. According to the Boston criteria,<sup>7</sup> the patient diagnosis was probable CAA.

The deficiency of standardized strategies to detect CAA and the bleeding risk that the disease entails, complicate

the management of concomitant pathologies with antithrombotic therapy requirement. This is particularly important in patients under hemodialysis, who need anticoagulation treatment during sessions. In regard to antiplatelet treatment, retrospective researches show different outcomes respecting bleeding risk,<sup>8</sup> although acetylsalicylic acid is generally avoided and replaced by clopidogrel. Anticoagulation with heparin is also controversial. On the one hand, a case report of CAA-related inflammation treated with enoxaparin 4000 IU/12 h due to venous thrombosis, described a subsequent big cerebral hematoma which caused death.<sup>9</sup> On the other hand, low-molecular-weight heparin (LMWH) is recommended despite cerebral hemorrhage if immobilization extends beyond 3-4 days.<sup>10</sup> In the exposed case of



**Fig. 1** – Non-contrast head CT along hospitalization (September 2015).