

carnitine 50 mg/kg/day, biotin 10 mg daily and low protein diet was started for the patient. His blood pressure was refractory to all of anti-hypertensive drugs such as Hydralazine, Captopril, Labetalol. Methylmalonic aciduria confirmed by increased of urine methylmalonic acid and serum propionyl carnitine. Despite early treatment of methylmalonic acid even without waiting for tests result, the patient died.

Chronic renal disease is a life-threatening complication of MMA and finally leads to dialysis or kidney transplantation. Renal impairment most occurs in patients with mut (0) and cblB mutation.⁵ The mechanism of renal injury in MMA is still unknown. Proximal tubular disorder is a main pathogenic mechanism of MMA-associated kidney disease.⁶ A recent case study has reported 2 cases of MMA associated with hemolytic uremic syndrome (HUS) association which revealed that probable pathogenesis of thrombotic microangiopathy could be related to the increase of plasma methylmalonic acid and homocysteine levels.⁷

In the current study, the two mentioned patients had MMA that confirmed with assessment of urine organic acid and acylcarnitine profile. They had just renal involvement that their symptom and signs were started during infancy that was refractory to all of the treatment and despite early treatment in the one of them, they died.

In summary, in each case with hematuria, proteinuria, nephrotic syndrome, unexplained hypertension or renal failure of unknown origin especially in pediatric patients, metabolic screening and urinary organic acid analysis should be carried out as soon as possible.

REFERENCES

1. Walter JH, Michalski A, Wilson WM, Leonard JV, Barratt TM, Dillon MJ. Chronic renal failure in methylmalonic acidemia. *Eur J Pediatr.* 1989;148:344-8.
2. Matsui SM, Mahoney MJ, Rosenberg LE. The natural history of the inherited methylmalonic acidemias. *N Engl J Med.* 1983;308:857-61.
3. Nicolaides P, Leonard J, Surtees R. Neurological outcome of methylmalonic acidemia. *Arch Dis Child.* 1998;78:508-12.
4. Baumgartner MR, Horster F, Dionisi-Vici C, Haliloglu G, Karall D, Chapman KA, et al. Proposed guidelines for the diagnosis and management of methylmalonic and propionic acidemia. *Orphanet J Rare Dis.* 2014;9:130.
5. Horster F, Baumgartner MR, Viardot C, Suormala T, Burgard P, Fowler B, et al. Long-term outcome in methylmalonic acidurias is influenced by the underlying defect (mut0, mut-, cblA, cblB). *Pediatr Res.* 2007;62:225-30.
6. Manoli I, Sysol JR, Li L, Houillier P, Garone C, Wang C, et al. Targeting proximal tubule mitochondrial dysfunction attenuates the renal disease of methylmalonic acidemia. *Proc Natl Acad Sci U S A.* 2013;110:13552-7.
7. Mesa-Medina O, Ruiz-Pons M, Garcia-Nieto V, Leon-Gonzalez J, Lopez-Mendoza S, Solis-Reyes C. Methylmalonic acidemia with homocystinuria. A very rare cause of kidney failure in the neonatal period. *Nefrologia.* 2014;34:539-40.

Bahareh Yaghmaei^a, Parastoo Rostami^{a,*},
Farnaz Najmi Varzaneh^{b,c}, Behdad Gharib^a,
Behnaz Bazargani^a, Nima Rezaei^{b,c,d}

^a Department of Pediatrics, Children's Medical Center, Tehran University of Medical Sciences, Tehran, Iran

^b Research Center for Immunodeficiencies, Children's Medical Center, Tehran, Iran

^c Department of Immunology, School of Medicine, Tehran University of Medical Sciences, Tehran, Iran

^d Universal Scientific Education and Research Network (USERN), Tehran, Iran

* Corresponding author.

E-mail address: drp_rostami@yahoo.com (P. Rostami).

2013-2514/© 2015 Published by Elsevier España, S.L.U. on behalf of Sociedad Española de Nefrología. This is an open access article under the CC BY-NC-ND license (<http://creativecommons.org/licenses/by-nc-nd/4.0/>). <http://dx.doi.org/10.1016/j.nefro.2015.08.005>

Necrotizing glomerulonephritis in levamisole-contaminated cocaine use[☆]

Glomerulonefritis necrosante en el síndrome por consumo de cocaína y levamisol

Dear Editor,

Spain is the country with the greatest incidence of cocaine use in adults,^{1,2} and consignments of levamisole-contaminated cocaine has increased in the last decade.^{2,3} Regarding the

use of cocaine/levamisole (C/L), a syndrome distinguished by the following has been reported: (1) purpuric, necrotic or ecchymotic skin lesions on the trunk, limbs and earlobes; the histological background is leukocytoclastic vasculitis or thrombotic vasculopathy; (2) leukopenia and neutropenia, and

[☆] Please cite this article as: Sirvent AE, Enríquez R, Andrada E, Sánchez M, Millán I, González C. Glomerulonefritis necrosante en el síndrome por consumo de cocaína y levamisol. *Nefrologia.* 2016;36:76-78.

Table 1 – Clinical and serological characteristics of cocaine/levamisole use syndrome.**Skin impairment^a:**

Retiform purpura and skin necrosis (PS: leukocytoclastic vasculitis or thrombotic microangiopathy)
 Typical location on earlobes and pinnae. Also on limbs, trunk and flanks

Musculoskeletal impairment: arthralgia^a and/or arthritis^a; myalgia

Leukopenia, neutropenia and/or agranulocytosis

Serological abnormality: joint presence of multiple autoantibodies:

Double positivity for ANCA; discordance between pattern of immunofluorescence and antibodies by ELISA; atypical ANCA: ACLs, LA, ANAs, anti-DNA antibodies, hypocomplementaemia

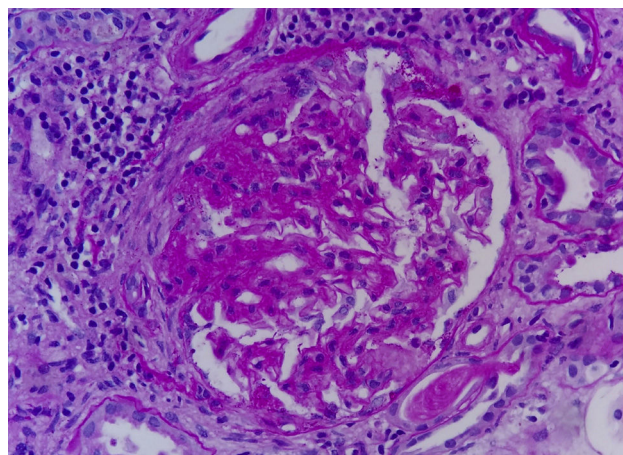
ACLs: anticardiolipin antibodies; LA: lupus anticoagulant; PS: pathology study.

^a According to the series, these may be the most common manifestations.

(3) positivity for different immune parameters^{2,3} (Table 1). Kidney disease due to C/L is found to be scarcely documented.

We describe the case of a patient who developed necrotizing glomerulonephritis, with kidney failure and nephrotic syndrome, associated with C/L use. To our knowledge, this would be the first publication with kidney biopsy in Spain.

The patient was a 47-year-old male referred for kidney failure and nephrotic syndrome evaluation. Two years earlier, he had had self-limited skin lesions on his right flank and his earlobes, and analyses confirmed neutropenia and positivity for ANAs and ANCA (MPO and PR3). In the current admission he reported nocturia for the last few months, choluria, intermittent oedema and arthralgia in the left shoulder, elbow and knee. He denied the use of tobacco, toxins or any medicine. Physical examination: afebrile, with a blood pressure of 120/70 mmHg and all other parameters within normal limits. Laboratory test: haemoglobin 9.2 g/dl, leukocytes 3190 μ l (neutrophils 54.6%), platelets 248,000 μ l, prolonged APTT (41.7 min), Cr 2.66 mg/dl, albumin 2.9 g/dl, triglycerides 336 mg/dl, cholesterol 207 mg/dl, CK 167 U/l; rheumatoid factor, C3–C4, serum electrophoresis and thyroid hormones negative/normal. Antinuclear antibodies positive at 1/160, anti-DNA antibodies negative, lupus anticoagulant positive, IgG anticardiolipin antibodies negative, IgM 18.8 MPL/ml (positive > 18 MPL/ml), cryoglobulins negative, c-ANCA negative, p-ANCA positive, MPO 17 IU/ml (positive > 10), PR3 35 IU/ml (positive > 3). HLA-B27 negative. Serology for hepatitis B, hepatitis C and HIV viruses negative; previous exposure to cytomegalovirus, Epstein–Barr virus and parvovirus B19. Chest X-ray, echocardiogram and abdominal–pelvic CAT scan with no significant findings. Determination of toxins in urine was positive for cocaine. Sediment with 60–100 erythrocytes per field with 20%–30% dysmorphic, 6–12 leukocytes per field, culture negative, proteinuria 7680 mg/24 h with a non-selective glomerular pattern. The patient was questioned again and admitted to use of inhaled cocaine in the previous months. The kidney biopsy comprised 27 glomeruli: 3 with ischaemic changes, one with a fibrous crescent and the rest with segmental capillary tuft necrosis (Fig. 1); immunofluorescence was not significant. Methylprednisolone (1.5 g IV), cyclophosphamide (750 mg IV) and oral prednisone 60 mg/day were administered

**Fig. 1 – Glomerulus with segmental fibrinoid necrosis and fibrous half-moon (SBP \times 40).**

in a decreasing regimen. After one month, serum creatinine level was 1.31 mg/dl.

The percentage of cocaine samples contaminated with levamisole was 80% in the United States in 2011,² and 48% in Spain between August and December 2009.⁴ It seems that cocaine is cut with levamisole because levamisole is a cheap powder with organoleptic characteristics similar to those of cocaine, and would increase cocaine's dopaminergic and sympathomimetic effects.^{1,5}

Levamisole is an anthelmintic agent that was used as an immunomodulator in humans until 2000. It promotes immune manifestations through various mechanisms: (1) it facilitates the actions of macrophages, B lymphocytes and T lymphocytes, and neutrophil chemotaxis; (2) it would alter immune tolerance and (3) it has direct toxicity on neutrophils and endothelial cells.^{1,6} Cocaine in itself also may cause immune phenomena; therefore, it is possible for cocaine and levamisole to enhance each other. A jumbled or discordant immune pattern may be a key to diagnosis.¹ ANCA, ANAs, lupus anticoagulant and IgM anticardiolipin antibodies have been described; the presence of anti-DNA antibodies and hypocomplementaemia is rarer.^{1,3,6,7} Regarding ANCA, positivity for both MPO and PR3 may be seen. Discordance between the pattern by immunofluorescence and ELISA may also be seen,^{1,6} and indeed was observed in this case.

Levamisole is difficult to detect in urine due to its short half-life²; however, demonstrated cocaine use plus characteristic clinical and laboratory abnormalities are sufficient to diagnose C/L syndrome.³

According to the series, both skin and/or joint manifestations (arthritis or arthralgia), which were present in our patient, are very common. Neutropenia is also common. A genetic susceptibility due to positivity for the HLA-B27 antigen has been shown in certain cases.^{1,3} Neutropenia tends to improve upon suspending drug use.² Kidney manifestations due to C/L are asymptomatic urinary abnormalities, nephrotic syndrome and acute kidney failure.^{5,7,8} Although biopsied cases are few in number, pauci-immune extracapillary necrotizing glomerulonephritis is the most common histological pattern,⁶⁻⁹ and may or may not be accompanied by pulmonary

haemorrhage.⁸ Abstention from C/L is the mainstay of treatment and, in addition, various immunosuppressants have been used.^{8,9} The patient's clinical course is not always good, and he or she may require maintenance dialysis.⁸

It would be appropriate to alert medical professionals to the onset of C/L use syndrome, above all in the presence of neutropenia and multiple autoimmune phenomena. Given that cocaine use is illegal and patients tend to deny it, it is important to maintain a high degree of clinical suspicion to reach a diagnosis.

REFERENCES

1. Khan TA, Cuchacovich R, Espinoza LR, Lata S, Patel NJ, García-Valladares I, et al. Vasculopathy, hematological, and immune abnormalities associated with levamisole-contaminated cocaine use. *Semin Arthritis Rheum.* 2011;41:445-54.
2. Espinoza LR, Pérez Alamino R. Cocaine-induced vasculitis: clinical and immunological spectrum. *Curr Rheumatol Rep.* 2012;14:532-8.
3. Gross RL, Brucker J, Bahce-Altuntas A, Abadi MA, Lipoff J, Kotlyar D, et al. A novel cutaneous vasculitis syndrome induced by levamisole-contaminated cocaine. *Clin Rheumatol.* 2011;30:1385-92.
4. Ventura Vilamala M, Caudevilla Gáligo F, Vidal Giné C, Grupo de Investigadores SELECTO. Cocaína adulterada con Levamisol: posibles implicaciones clínicas. *Med Clin (Barc).* 2011;136:365-8.
5. Álvarez Díaz H, Mariño Callejo AI, García Rodríguez JF, Rodríguez Pazos L, Gómez Buena I, Bermejo Barrera AM. ANCA-positive vasculitis induced by levamisole-adulterated

- cocaine and nephrotic syndrome: the kidney as an unusual target. *Am J Case Rep.* 2013;14:557-61.
6. Graf J. Rheumatic manifestations of cocaine use. *Curr Opin Rheumatol.* 2013;25:50-5.
7. McGrath MM, Isakova T, Rennke HG, Mottola AM, Laliberte KA, Niles JL. Contaminated cocaine and antineutrophil cytoplasmic antibody-associated disease. *Clin J Am Soc Nephrol.* 2011;6:2799-805.
8. Carlson AQ, Tuot DS, Jen KY, Butcher B, Graf J, Sam R, et al. Pauci-immune glomerulonephritis in individuals with disease associated with levamisole-adulterated cocaine: a series of 4 cases. *Medicine (Baltimore).* 2014;93:290-7.
9. Gulati S, Donato AA. Lupus anticoagulant and ANCA associated thrombotic vasculopathy due to cocaine contaminated with levamisole: a case report and review of the literature. *J Thromb Thromb.* 2012;34:7-10.

Ana Esther Sirvent^{a,*}, Ricardo Enríquez^a, Encarnación Andrada^b, María Sánchez^a, Isabel Millán^a, César González^a

^a Servicio de Nefrología, Hospital General Universitario de Elche, Elche, Alicante, Spain

^b Servicio de Anatomía Patológica, Hospital General Universitario de Elche, Elche, Alicante, Spain

* Corresponding author.

E-mail address: nefro.elx@gva.es (A.E. Sirvent).

2013-2514/© 2015 Sociedad Española de Nefrología. Published by Elsevier España, S.L.U. This is an open access article under the CC BY-NC-ND license (<http://creativecommons.org/licenses/by-nc-nd/4.0/>). <http://dx.doi.org/10.1016/j.nefro.2016.03.003>

Microscopic polyangiitis in a patient with primary biliary cirrhosis: Treatment complications[☆]

Poliangeítis microscópica en paciente con cirrosis biliar primaria. Complicaciones del tratamiento

Dear Editor,

A 70-year-old woman with a prior history of primary biliary cirrhosis diagnosed 18 months earlier, being treated with ursodeoxycholic acid 600 mg/day. No prior history of hypertension or diabetes mellitus. No known kidney diseases. Admitted to the nephrology department owing to acute renal function deterioration (creatinine: 4.12 mg/dl; urea: 122 mg/dl).

Reported wasting syndrome, over a period of several months. Diuresis was maintained, and vital signs (blood pressure [BP]: 125/75 mmHg) and physical examination were normal.

Findings included normocytic normochromic anaemia (Hb 10.3 g/dl), which required initiation of erythropoietin treatment. Proteinuria of 0.840 g/day with granular casts in the sediment, and ++++ microhaematuria. She tested positive for p-ANCAs at a titre of 29.1 IU/ml. She also tested positive

[☆] Please cite this article as: Ruiz-Ferreras E, Martín-Arribas A, Tabernero-Fernández G, Lerma-Márquez JL, Fraile-Gómez P, García-Cosmes P, et al. Poliangeítis microscópica en paciente con cirrosis biliar primaria. Complicaciones del tratamiento. *Nefrología.* 2016;36:78-80.