

It is not uncommon to find a combination of several autoimmune diseases in a single patient, given their common background. In our case, MPA was diagnosed in a patient with a prior history of primary biliary cirrhosis, even though there are few references in the literature of cases in which these two diseases are combined.<sup>5-7</sup>

#### REFERENCES

1. Ernst E, Girndt M, Pliquett RU. A case of granulomatosis with polyangiitis complicated by cyclophosphamide toxicity and opportunistic infections: choosing between Scylla and Charybdis. *BMC Nephrol.* 2014;15:28.
2. Yamazaki M, Takei T, Otsubo S, Iwasa Y, Yabuki Y, Suzuki K, et al. Wegener's granulomatosis complicated by intestinal ulcer due to cytomegalovirus infection and by thrombotic thrombocytopenic purpura. *Intern Med.* 2007;46:1435-40.
3. Wakura D, Yoneda M, Kotani T, Egashira Y, Nagai K, Shoda T, et al. A refractory case of MPO-ANCA-associated vasculitis presented with gastrointestinal ulcer, rapidly progressive glomerular nephritis and pulmonary multiple nodules. *Nihon Rinsho Meneki Gakkai Kaishi.* 2010;33:31-6 [Article in Japanese]. Erratum in: *Nihon Rinsho Meneki Gakkai Kaishi* 2010;33:117. Wakaura, Daisuke [corrected to Wakura, Daisuke].
4. Pagnoux C, Mahr A, Cohen P, Guillevin L. Presentation and outcome of gastrointestinal involvement in systemic necrotizing vasculitides: analysis of 62 patients with polyarteritis nodosa, microscopic polyangiitis, Wegener granulomatosis, Churg-Strauss syndrome, or rheumatoid

arthritis-associated vasculitis. *Medicine (Baltim).* 2005;84:115-28.

5. Amezcua-Guerra LM, Prieto P, Bojalil R, Pineda C, Amigo MC. Microscopic polyangiitis associated with primary biliary cirrhosis: a causal or casual association? *J Rheumatol.* 2006;33:2351-3.
6. Iannone F, Falappone P, Pannarale G, Gentile A, Grattagliano V, Covelli M, et al. Microscopic polyangiitis associated with primary biliary cirrhosis. *J Rheumatol.* 2003;30:2710-2.
7. Nakamura T, Kawagoe Y, Ueda Y, Koide H. Antineutrophil cytoplasmic autoantibody associated rapidly progressive glomerulonephritis in a patient with primary biliary cirrhosis. *Am J Med Sci.* 2004;328:176-9.

Elena Ruiz-Ferreras\*, Alberto Martín-Arribas, Guadalupe Taberbero-Fernández, José Luis Lerma-Márquez, Pilar Fraile-Gómez, Pedro García-Cosmes, José Matías Taberbero-Romo

*Servicio de Nefrología, Hospital Universitario de Salamanca, Salamanca, Spain*

\* Corresponding author.

E-mail address: [eruiburg@hotmail.com](mailto:eruiburg@hotmail.com) (E. Ruiz-Ferreras).

2013-2514/© 2015 Sociedad Española de Nefrología. Published by Elsevier España, S.L.U. This is an open access article under the CC BY-NC-ND license (<http://creativecommons.org/licenses/by-nc-nd/4.0/>). <http://dx.doi.org/10.1016/j.nefro.2016.03.002>

## An uncommon cause of spontaneous hemoperitoneum in a peritoneal dialysis patient<sup>☆</sup>

### Una causa infrecuente de hemoperitoneo espontáneo en un paciente en diálisis peritoneal

To the Editor,

We present the case of a 64-year-old woman with multiple allergies, poorly-controlled hypertension, frequent headaches being followed by the neurology department, duodenal ulcer with a partial gastrectomy performed more than 20 years ago, and chronic kidney disease (CKD) secondary to IgA nephropathy. She began haemodialysis in May 2004. In November 2004, she received a cadaveric renal transplant; due to recurrence of underlying disease there was a progressive deterioration in renal function. In October 2010 she re-started a dialysis programme in the form of automated peritoneal dialysis (APD).

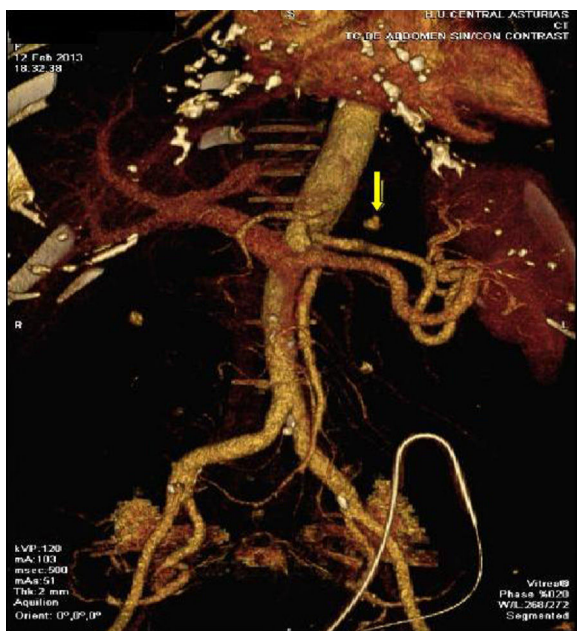
The patient presented to the emergency department after few hours of sudden-onset epigastric pain, radiating to the

back, and with associated nausea. A peritoneal exchange was performed, in which significant haemoperitoneum was observed. It was therefore decided to perform further test to investigate the cause of haemoperitoneum.

Blood tests showed a Hb of 9.4 g/dL, leukocytes of 11 400/ $\mu$ l, normal platelet count, urea of 133 mg/dL, creatinine of 9.95 mg/dL, and sodium and potassium within normal range. There were no coagulation abnormalities. In the peritoneal fluid analysis, the red cell count was 135 000/ $\text{mm}^3$  and leukocytes were 369/ $\text{mm}^3$  (79.9% PMNs).

Following review of all the findings, it was decided to perform axial computed tomography (CT) with contrast. This revealed the presence of a hyperdense nodule in the posterior region of the gastric fundus compatible with pseudoaneurysm

<sup>☆</sup> Please cite this article as: Hidalgo-Ordoñez C, Sánchez-Alvarez E, Rodríguez-Suárez C. Una causa infrecuente de hemoperitoneo espontáneo en un paciente en diálisis peritoneal. *Nefrología.* 2016;36:80-81.



**Fig. 1** – CT imaging of a hyperdense nodule in the posterior region of the gastric fundus, compatible with pseudoaneurysm of the left gastric artery, with an underlying haematoma.

of the left gastric artery, with an underlying haematoma (Fig. 1). Percutaneous transcatheter embolization of the pseudoaneurysm was performed with the use of coils, with satisfactory control of bleeding as per angiography (Fig. 2).

The patient was subsequently admitted for haemodynamic monitoring; patient had an inguinal haematoma as a complication of the procedure and, required the transfusion of 2 units packed red cells.

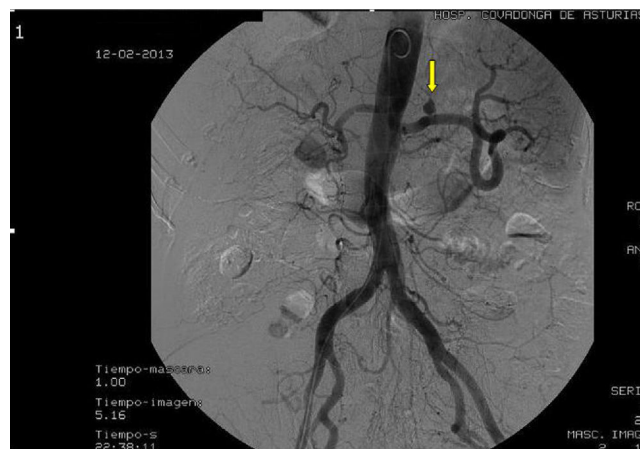
She was kept on peritoneal rest, with frequent peritoneal lavage until peritoneal fluid became clear. During this time, haemodialysis was performed via a temporary jugular venous catheter.

She had a low-grade fever related to the haematoma, with negative blood cultures. After one week the patient re-started peritoneal exchanges with no signs of bleeding in the peritoneal fluid. She has had no further complications since this episode.

Haemoperitoneum is an uncommon complication of peritoneal dialysis, and can vary from minimal bleeding to frank haemorrhage causing shock.<sup>1-3</sup> The most common cause of bleeding is related to menstruation or ovulation. Less common causes include sclerosing peritonitis, pseudoaneurysm of the splenic artery, polycystic kidneys, laceration of an abdominal organ, acute pancreatitis, and coagulation abnormalities.<sup>4</sup>

Our patient presented to the emergency department with epigastric pain of sudden onset. The bloody peritoneal fluid gave us a clue as to the cause of the pain, which led to a CT. With percutaneous embolization, the bleeding was stopped.

Peritoneal dialysis is an established renal replacement therapy technique, but among its advantages is the rarely-mentioned possibility of early detection of abdominal bleeding, revealing blood loss that would otherwise go unnoticed.<sup>5</sup> In other cases, previously reported, immediate angiography and percutaneous transcatheter embolization



**Fig. 2** – Angiography after percutaneous transcatheter embolization of the pseudoaneurysm.

helped to control bleeding and avoid laparotomy.<sup>1</sup> In our case, due to the peritoneal dialysis technique, we were able to suspect the cause of epigastric pain and treat it appropriately.

## Conflicts of interest

The authors declare no conflicts of interest.

## REFERENCES

1. Macía M, Pulido-Duque JM, Hortal L, Vega N, García-Medina J, Ortiz E, et al. Percutaneous embolization of splenic artery pseudoaneurysm as a treatment of hemoperitoneum in a CAPD patient. *Perit Dial Int.* 1993;13:157-9.
2. Borràs M, Valdivielso JM, Egidio R, Vicente de Vera P, Bordalba JR, Fernández E. Haemoperitoneum caused by bilateral renal cyst rupture in an ACKD peritoneal dialysis patient. *Nephrol Dial Transplant.* 2006;21:789-91.
3. Fine A, Novak C. Hemoperitoneum due to carcinomatosis in the liver of a CAPD patient. *Perit Dial Int.* 1996;16:181-3.
4. Peng SJ, Yang CS. Hemoperitoneum in CAPD patients with hepatic tumors. *Perit Dial Int.* 1996;16:84-6.
5. Kanagasundaram NS, Macdougall IC, Turney JH. Massive haemoperitoneum due to rupture of splenic infarct during CAPD. *Nephrol Dial Transplant.* 1998;13:2380-1.

Carlos Hidalgo-Ordoñez, Emilio Sánchez-Alvarez\*, Carmen Rodríguez-Suárez

Unidad de Gestión Clínica de Nefrología, Hospital Universitario Central de Asturias, Oviedo, Asturias, Spain

\*Corresponding author.

E-mail addresses: [jesastur@hotmail.com](mailto:jesastur@hotmail.com), [carmen.diazc@sespa.es](mailto:carmen.diazc@sespa.es) (E. Sánchez-Alvarez).

2013-2514/© 2015 Sociedad Española de Nefrología. Published by Elsevier España, S.L.U. This is an open access article under the CC BY-NC-ND license (<http://creativecommons.org/licenses/by-nc-nd/4.0/>). <http://dx.doi.org/10.1016/j.nefro.2016.03.001>