

## REFERENCES

1. Wen YK, Chen ML. The spectrum of acute renal failure in IgA nephropathy. *Ren Fail.* 2010;32:428-33.
2. Castellano I, Covarsi A, Novillo R, GómezMartino JR, Ferrando L. Lesiones histológicas renales en pacientes con diabetes mellitus tipo II. *Nefrologia.* 2002;22:162-9.
3. Yoshikawa Y, Truong LD, Mattioli CA, Ordonez NG, Balsaver AM. Membranous glomerulonephritis in diabetic patients: a study of 15 cases and review of the literature. *Mod Pathol.* 1990;3:36-42.
4. Hory B, Chaillet R, Pérol C. Chronic terminal renal failure: an unusual outcome of acute tubulointerstitial nephritis. *Nephrologie.* 1987;8:237-41.
5. González E, Gutiérrez E, Galeano C, Chevia C, de Sequera P, Bernis C, Grupo Madrileño de Nefritis Intersticiales. Early steroid treatment improves renal function recovery in patients with drug-induced acute interstitial nephritis. *Kidney Int.* 2008;73:940-6.

## ***Mycobacterium fortuitum* as a cause of peritoneal dialysis catheter port infection. A clinical case and a review of the literature** ☆

### ***Mycobacterium fortuitum* como causa de infección del orificio del catéter de diálisis peritoneal. Caso clínico y revisión de la literatura**

Dear Editor,

Catheter-related infections are a common and clinically relevant in peritoneal dialysis patients. Exit-site infections are characterized by the presence of purulent discharge, with or without local. The most common pathogens are *Staphylococcus* and Gram-negative bacteria; however, rapidly growing atypical mycobacteria (RGAM) are rare.

Here we describe a paediatric patient with a *Mycobacterium fortuitum* peritoneal catheter exit-site infection together with literature review.

He is a 4-year-old boy with a 4-month history of continuous ambulatory peritoneal dialysis (CAPD). He complained of erythema in the peritoneal catheter exit site, with mild discharge and no improvement following 7 days of treatment with topical mupirocin. After sampling for exudate culture, topical therapy with ciprofloxacin was initiated. Six days later the erythema was still present and the patient developed a chocolate-coloured discharge and a granuloma was observed (Fig. 1). The patient was asymptomatic with no fever. Blood chemistry did not show an increase in acute-phase reactants, and cytochemistry of peritoneal fluid was normal. Previous culture was positive for RGAM. Intraperitoneal ciprofloxacin and amikacin were initiated, together local care of the exist site with Betadine®. The *Mycobacteria* was subsequently classified as *Mycobacterium fortuitum* sensitive to both antibiotics, ciprofloxacin and amikacin. Treatment was continued for 8

weeks and culture became negative, with low improvement of the exit site appearance (Fig. 1). Thus, it was decided to replace the Tenckhoff catheter, despite no evidence of peritonitis. The patient continued under CAPD with no acceptable ultrafiltration. The patient was naïve to systemic antibiotics and had no history of previous infections before this episode.

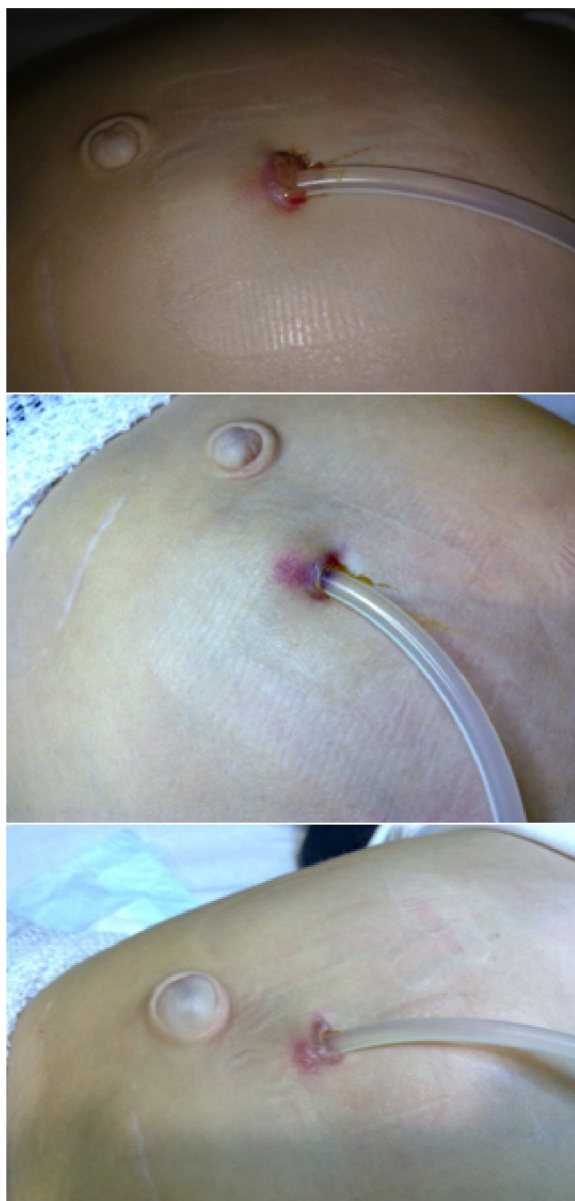
The incidence of RGAM infections has increased during the last years, this group of *Mycobacteria* is widespread, and without nutrients and over wide-ranging temperatures. The most prevalent RGAMs involved in human infections include: *M. fortuitum*, *Mycobacterium chelonae*, *Mycobacterium mucogenicum*, *Mycobacterium abscessus*, and *Mycobacterium marinum*,<sup>1</sup> with the first two most commonly resulting in peritoneal dialysis catheter infections.

We have found twenty-three cases reported of RGAM infections of the peritoneal catheter exit site were identified in 10 English and Spanish articles published between 1990 and 2011,<sup>2-11</sup> including a paediatric patient.<sup>2</sup> The most common microorganism, as in our patient was *M. fortuitum*, followed by *M. chelonae*, and *M. abscessus*. Infection was associated with peritonitis in one patient and with the infection of subcutaneous tract in 4 patients (Table 1).

Predisposing factors described are: immunosuppression, peritonitis resistant to several cycles of antibiotic, surgery, accidental trauma, or injections.

Auramin or Ziehl-Neelsen staining techniques reveal the acid-alcohol resistance of mycobacteria. A culture should

☆ Please cite this article as: Martínez López ÁB, Álvarez Blanco O, Ruíz Serrano MJ, Morales San-José MD, Luque de Pablos A. *Mycobacterium fortuitum* como causa de infección del orificio del catéter de diálisis peritoneal. Caso clínico y revisión de la literatura. *Nefrologia.* 2015;35:584-586.



**Fig. 1 – Top: erythema in the peritoneal dialysis catheter exit site, with granuloma and chocolate-like discharge. Centre: appearance of the exit site at Week 2. Bottom: appearance of the exit site at Week 6 from the start of targeted therapy.**

be made in 2 specific media: a solid egg-based medium (Lowenstein-Jensen) and a liquid medium allowing for automated reading (MGIT, MB/BacT, ESP). Colony growth usually occurs within 7 days and is identified by means of faster and more accurate phenotyping (biochemical tests) and genotyping systems, based on the detection of species-specific DNA sequences.

RGAMs are relatively resistant to standard disinfectants and are able to generate biofilms to survive. Consequently in many cases, peritoneal catheters must often be removed or replaced. In our literature review the dialysis catheter was replaced in 65.2% of patients. The catheter was also removed

**Table 1 – Characteristics of patients on peritoneal dialysis with exit-site infection by rapidly growing non-tuberculous mycobacteria (N = 24).**

Characteristics	Number	Percent
<b>Organism</b>		
<i>M. fortuitum</i>	14	58.2
<i>M. chelonae</i>	5	20.8
<i>M. abscessus</i>	5	20.8
<b>Appearance of the exit site (N = 16)</b>		
Purulent discharge	16/16	100
Granulation tissue	9/16	56.2
Abscess	5/16	31.2
<b>Associated with peritonitis</b>		
	1	4.1
<b>Associated with catheter tunnel infection</b>		
	4	16.6
<b>Requiring catheter replacement</b>		
	16	66.7
<b>Switch to HD (N = 23 patients)</b>		
Yes (temporal or permanent)	12/23	52.1
No	11/23	47.8

in all cases showing peritonitis or tunnel infection, patients with *M. abscessus* infection, and 80% of *M. chelonae* infections. More than 50% of patients had to be on haemodialysis.

In light of the extensive variability reported in terms of antibiotic resistance, species should be accurately screened *in vitro* for sensitivity to certain antibiotics so a right therapy can be established. Medium microdilution is recommended for determining sensitivity; a faster commercial technique, E-test, has been introduced in recent years, with an outstanding correlation with the reference method. An empirical therapy may include a combined therapy with aminoglycosides (amikacin), macrolides (clarithromycin and azithromycin), and fluoroquinolones (although *M. chelonae* and *M. abscessus* may be resistant to the latter). Optimal treatment duration has not been established yet, but ranged from one to six months in our literature review. One case was cured after withdrawal of topical gentamicin, which had been administered for 7 weeks, and required no further antibiotic treatment.<sup>10</sup>

In conclusion RGAMs should be suspected in catheter infections or peritonitis with negative cultures so as to prevent a delay in diagnosis and decrease associated morbidity. A large number of patients require replacement or removal of the Tenckhoff catheter and should be switched to haemodialysis.

## Conflicts of interest

The authors have no conflicts of interest to declare.

## REFERENCES

- García-Martos P, García-Agudo L. Infecciones por micobacterias de crecimiento rápido. *Enferm Infecc Microbiol Clin.* 2012;30:192-200.
- Ellis EN, Schutze GE, Wheeler JG. Nontuberculous mycobacterial exit-site infection and abscess in a peritoneal dialysis patient. A case report and review of the literature. *Pediatr Nephrol.* 2005;20:1016-8.

3. White R, Abreo K, Flanagan F, Gadallah M, Krane K, el-Shahawy M, et al. Nontuberculous mycobacterial infections in continuous ambulatory peritoneal dialysis patients. *Am J Kidney Dis.* 1993;22:581-7.
  4. Gehr TW, Walters BA. Catheter-related *Mycobacterium chelonae* infection in a CAPD patient. *Perit Dial Int.* 1994;14:278-88.
  5. Hevia C, Bajo MA, Sánchez-Tomero JA, del Peso G, Fernández-Perpen A, Millán I, et al. Peritoneal catheter exit-site infections caused by rapidly-growing atypical mycobacteria. *Nephrol Dial Transplant.* 2000;15:1458-60.
  6. Kleinpeter MA, Krane NK. Treatment of mycobacterial exit-site infections in patients on continuous ambulatory peritoneal dialysis. *Adv Perit Dial.* 2001;17:172-5.
  7. Renaud CJ, Subramanian S, Tambyah PA, Lee EJC. The clinical course of rapidly growing nontuberculous mycobacterial peritoneal dialysis infections in Asians: a case series and literature review. *Nephrology (Carlton).* 2011;16:174-9.
  8. Siu YP, Leung KT, Tong MKH, Lee MKF. *Mycobacterium chelonae* exit site infection in a patient on peritoneal dialysis. *Clin Nephrol.* 2005;63:321-4.
  9. Gourtzelis N, Margassery S, Bastani B. Successful treatment of severe *Mycobacterium fortuitum* exit-site infection with preservation of the Tenckhoff catheter. *Perit Dial Int.* 2005;25:607-8.
  10. Tse KC, Lui SL, Cheng VCC, Yip TPS, Lo WK. A cluster of rapidly growing mycobacterial peritoneal dialysis catheter exit-site infections. *Am J Kidney Dis.* 2007;50:e1-5.
  11. Viguera J, Oliva JA, Pascual R, Lens XM, Carrio J, Mallafre JM. *Mycobacterium fortuitum* in patients with chronic renal insufficiency: a propos of two cases. *Enferm Infecc Microbiol Clin.* 1990;8:286-8.
- Ana Belén Martínez-López<sup>a,\*</sup>, Olalla Álvarez Blanco<sup>a</sup>, María Jesús Ruiz Serrano<sup>b</sup>, María Dolores Morales San-José<sup>a</sup>, Augusto Luque de Pablos<sup>a</sup>
- <sup>a</sup> Sección de Nefrología Pediátrica, Servicio de Pediatría, Hospital General Universitario Gregorio Marañón, Madrid, Spain  
<sup>b</sup> Servicio de Microbiología Clínica y Enfermedades Infecciosas, Hospital General Universitario Gregorio Marañón, Madrid, Spain
- \* Corresponding author.  
 E-mail address: [anabelen.martinez@salud.madrid.org](mailto:anabelen.martinez@salud.madrid.org) (A.B. Martínez-López).

## Resistant anaemia and mixed cryoglobulinaemia in a patient on haemodialysis in the context of Q fever<sup>☆</sup>

### Anemia resistente y crioglobulinemia mixta en paciente en hemodiálisis en contexto de fiebre Q

To the Editor,

Q fever caused by *Coxiella burnetii* may produce acute or chronic clinical manifestation, although most cases are asymptomatic or mild.<sup>1</sup> Acute presentation of Q fever is characterised by a sudden flu-like syndrome and high-grade fever. Nearly 1-5% of infected patients develop a chronic form, which can take place months or years after an acute infection. The most common manifestation is endocarditis, especially in immunocompromised patients or in patients with valvular heart disease. Mixed cryoglobulinaemia is rare<sup>2,3</sup> and can be diagnosed using an immunoassay. Seroconversion is usually detected 7-15 days after the onset of symptoms. Titres of anti-phase II antigens IgG greater than 200 or Titres of anti-phase II antigens IgM greater than 50 are indicative of a recent infection, whereas titres of anti-phase I antigens IgG greater than 800 are suggestive of

chronic infection. Mild forms are commonly self-limiting. Doxycycline is the drug of choice if treatment is needed. Hydroxychloroquine and doxycycline are recommended for at least 18 months for the treatment of chronic forms of endocarditis.

Our patient is a 64-year-old man from Germany who has been living in Mallorca since 2011.

History: HTN, ischaemic cardiomyopathy that underwent revascularisation (3 stents). Atrial fibrillation treated with anticoagulation. Moderate alcoholism. End-stage chronic renal disease (ESCRD) receiving haemodialysis with vascular graft access.

In April 2013, the patient started with fever, elevated transaminases (GPT 124, GOT 114, and GGT 100), and positive CMV IgM. Following 2 weeks of treatment with ganciclovir, the fever abated but the inflammatory parameters remained high (CRP 9.24 and PCT 12.48). Fever recurred subsequently

<sup>☆</sup> Please cite this article as: Allende Burgos N, Calls Ginesta J. Anemia resistente y crioglobulinemia mixta en paciente en hemodiálisis en contexto de fiebre Q. *Nefrología.* 2015;35:586-587.