

## Letter to the Editor – Brief papers about basic research or clinical experiences

# IgA nephropathy associated with acute interstitial nephritis after administering iodinated contrast media<sup>☆</sup>

## Nefropatía IgA asociada a nefritis intersticial aguda tras administración de contraste yodado

María Valdenebro<sup>a,\*</sup>, María Marques<sup>a</sup>, Esther Rubio<sup>a</sup>, Edwin Palomino<sup>a</sup>, Estefanya García<sup>a</sup>, Jeanette Fernández<sup>a</sup>, Ana Huerta<sup>a</sup>, Carmen Bellas<sup>b</sup>, José Portolés<sup>a</sup>

<sup>a</sup> Servicio de Nefrología, Hospital Universitario Puerta de Hierro/REDInREN, ISCiii, Majadahonda, Madrid, Spain

<sup>b</sup> Servicio de Anatomía Patológica, Hospital Universitario Puerta de Hierro/REDInREN, ISCiii, Majadahonda, Madrid, Spain

Dear Director,

IgA nephropathy (IgAN) is known to be the most common cause of glomerular disease and the clinical course is variable ranging from microhematuria and isolated proteinuria to acute renal failure (ARF) or rapidly progressive GN. IgAN often presents with ARF due to tubular necrosis (ATN)<sup>1</sup>; however, biopsy findings of eosinophilia, tubulitis, and interstitial eosinophils, which are typical of acute interstitial nephropathies (AIN), and its association with the use of iodinated (IC) contrast media, are exceptional.

Therefore, we believe that renal biopsies (RB) should be performed in ARF, even when its cause appear to be clear, as with the use of IC. In our case of ARF, the starting point was a case with typical presentation of ATN resulting from IC; yet, the RB showed overlap with a severe form of IgAN and severe tubulointerstitial damage.

A 73-year-old male patient, with a history of high blood pressure, diabetes mellitus (DM), normal renal function (RF), serum creatinine (SC): 1.0 mg/dl, and urine without abnormalities.

A month before consultation he had undergone embolization of a giant bi-lobulated aneurysm of the anterior cerebral artery, requiring intravenous IC. Five days later, he developed

progressive impairment of RF with SC: 1.6 mg/dl, eosinophilia: 7.90 cells/mm<sup>3</sup>, and persistent microhematuria. The ultrasound revealed normal kidneys, and autoimmunity tests were negative. RB was not considered because of fever of unknown origin and negative blood and urine cultures. Empirical treatment with steroids 1 mg/kg was started, resulting in a rapid decrease of SC levels.

RF was progressively impaired in subsequent controls, resulting in SC: 2.3 mg/dl, microhematuria: 50–60 red blood cells/field, proteinuria: 0.8 g/24 h, without eosinophilia at 15 days; and so readmission for RB was decided.

Renal biopsy showed glomeruli with an increased mesangial matrix and cell proliferation. Tubules had severe tubulitis, signs of ATN with epithelial flattening and loss of brush border, and extensive interstitial inflammatory infiltration with the presence of eosinophils (Fig. 1). Immunofluorescence revealed granular deposits of IgA and C3 within the mesangium (Fig. 2).

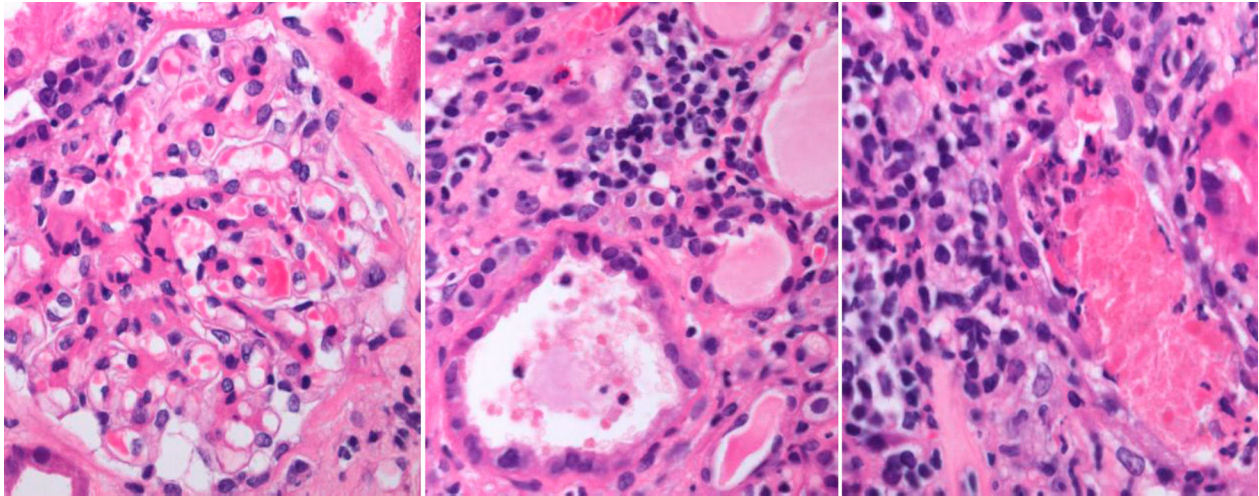
The patient was diagnosed of IgAN with severe acute tubulointerstitial involvement suggestive of AIN. Treatment with prednisone 1 mg/kg/day was initiated, and renal function stabilized although SC levels did not return to baseline after 2 months of follow-up (SC: 2.2 mg/dl).

From nephrologist's perspective, RB is an essential procedure with well-established indications for the study of

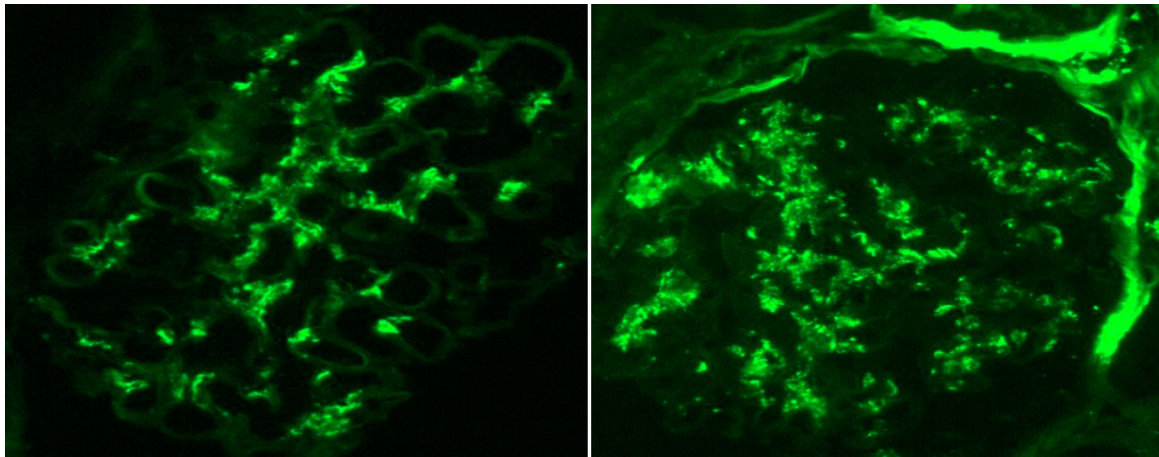
<sup>☆</sup> Please cite this article as: Valdenebro M, Marques M, Rubio E, Palomino E, García E, Fernández J, et al. Nefropatía IgA asociada a nefritis intersticial aguda tras administración de contraste yodado. Nefrología. 2015;35:582-584.

\* Corresponding author.

E-mail address: [mdev183@hotmail.com](mailto:mdev183@hotmail.com) (M. Valdenebro).



**Fig. 1 – Glomeruli with mesangial hypercellularity and interstitial expansion by inflammatory cells and eosinophils. Severe tubulointerstitial inflammation and tubulitis.**



**Fig. 2 – Immunofluorescence in conjugated antibodies showing diffuse granular mesangial uptake for C3 and IgA.**

variety of renal diseases. It confirms the diagnoses, determines prognosis, and helps to stabilize the right treatment. It is most commonly used in cases of nephrotic syndrome, abnormal urine tests, and unclear ARF. Our patient is a real example of the importance of confirming clinical suspicions with histological findings of RB. IgAN is the most common primary renal disease, but it can also progress to some form of “superimposed” glomerulonephritis (GM) in patients with diabetic nephropathy who develop ARF of any cause. In the series of Castellano et al., IgAN, together with membranous GM and vasculitis, were the most common non-diabetic conditions found in RBs among these patients.<sup>2</sup> This has led to a discussion over the role of abnormal synthesis and the degradation of glomerular basement membrane and mesangial matrix which is characteristic of these cases, with haemodynamic factors and nonenzymatic glycosylation being typical of DM.<sup>3</sup>

The association of IgAN with ARF and IC media is also common since hypersensitivity reactions result in changes in T cell receptors and cytokine release, thereby activating cell

and humoral immunity. These findings would account for the link between AIN and the use of IC. Nonetheless, their actual prevalence is underestimated by their confirmatory diagnosis, because of the bias against performance of RBs in most patients with ARF.<sup>4</sup> AIN is well-known to benefit from early treatment with steroids. González et al. studied the outcome of 61 patients diagnosed with drug-induced AIN by RB<sup>5</sup>: 85% received steroids and achieved final improvement of RF and decreased need of dialysis.

Presentation and outcome in this patient with AIN and IgAN illustrates the importance of RB among patients with ARF of uncertain etiology. This leads to early initiation of the appropriate treatment to improve prognosis for our patients and it also provides important clinical information in patients with poor outcomes (Figs. 1 and 2).

#### Conflicts of interest

The authors have no conflicts of interest to declare.

## REFERENCES

1. Wen YK, Chen ML. The spectrum of acute renal failure in IgA nephropathy. *Ren Fail.* 2010;32:428-33.
2. Castellano I, Covarsi A, Novillo R, GómezMartino JR, Ferrando L. Lesiones histológicas renales en pacientes con diabetes mellitus tipo II. *Nefrologia.* 2002;22:162-9.
3. Yoshikawa Y, Truong LD, Mattioli CA, Ordonez NG, Balsaver AM. Membranous glomerulonephritis in diabetic patients: a study of 15 cases and review of the literature. *Mod Pathol.* 1990;3:36-42.
4. Hory B, Chaillet R, Pérol C. Chronic terminal renal failure: an unusual outcome of acute tubulointerstitial nephritis. *Nephrologie.* 1987;8:237-41.
5. González E, Gutiérrez E, Galeano C, Chevia C, de Sequera P, Bernis C, Grupo Madrileño de Nefritis Intersticiales. Early steroid treatment improves renal function recovery in patients with drug-induced acute interstitial nephritis. *Kidney Int.* 2008;73:940-6.

## ***Mycobacterium fortuitum* as a cause of peritoneal dialysis catheter port infection. A clinical case and a review of the literature** ☆

### ***Mycobacterium fortuitum* como causa de infección del orificio del catéter de diálisis peritoneal. Caso clínico y revisión de la literatura**

Dear Editor,

Catheter-related infections are a common and clinically relevant in peritoneal dialysis patients. Exit-site infections are characterized by the presence of purulent discharge, with or without local. The most common pathogens are *Staphylococcus* and Gram-negative bacteria; however, rapidly growing atypical mycobacteria (RGAM) are rare.

Here we describe a paediatric patient with a *Mycobacterium fortuitum* peritoneal catheter exit-site infection together with literature review.

He is a 4-year-old boy with a 4-month history of continuous ambulatory peritoneal dialysis (CAPD). He complained of erythema in the peritoneal catheter exit site, with mild discharge and no improvement following 7 days of treatment with topical mupirocin. After sampling for exudate culture, topical therapy with ciprofloxacin was initiated. Six days later the erythema was still present and the patient developed a chocolate-coloured discharge and a granuloma was observed (Fig. 1). The patient was asymptomatic with no fever. Blood chemistry did not show an increase in acute-phase reactants, and cytochemistry of peritoneal fluid was normal. Previous culture was positive for RGAM. Intraperitoneal ciprofloxacin and amikacin were initiated, together local care of the exist site with Betadine®. The *Mycobacteria* was subsequently classified as *Mycobacterium fortuitum* sensitive to both antibiotics, ciprofloxacin and amikacin. Treatment was continued for 8

weeks and culture became negative, with low improvement of the exit site appearance (Fig. 1). Thus, it was decided to replace the Tenckhoff catheter, despite no evidence of peritonitis. The patient continued under CAPD with no acceptable ultrafiltration. The patient was naïve to systemic antibiotics and had no history of previous infections before this episode.

The incidence of RGAM infections has increased during the last years, this group of *Mycobacteria* is widespread, and without nutrients and over wide-ranging temperatures. The most prevalent RGAMs involved in human infections include: *M. fortuitum*, *Mycobacterium chelonae*, *Mycobacterium mucogenicum*, *Mycobacterium abscessus*, and *Mycobacterium marinum*,<sup>1</sup> with the first two most commonly resulting in peritoneal dialysis catheter infections.

We have found twenty-three cases reported of RGAM infections of the peritoneal catheter exit site were identified in 10 English and Spanish articles published between 1990 and 2011,<sup>2-11</sup> including a paediatric patient.<sup>2</sup> The most common microorganism, as in our patient was *M. fortuitum*, followed by *M. chelonae*, and *M. abscessus*. Infection was associated with peritonitis in one patient and with the infection of subcutaneous tract in 4 patients (Table 1).

Predisposing factors described are: immunosuppression, peritonitis resistant to several cycles of antibiotic, surgery, accidental trauma, or injections.

Auramin or Ziehl-Neelsen staining techniques reveal the acid-alcohol resistance of mycobacteria. A culture should

☆ Please cite this article as: Martínez López ÁB, Álvarez Blanco O, Ruíz Serrano MJ, Morales San-José MD, Luque de Pablos A. *Mycobacterium fortuitum* como causa de infección del orificio del catéter de diálisis peritoneal. Caso clínico y revisión de la literatura. *Nefrologia.* 2015;35:584-586.