

Letters to the Editor - Case Report

Acute pancreatitis as initial manifestation in an adult patient with focal proliferative necrotizing purpura nephritis

Pancreatitis aguda como manifestación inicial en un paciente adulto con purpura y glomerulonefritis necrosante proliferativa focal

Dear Editor,

Henoch-Schönlein purpura (HSP) is a generalized vasculitis, which could cause a large variety of symptoms in different organs. Acute pancreatitis is an inflammatory disorder and may be life-threatening if it is severe. HSP could cause the acute pancreatitis rarely. It tends to develop in the first week of the illness after characteristic purpura, or develop later.¹ Exceptionally, acute pancreatitis developed during the course of HSPN as an initial presenting feature before the typical rash. Here we report an adult patient with HSPN presenting after the acute pancreatitis.

A 19-year-old man was admitted to our hospital with the chief complaint of "abdominal pain and abnormal urine test for 1 month, erythematous purpura over legs for 5 days". He received the treatment for pancreatitis in the local hospital. However, the pancreatitis did not get remission. On admission of our hospital, the patient had a normal blood pressure and respiratory rate. There was a diffuse purpuric rash located over the legs. Abdominal examination showed tenderness in all quadrants with rebound tenderness. There was no hepatosplenomegaly, and bowel sounds were normal. Blood testing showed hemoglobin (101 g/l), white cell count (19.6×10^9 g/l), neutrophil (9.7×10^9 g/l). Erythrocyte sedimentation rate and C-reactive protein were significantly high at 29 mm/h and 100.3 mg/l, respectively. Serum testing showed glucose (3.3 mmol/l), urea (6.31 mmol/l), creatinine (52 umol/l), albumin (28.5 g/l), total cholesterol (4.1 mmol/l), and triglyceride (1.6 mmol/l). Serum amylase (332 U/l) and lipase (85.2 U/l) were increased. Urinary sediment examination showed microscopic hematuria. The proteinuria of 24 h is 2.48 g/2L. Rheumatoid factor and complements (C3, C4) were within the normal range, and antinuclear antibodies,

anti-DNA, antiphospholipids, antineutrophil cytoplasmic antibodies, and hepatitis viral markers were negative. Abdominal ultrasound showed a peritoneal effusion. Abdominal computed tomography (CT) scan noted an edematous pancreas (Fig. 1).

The result of renal biopsy was focal proliferative necrotizing purpura nephritis. Focal granular staining for IgA and C3 in the mesangium was shown using immunofluorescence staining. By light microscopy, glomeruli showed a mild hypercellularity in mesangial cells and matrix, focal endocapillary hypercellularity, eight crescents of 10 glomeruli, 1 necrosis of capillary loop. There is interstitial edema and inflammation composed mainly of mononuclear leukocytes and tubular epithelial injury (Fig. 2). The result of the light microscopy was confirmed by the electron microscopy.

The patient was diagnosed as purpura nephritis complicated by acute pancreatitis. He was started on therapy with methylprednisolone 40 mg/d intravenously for 5 days before the renal biopsy result. Afterwards, 0.5 g bolus of methylprednisolone was given intravenously for 3 days and after that prednisone orally (30 mg/day) and MMF orally (1.5 mg/day). Abdominal pain disappeared at the third day of the treatment and the pancreas was normal after two weeks' treatment. After 1-year follow-up, the patient recovered well with prednisone (10 mg/day) and MMF (0.25 mg/d), and renal function was normal, proteinuria was less than 150 mg/day, and abdominal CT scan was normal.

The association between pancreatitis and Henoch-Schönlein Purpura Nephritis is rare. In our case, purpura nephritis complicated by acute pancreatitis was showed in this 19-year-old man. HSP is a rare cause of acute pancreatitis that can occur before or after the characteristic rash. In our case, the symptoms occurred before the rash. The

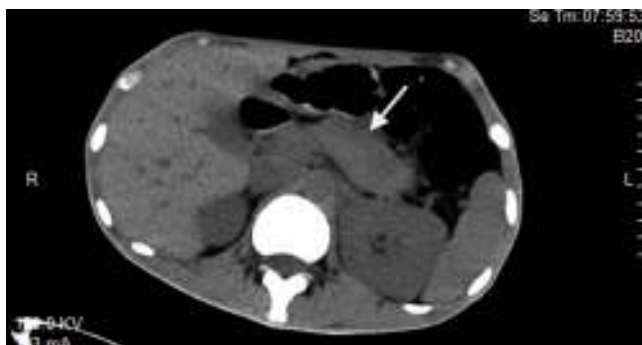


Fig. 1 – Edematous pancreas in abdominal CT scan.

pancreatitis tends to develop on the first day of the illness but may develop as late as day 75.² Acute pancreatitis is presumed to be caused by vasculitic involvement of the pancreas.

The clinical feature of HSP nephritis is quite variable. The pathology of this patient showed a mild hypercellularity in mesangial cells and matrix, focal endocapillary hypercellularity, eight crescents of ten glomeruli, 1 necrosis of capillary loop. In the literature, only two

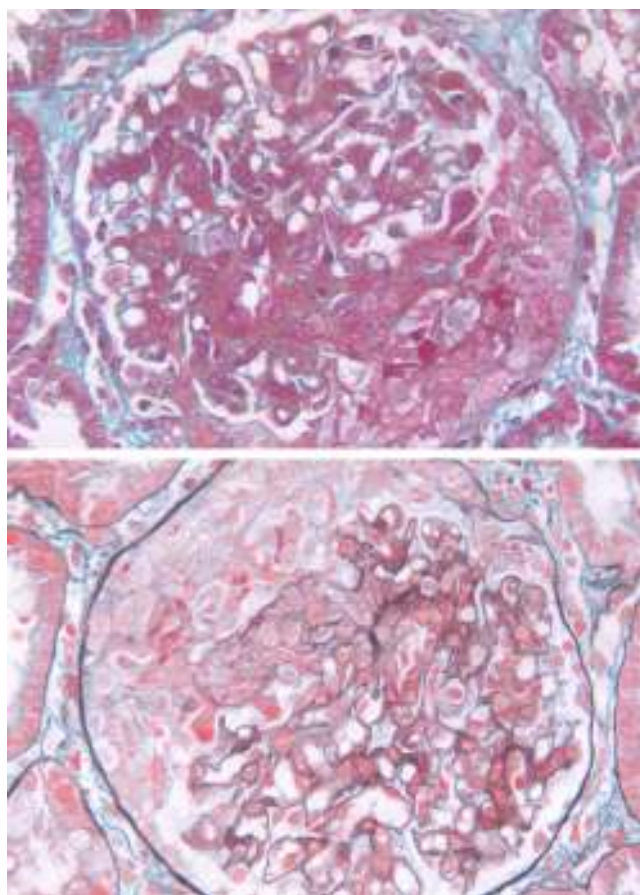


Fig. 2 – Crescents observed by light microscopy in Masson stained section (upper one, 400) and PAS stained section (lower one, 400).

cases got renal biopsy of purpura nephritis with pancreatitis. One case showed moderate-to-severe increase of mesangial matrix with crescent formation³ and one case showed endocapillary proliferative glomerulonephritis.² There is no special feature in the pathology of those patients.

Steroids have been used to treat HSP patients with pancreatitis.⁴⁻⁷ For most HSP related pancreatitis without nephritis, parenteral nutrition and Nasogastric suction was used to treat the pancreatitis,^{8,9} and the outcome of pancreatitis improved. In our case, the patient's pancreatitis did not improve with the supportive treatment; however, the symptoms of pancreatitis disappeared with the steroids usage. In the literature, two patients were diagnosed as HSP related pancreatitis with nephritis. In the study by Frirui et al., kidney biopsy showed endocapillary proliferative glomerulonephritis and the patient was given 1 g bolus methylprednisolone intravenously for 3 days and after that prednisone orally (60 mg/day).² And in the study by Nie et al., as HSP nephritis (severe) was confirmed, intravenous methylprednisolone (500 mg/d) was given to the patient for 3 days followed by oral dehydrocortisone of 30 mg/d.³ The two patients got complete remission in pancreas and kidney.

HSP is a rare and benign cause of acute pancreatitis. This complication could occur before the characteristic rash and shown as an initial manifestation of HSPN. Steroids could improve the outcome of the HSPN patients with pancreatitis.

REFERENCES

- Roberts PF, Waller TA, Brinker TM, Riffe IZ, Sayre JW, Bratton RL. Henoch-Schonlein purpura: a review article. *South Med J*. 2007;100(8):821-4.
- Frigui M, Lehiani D, Koubaa M, Bouaziz Z, Abid B, Beyrouti I, et al. Acute pancreatitis as initial manifestation of adult Henoch-Schonlein purpura: report of a case and review of literature. *Eur J Gastroenterol Hepatol*. 2011;23(2):189-92.
- Nie Y, Li W, Tong Z, Wang X, Li J. Acute pancreatitis associated with Henoch-Schonlein purpura. *Pancreas*. 2011;40(2):315-6.
- Diaz CF. Schonlein-Henoch purpura and pancreatitis. *Dig Dis Sci*. 1995;40(4):750-1.
- Cheung KM, Mok F, Lam P, Chan KH. Pancreatitis associated with Henoch-Schonlein purpura. *J Paediatr Child Health*. 2001;37(3):311-3.
- Soyer T, Egritas O, Atmaca E, Akman H, Ozturk H, Tezic T. Acute pancreatitis: a rare presenting feature of Henoch Schonlein purpura. *J Paediatr Child Health*. 2008;44(3):152-3.
- Dinler G, Bek K, Acikgoz Y, Kalayci AG. Acute pancreatitis as a presenting feature of Henoch-Schonlein purpura. *Turk J Pediatr*. 2010;52(2):191-3.
- Puppala AR, Cheng JC, Steinheber FU. Pancreatitis – a rare complication of Schonlein-Henoch purpura. *Am J Gastroenterol*. 1978;69(1):101-4.
- El Alami S, Azar C, Bheane M, Derumier J. Acute pancreatitis: a rare initial clinical manifestation of Henoch-Schonlein disease. *Acta Gastro-enterol Belg*. 1994;57(3-4):264-5.

Dong Liu, Yanna Dou, Wenming Yuan, Zeyu Li,
Songxia Quan, Jing Xiao, Zhanzheng Zhao*

Nephrology Center of The First Affiliated Hospital of Zhengzhou
University, Zhengzhou University Institute of Nephrology,
Zhengzhou, Henan, China

* Corresponding author.

E-mail addresses: 13938525666@139.com,
zhaozhanzheng2014@126.com (Z. Zhao).

0211-6995/© 2015 The Authors. Published by Elsevier España, S.L.U. on behalf of Sociedad Española de Nefrología. This is an open access article under the CC BY-NC-ND license (<http://creativecommons.org/licenses/by-nc-nd/4.0/>).
<http://dx.doi.org/10.1016/j.nefro.2015.06.002>

Letters to the Editor - Case Report

Response to acetazolamide in a patient with tumoural calcinosis[☆]

Respuesta a acetazolamida en paciente con calcinosis tumoral

To the Editor,

Tumoural calcinosis (TC) is a rare disorder of phosphorus metabolism, characterised by the formation of periarticular deposits of calcium phosphate.¹ The disease is the result of a defect in renal phosphorus excretion, due to mutations in the genes for fibroblast growth factor 23 (FGF23), Klotho (KL), and N-acetylgalactosaminyltransferase-3 (GALNT3). The loss of FGF23 function results in increased tubular phosphorus reabsorption, and subsequent deposition in subcutaneous tissues.²

We present the case of a 23-year-old man with no significant past medical history, whose symptoms began at the age of 18 years, with the appearance of a mass in the right dorsal region, lateral buttock, and thigh. The patient reported a progressive increase in size of the mass, related with physical activity, and pain in the affected limb as a functional limitation. Six months before his admission to our hospital, the tumour had been excised, measuring 18 × 7 cm from the right thigh, and 20 × 10 cm from the right buttock, with amorphous characteristics.

On admission, he had a solid painless mass in the area of excision on the superficial lateral right thigh, measuring 10 × 4 × 6 cm. Laboratory analysis reported normal serum levels of calcium, phosphate, creatinine, albumin, and PTH. X-ray revealed a multinodular calcified mass around the right hip joint.

Biopsy of the lesion reported amorphous calcified nodules, some surrounded by a proliferation of macrophages and

osteoclast-like giant cells, separated by dense fibrous tissue, consistent with TC (Fig. 1). He was followed up for 2 years while receiving acetazolamide (August 2008 to October 2011) and showed clinical improvement and cessation of growth of the lesions. There were no reported acid-base disturbances during treatment. A follow-up X-ray was taken 7 years after starting treatment, with no increase in the size of the lesions (Fig. 2).

The pathophysiology of TC is based on abnormal phosphorus metabolism.³ Serum phosphate concentration is regulated by endocrine communication between bone, kidney, and the intestine.⁴ The endocrine factors involved in phosphate metabolism are 1,25-hydroxyvitamin D3, parathyroid hormone (PTH) and FGF23. FGF23 and PTH act synergistically to reduce the expression of the cotransporters NaPi-IIa and NaPi-IIc in the brush border of the proximal renal tubule, increasing renal phosphorus excretion.⁵

FGF 23 is a glycoprotein, formed by 251 amino acids, and has an N-terminal and a C-terminal made of 71 amino acids.⁶ It promotes phosphorus excretion by reducing the expression of NaP(i) cotransporters in the proximal tubular cell brush border.³ For FGF23 to bind to its receptor, FGFR1c, Klotho is essential to form a functional heterodimer.⁷ FGF23 is glycosylated by GALNT3.⁸ Only the complete FGF23 protein is biologically active. Therefore, an abnormality at any of these points can lead to increased tubular phosphorus reabsorption, which is what happens in TC.³

The disease manifests as hyperphosphatemia and massive calcium deposition in the subcutaneous tissue, which are the

DOI of original article:

<http://dx.doi.org/10.1016/j.nefro.2015.07.002>

[☆] Please cite this article as: Landini-Enríquez V, Escamilla MA, Soto-Vega E, Chamizo-Aguilar K. Respuesta a acetazolamida en paciente con calcinosis tumoral. Nefrología. 2015;35:504-506.