



Letter to the Editor

Acute kidney injury with sodium-glucose co-transporter-2 inhibitors across the cardiovascular and renal outcome trials: Foe or friend?

Daño renal agudo con cotransportador de sodio-glucosa-2 inhibidores en el resultado cardiovascular y renal ensayos: enemigo o amigo?

Dear Editor,

Acute kidney injury (AKI) represents an independent, prognostic risk factor for chronic kidney disease development and progression, cardiovascular morbidity and mortality and all-cause mortality both in the in-hospital and in the out-patient setting¹⁻⁴. Patients with diabetes mellitus experience an increased risk for AKI compared to non-diabetic subjects, while lower estimated glomerular filtration rate and higher albuminuria are associated with greater risk of AKI⁵.

In a recently published retrospective cohort study it was demonstrated that sodium-glucose co-transporter-2 (SGLT-2) inhibitors do not correlate with increased risk of AKI compared to other glucose-lowering drugs⁶. Two previous meta-analyses of the initial "hallmark" cardiovascular outcome trials, namely the Empagliflozin Cardiovascular Outcome Event Trial in Type 2 Diabetes Mellitus Patients-Removing Excess Glucose (EMPA-REG OUTCOME), the Canagliflozin Cardiovascular Assessment Study (CANVAS) and the Dapagliflozin Effect on Cardiovascular Events-Thrombolysis in Myocardial Infarction 58 (DECLARE-TIMI 58) trial, with the addition of the Canagliflozin and Renal Events in Diabetes with Established Nephropathy Clinical Evaluation (CREDENCE) trial, have shown that SGLT-2 inhibitors confer a robust decrease in the risk of AKI, overcoming initial worries regarding increased risk^{7,8}.

During last year, publication of the Dapagliflozin and Prevention of Adverse Outcomes in Heart Failure (DAPA-HF) demonstrated for the first time the substantial cardiovascular benefits with SGLT-2 inhibitors in patients with heart failure with reduced ejection fraction (HFrEF) regardless of concomitant diabetes mellitus, establishing a new indication for the administration of this drug class. Recently, we were delighted

to read the results of the ertugliflozin cardiovascular outcome trial (VERTIS CV) and the trial assessing the cardiovascular and renal effects of empagliflozin on patients with HFrEF with or without diabetes (EMPEROR-Reduced). In addition, we have also welcomed the results of the trial evaluating the effects of dapagliflozin on patients with chronic kidney disease and albuminuria, with or without diabetes (DAPA-CKD), along with the sotagliflozin trials, namely the Sotagliflozin on Cardiovascular and Renal Events in Patients With Type 2 Diabetes and Moderate Renal Impairment Who Are at Cardiovascular Risk (SCORED) trial and the Sotagliflozin in Patients with Diabetes and Recent Worsening Heart Failure (SOLOIST-WHF) trial. Therefore, we sought to determine the effect of SGLT-2 inhibitors on AKI regardless of diabetes status across the hallmark cardiovascular and renal outcome trials.

Two independent reviewers (D.P. and C.P.) extracted the data from the eligible reports, by using a pilot tested, data extraction form. We preferred utilizing data from intention-to-treat analyses.

As we assessed only a dichotomous variable, difference was calculated with the use of risk ratio (RR), with 95% confidence interval (CI), after implementation of the Mantel-Haenszel (M-H) random effects formula. Statistical heterogeneity among studies was assessed by using I^2 statistics. Heterogeneity was considered to be low if I^2 was between 0% and 25%, moderate if I^2 was between 25% and 50%, or high if I^2 was greater than 75%⁹. All analyses were performed at the 0.05 significance level, while they were undertaken with RevMan 5.3 software.

Two independent reviewers (D.P. and C.P.) assessed the quality of the included randomized controlled trials, by using the Revised Cochrane risk of bias tool for randomized trials (RoB 2.0) for the primary safety outcome¹⁰. Discrepancies

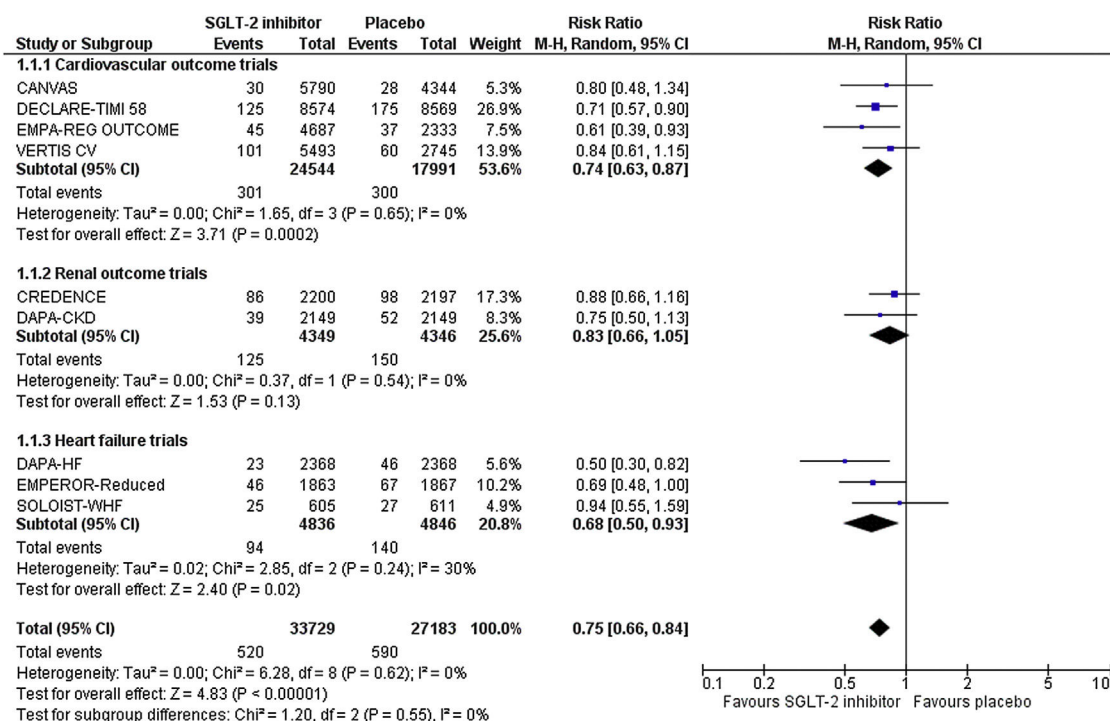


Fig. 1 – Effect of SGLT-2 inhibitors compared to control on the risk of AKI across the cardiovascular and renal outcome trials and the trials performed in the heart failure population.

between reviewers were solved by discussion, consensus or arbitration by a third senior reviewer (M.D.).

Besides trialists of the SCORED trial who did not report any data regarding the incidence of AKI in the two treatment arms, the rest cardiovascular and renal outcome trials and trial performed in the heart failure population provided corresponding data. Specifically, trialists of the EMPEROR-Reduced trial provided relevant data in a recently published, post-hoc analysis. Therefore, we pooled available data from nine randomized controlled trials in a total of 60,912 enrolled participants. Risk of bias is considered as low across all included trials.

Overall, SGLT-2 inhibitor treatment resulted in a decrease in the risk of AKI equal to 25% (RR=0.75, 95% CI; 0.66–0.84, I²=0%), as shown in Fig. 1. This effect was driven by the cardiovascular outcome trials (RR=0.74, 95% CI; 0.63–0.87, I²=0%) and trials performed in the heart failure population (RR=0.68, 95% CI; 0.50–0.93, I²=30%). In contrast, no effect was observed in the dedicated renal outcome trials (RR=0.83, 95% CI; 0.66–1.05, I²=0%).

Collectively, it seems that the observed protective effect of SGLT-2 inhibitors against AKI in the high or very high-risk patients enrolled in the aforementioned cardiovascular and renal outcome trials and trials in the heart failure population is very important and should influence decision making in clinical practice. Of note, close monitoring of patients after prescription of a SGLT-2 inhibitor is always required, especially in patients with risk factors for presenting with AKI, since manifestation of adverse events such as volume depletion phenomena or hypotension could potentially predispose to the development of AKI in the context of the induced osmotic

diuresis, even though incidence of these events remains quite low.

Conflict of interest

None to declare.

REFERENCES

1. Coca SG, Singanamala S, Parikh CR. Chronic kidney disease after acute kidney injury: a systematic review and meta-analysis. *Kidney Int.* 2012;81:442–8.
2. Odutayo A, Wong CX, Farkouh M, Altman DG, Hopewell S, Emdin CA, et al. AKI and long-term risk for cardiovascular events and mortality. *J Am Soc Nephrol.* 2017;28:377–87.
3. Coca SG, Yusuf B, Shlipak MG, Garg AX, Parikh CR. Long-term risk of mortality and other adverse outcomes after acute kidney injury: a systematic review and meta-analysis. *Am J Kidney Dis.* 2009;53:961–73.
4. See EJ, Jayasinghe K, Glassford N, Bailey M, Johnson DW, Polkinghorne KR, et al. Long-term risk of adverse outcomes after acute kidney injury: a systematic review and meta-analysis of cohort studies using consensus definitions of exposure. *Kidney Int.* 2019;95:160–72.
5. James MT, Grams ME, Woodward M, Elley CR, Green JA, Wheeler DC, et al. A meta-analysis of the association of estimated GFR, albuminuria, diabetes mellitus, and hypertension with acute kidney injury. *Am J Kidney Dis.* 2015;66:602–12.
6. Rampersad C, Kraut E, Whitlock RH, Komenda P, Woo V, Rigatto C, et al. Acute kidney injury events in patients with

type 2 diabetes using SGLT2 inhibitors versus other glucose-lowering drugs: a retrospective cohort study. *Am J Kidney Dis.* 2020;76:471–90.

7. Gilbert RE, Thorpe KE. Acute kidney injury with sodium-glucose co-transporter-2 inhibitors: a meta-analysis of cardiovascular outcome trials. *Diabetes Obes Metab.* 2019;21:1996–2000.
8. Neuen BL, Young T, Heerspink HJL, Neal B, Perkovic V, Billot L, et al. SGLT2 inhibitors for the prevention of kidney failure in patients with type 2 diabetes: a systematic review and meta-analysis. *Lancet Diabetes Endocrinol.* 2019;7:845–54.
9. Higgins JPT, Thomas J, Chandler J, Cumpston M, Li T, Page MJ, editors. *Cochrane Handbook for Systematic Reviews of Interventions* version 6.2 (updated February 2021). Cochrane, 2021. Available from: <http://www.training.cochrane.org/handbook>.
10. Sterne JAC, Savović J, Page MJ, Elbers RG, Blencowe NS, Boutron I, et al. RoB 2: a revised tool for assessing risk of bias in randomised trials. *BMJ.* 2019;366:14898.

Dimitrios Patoulas^{a,*}, Christodoulos Papadopoulos^b, Fotios Siskos^a, Michael Doumas^{a,c}

^a Second Propedeutic Department of Internal Medicine, Aristotle University of Thessaloniki, General Hospital “Hippokraton”, Greece

^b Third Department of Cardiology, Aristotle University of Thessaloniki, General Hospital “Hippokraton”, Greece

^c Veterans Affairs Medical Center, George Washington University, Washington, District of Columbia, United States

*Corresponding author.

E-mail address: dipatoulas@gmail.com (D. Patoulas).

0211-6995/© 2021 Sociedad Española de Nefrología. Published by Elsevier España, S.L.U. This is an open access article under the CC BY-NC-ND license (<http://creativecommons.org/licenses/by-nc-nd/4.0/>).

<https://doi.org/10.1016/j.nefro.2021.05.012>

Acute renal failure as a debut manifestation in Still's disease

Insuficiencia renal aguda como manifestación inicial en la enfermedad de Still

Dear Editor,

Adult Still's disease (ASD) is a systemic inflammatory disease of unknown etiology. Renal involvement in ASD is a rare and rarely reported manifestation in the literature. This report presents an atypical case of ASD with acute renal failure.

A 39-year-old male with arterial hypertension treated with Ramipril 10 mg was admitted to the Emergency Department (ED) with a fever of up to 39 °C, right laterocervical edema, dysphagia, and odynophagia the last four days. He started treatment with Amoxicillin-Clavulanate before consultation in the ED. The patient did not report country outings or recent trips. He highlighted an infestation of rodents in his building. The patient denied consuming alcohol, tobacco and other drugs, or mushrooms, herbal products, or other substances that could have caused liver damage.

Physical examination revealed mild jaundice, a temperature of 38 °C, non-adhered right laterocervical lymphadenopathy of 1–2 cm, enlarged tonsils with discrete whitish plaques on their surface, and a macular and itchy rash on the upper trunk and forearms. Laboratory tests at ED showed: procalcitonin 1.10 ng/ml, urea 69 mg/dL, creatinine 2.79 mg/dL, sodium 135 mmol/L, potassium 4.5 mmol/L, chlorine 98 mmol/L, GPT 114 U/L, CK 233 U/L, Amylase 35 U/L, C reactive protein (CRP) 286.9 mg/L, leukocytes 15,430/mcL (neutrophils 13,740/mcL), prothrombin activity 63%. Abdominal ultrasound and chest X-ray were normal. The patient presented the day after admission: total bilirubin 9 mg/dL, direct bilirubin 8.4 mg/dL, GGT 143 IU/L, and Alkaline Phosphatase 267 IU/L. Leukocytosis

reached 33,000/mcL with 92% polymorphonuclear cells. The rise in ferritin levels was remarkable with 4.104 mcg/mL. During admission, the patient presented a rapid onset acute renal failure with anuria. The renal function worsened with a creatinine of 10.36 mg/dL. This clinical course led to hemodialysis therapy from the second day of admission.

Immunoglobulin A level was 479 mg/dL. C3, C4, Anti-streptolysin O, antinuclear antibodies, nuclear extractible antigen antibodies, anti-DNA antibodies, neutrophil anti-cytoplasmic antibodies were normal or negative. Interleukin-6 was 148 pg/mL. Plasma protein electrophoresis was compatible with an acute inflammatory process.

Nasopharyngeal swab for Polymerase Chain Reaction for SARS-CoV2 and pharyngeal swab for *Streptococcus pyogenes* were both negative. Urine and blood cultures were negative. Serologic studies ruled out acute infection by Cytomegalovirus, Epstein-Bar virus, Measles, Q fever, Leptospira, hepatitis A and B viruses, Human Immunodeficiency Virus, and parvovirus B19. A computed tomography (CT) scan showed a slightly enlarged 15-cm spleen. A Positron Emission Tomography-CT scan was normal.

Finally, a renal biopsy showed an acute tubulointerstitial inflammatory infiltrate with some ruptured tubule and isolated eosinophils associated with a dense lymphoplasmacytic infiltrate and a mesangial deposit anti-IgA (++) and minimal anti-C3, all of which was compatible with IgA mesangial nephropathy and acute tubulointerstitial nephritis (Fig. 1). However, there was an absence of intratubular erythrocyte casts or crescents in the biopsy.